Případ č. **868**

Zdeněk K I N K O R

XXX. Martinský bioptický seminář

Martin 202**4**

Pagetův karcinom



Na bradavce **zapomeňte** na dermatózy; včasná bioptická verifikace !

High grade, high-stage (**1**/**2** pozitivní axila), **3**/**4** Her2**+**

1/**3** jen diskrétní DCIS (pozor na „skip“ léze…)

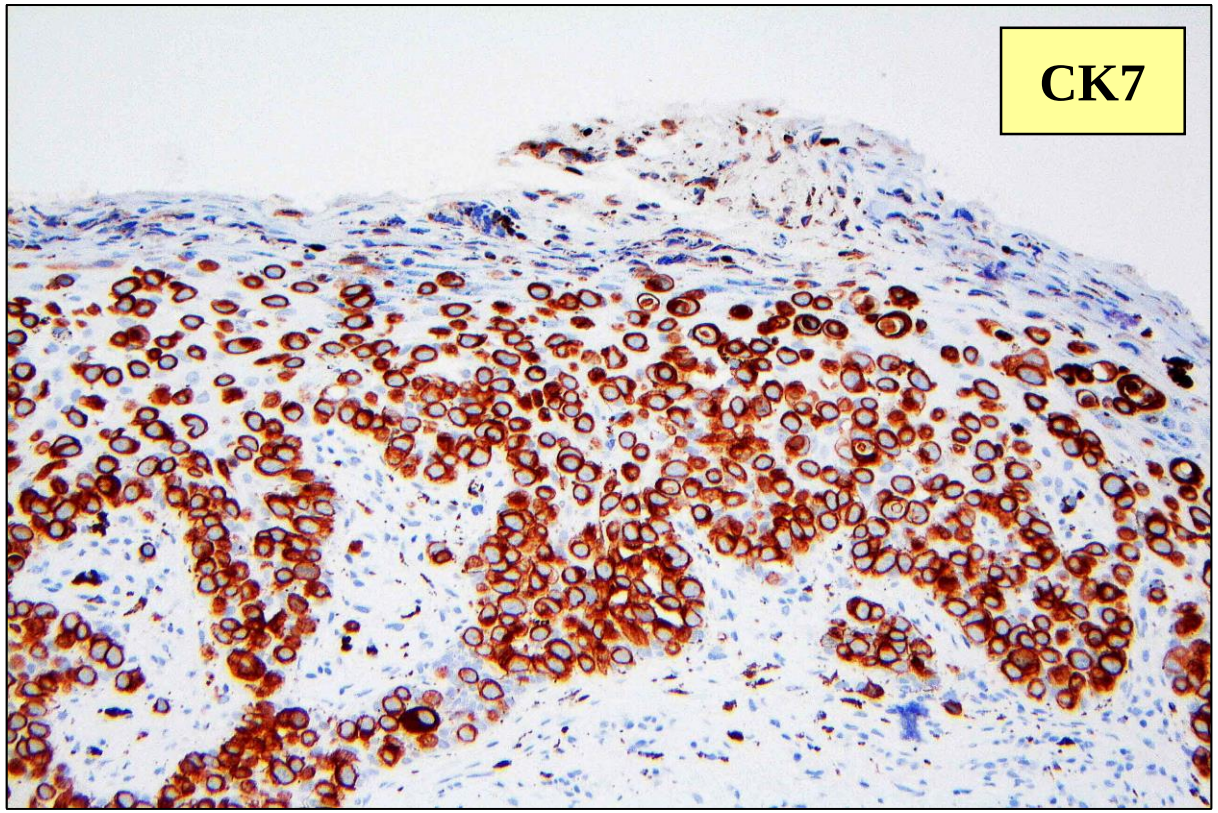

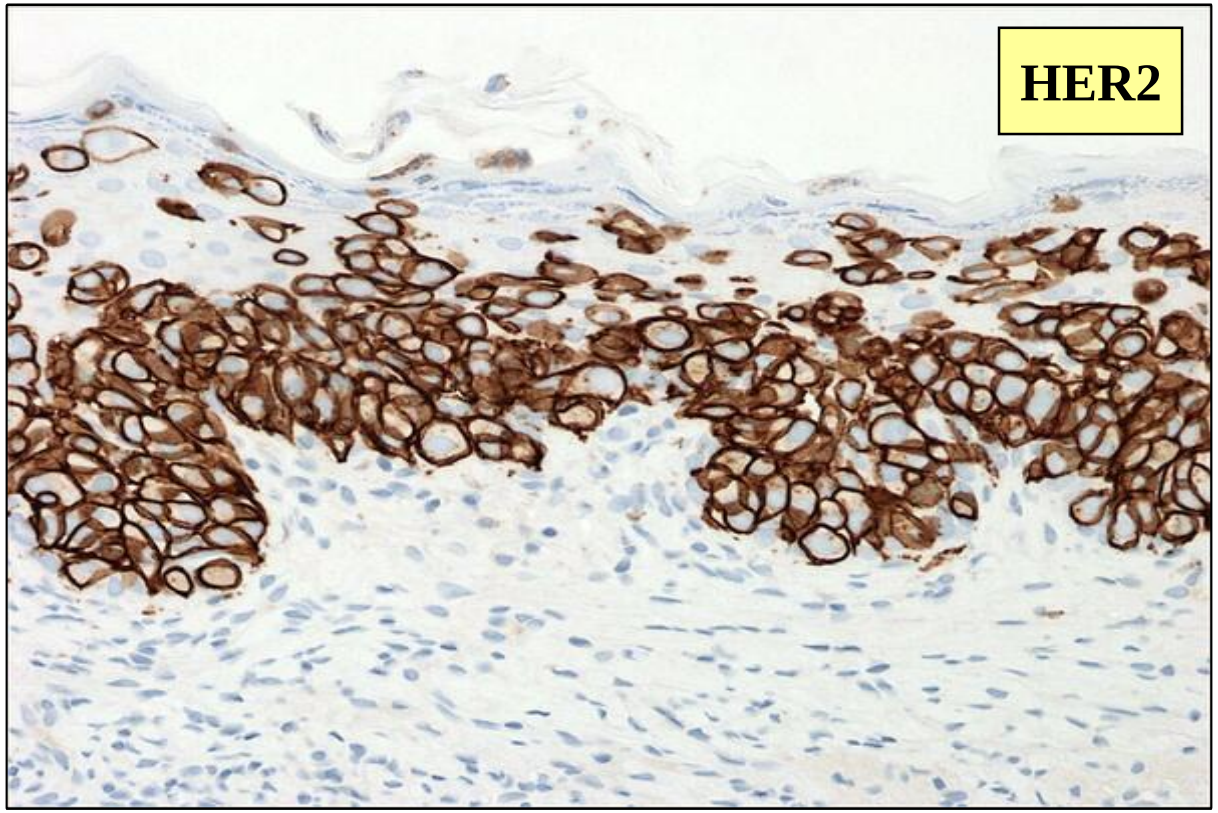

Human Pathology (2008) 39, 1295–1300

ELSEVIER

Human PATHOLOGY

www.elsevier.com/locate/humpath

Original contribution

Toker cells of the breast. Morphological and immunohistochemical characterization of 40 cases

Luca Di Tommaso MD[a,*], Giada Franchi BS[a], Annarita Destro BS, PhD[a], Fabiana Broglia BS[a], Francesco Minuti BS[b], Daoud Rahal MD[a], Massimo Roncalli MD, PhD[a]

Tokerovy bb. (TC) - **nejasná** histogeneze

- Migrace výstelky mlékovodů **?**
- Epidermální mamární vestigium **?**

Hyperplasia **TC** **vs.** Paget carcinoma

Origo? Pagetova karcinomu při **absenci** DCIS resp. IDC (<**5**%)

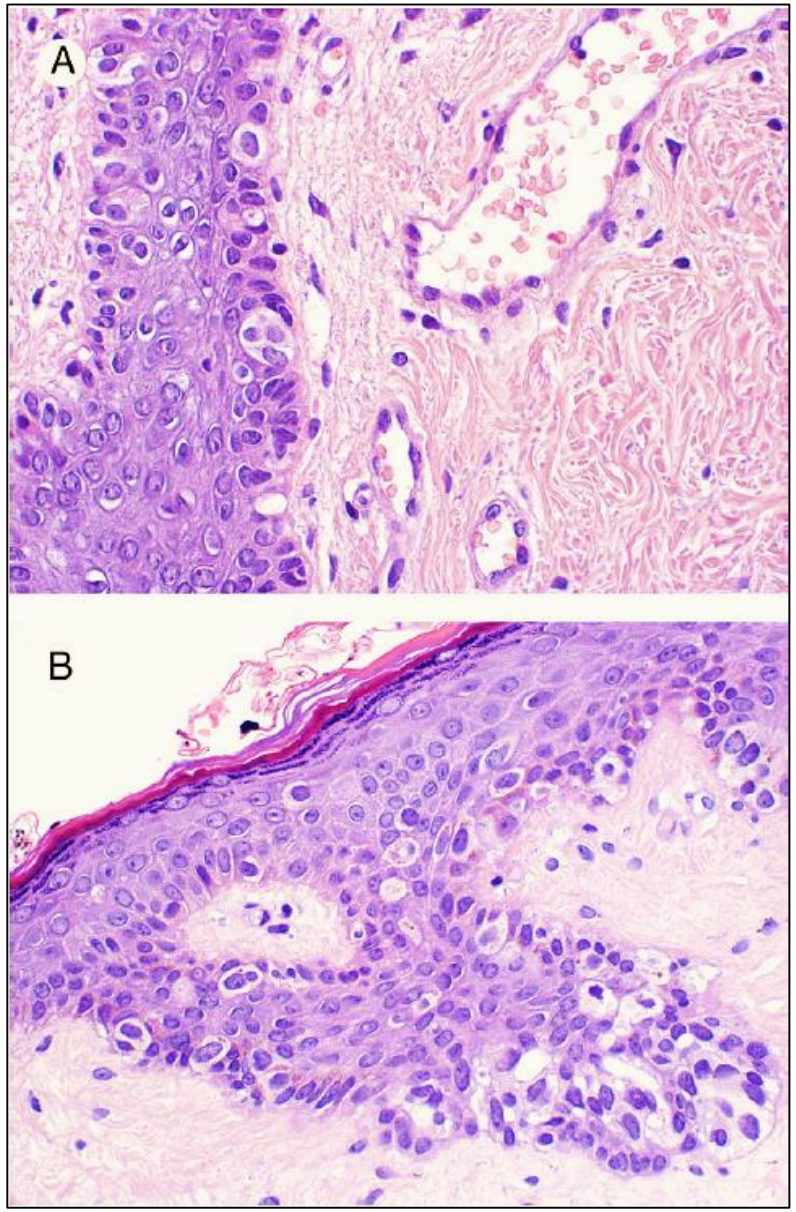

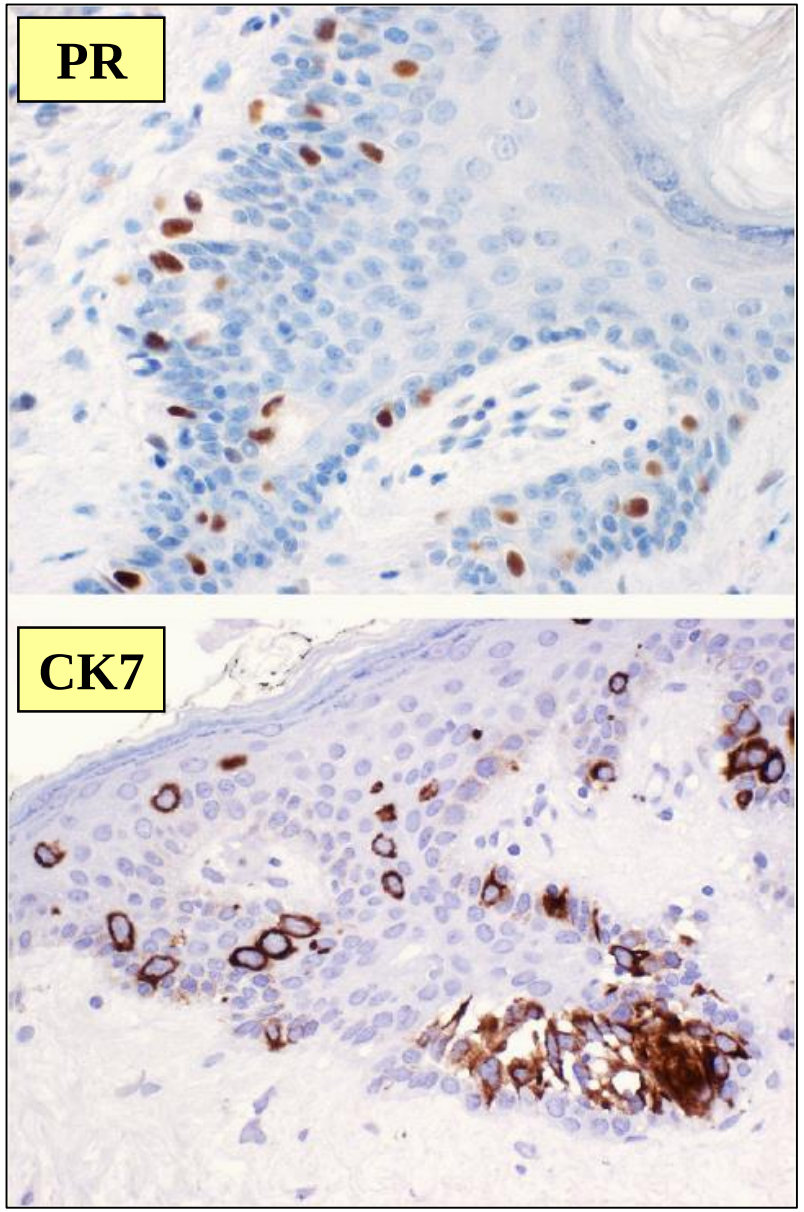

5/24 - 3 roky bolestivé zduření dvorce a bradavky, minulá MG 1/23 - mastopatie, lokální nález **neřešen…**

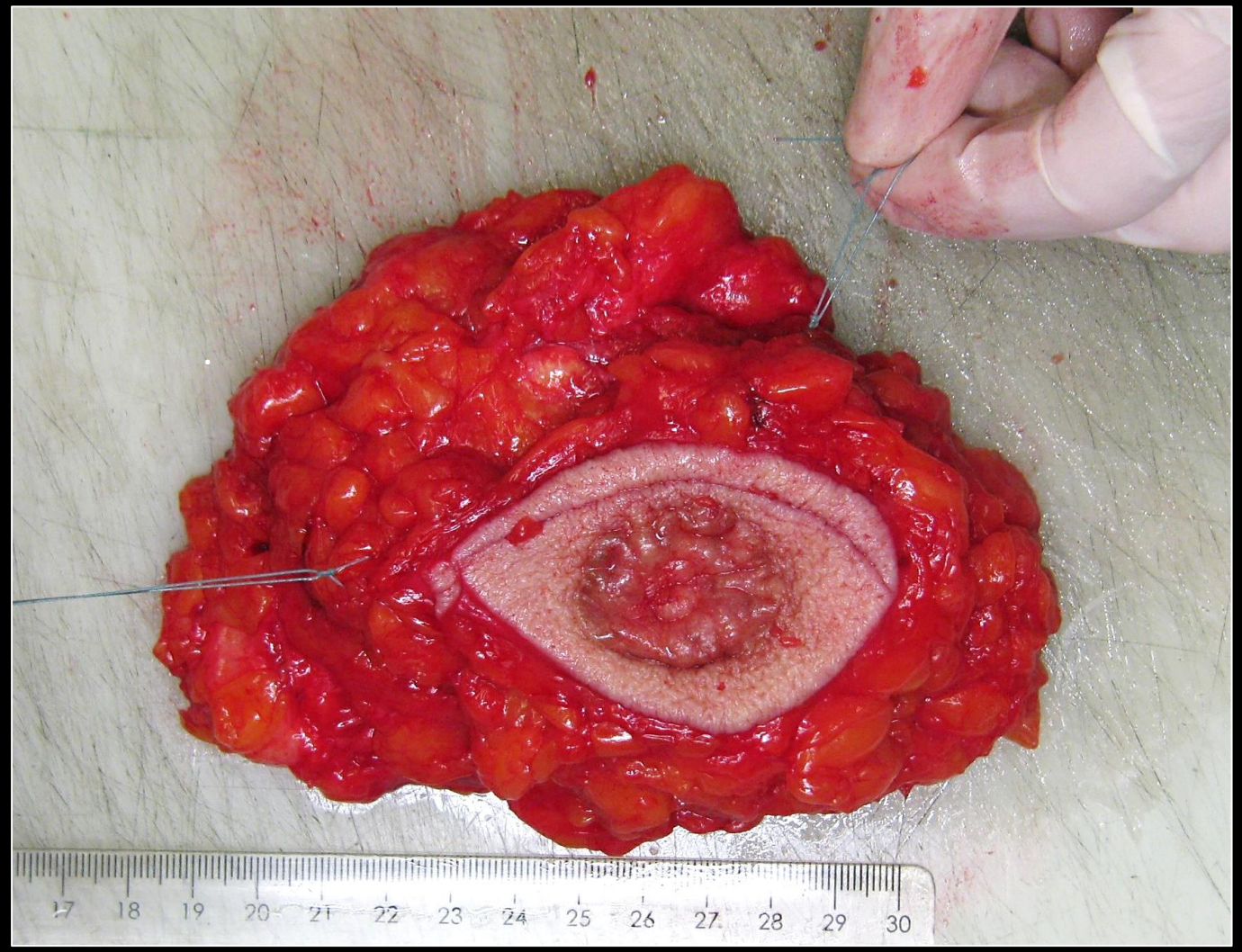

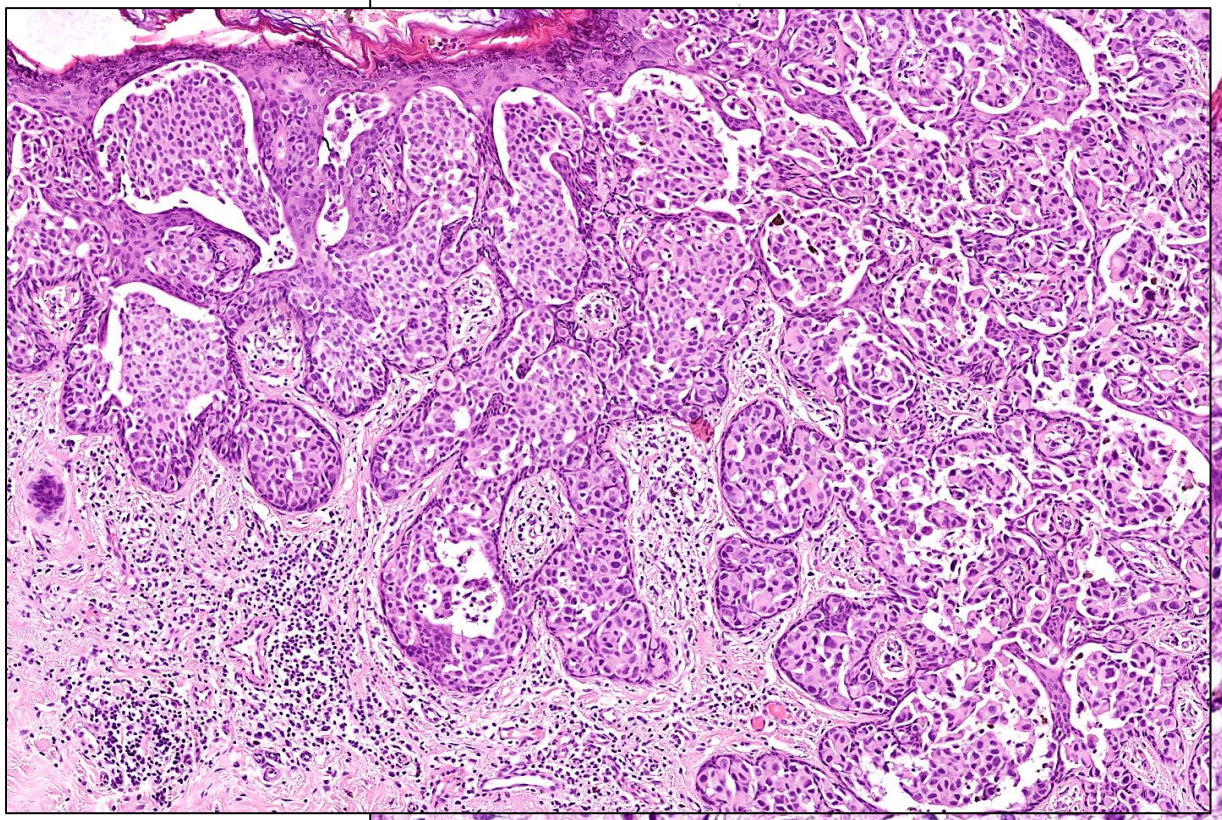

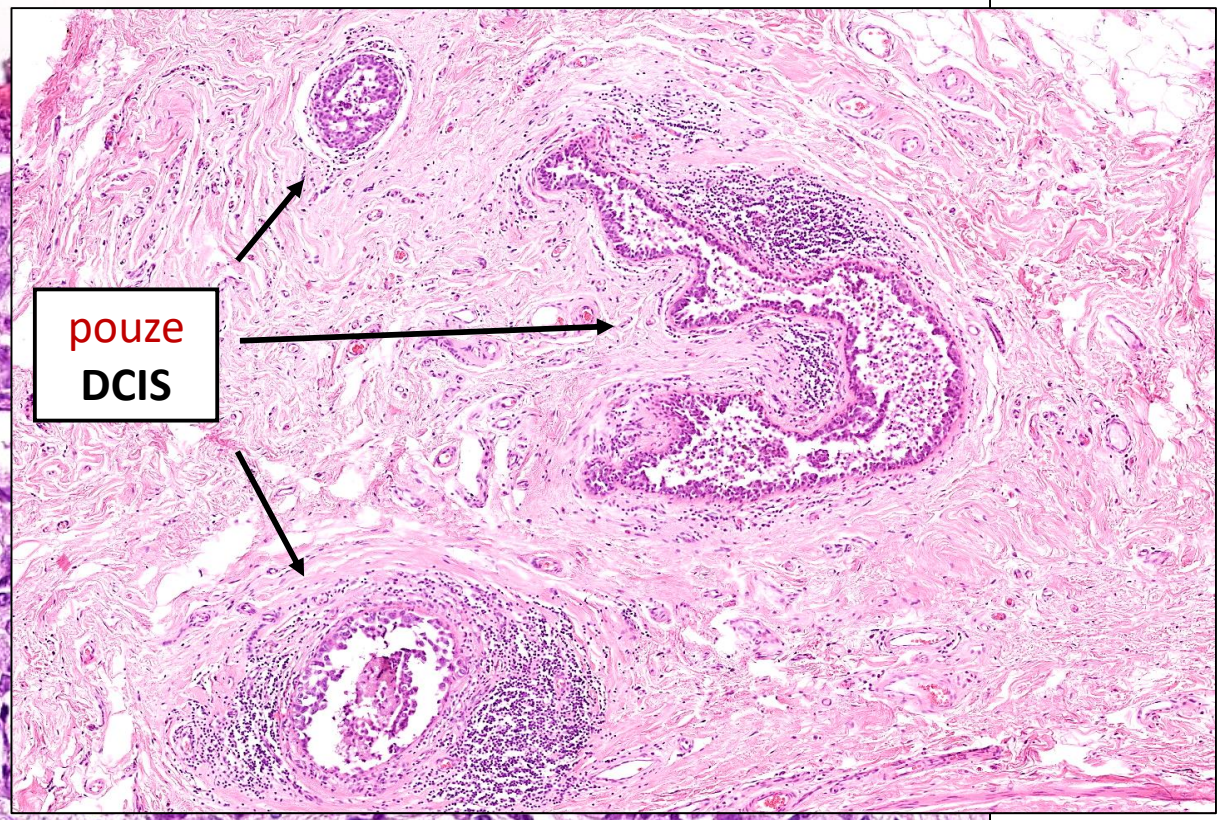
pouze
DCIS

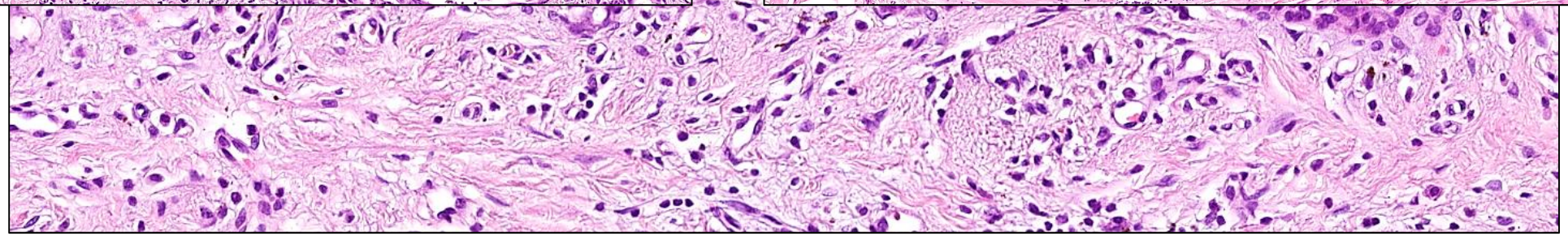

1

Postradiační? leiomyosarkom - před 11 lety IDC G2 / RTG

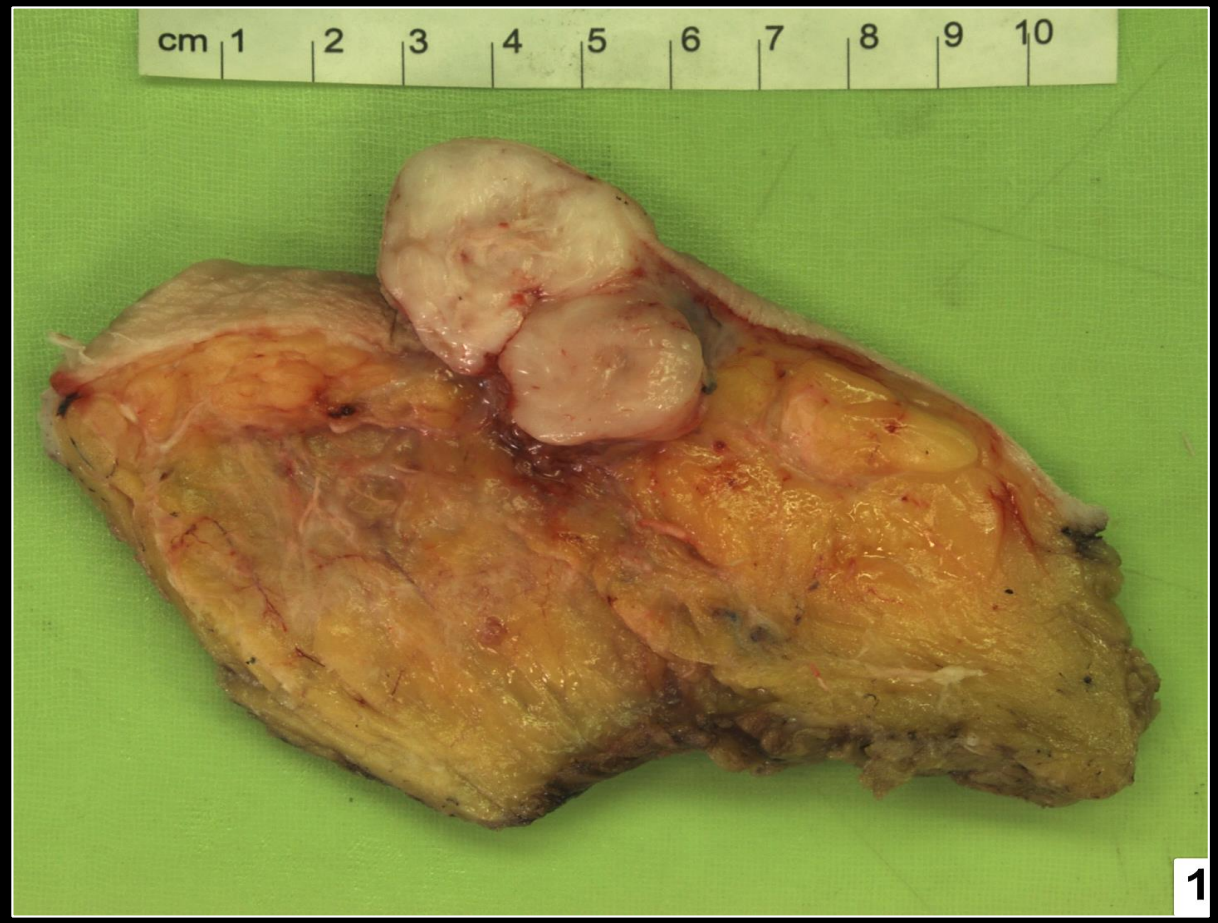

laskavě Dr. Koubová, Pelhřimov

2

Postradiační? leiomyosarkom - před 7 lety DCIS G2 / RTG

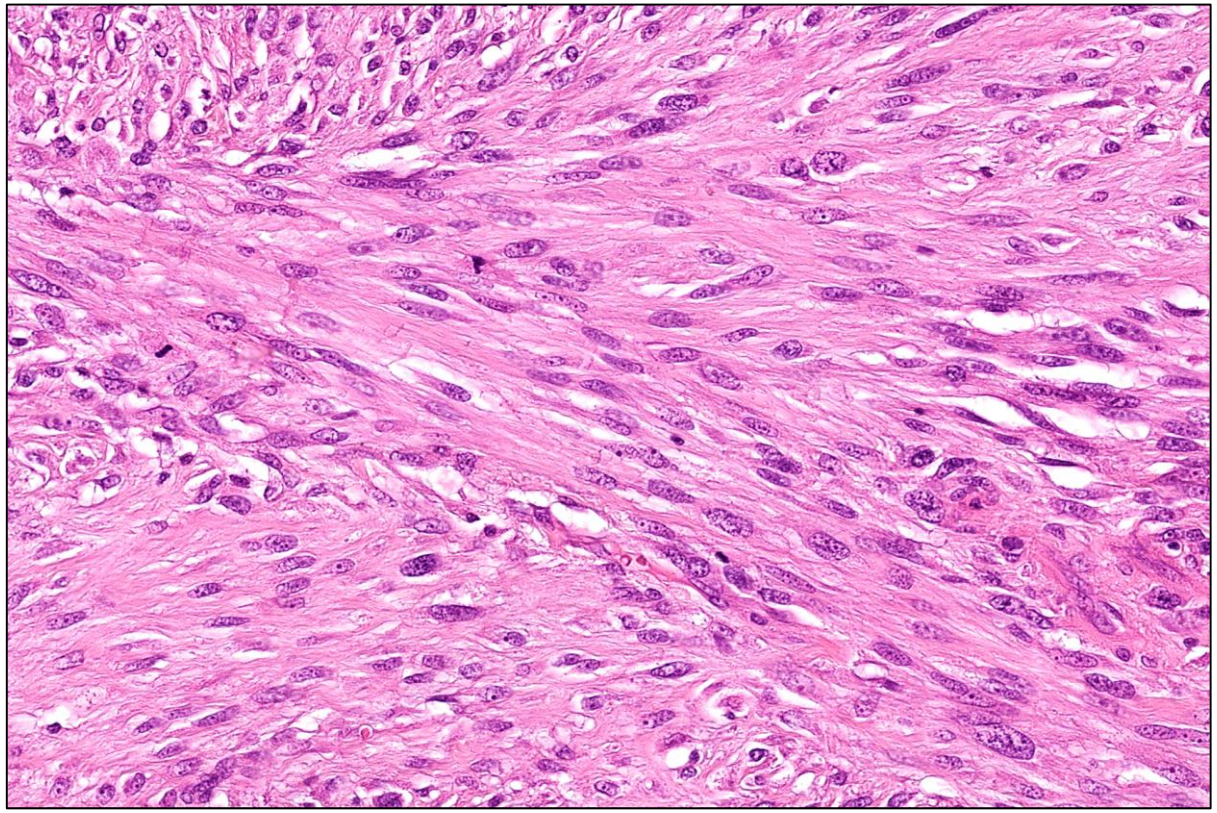

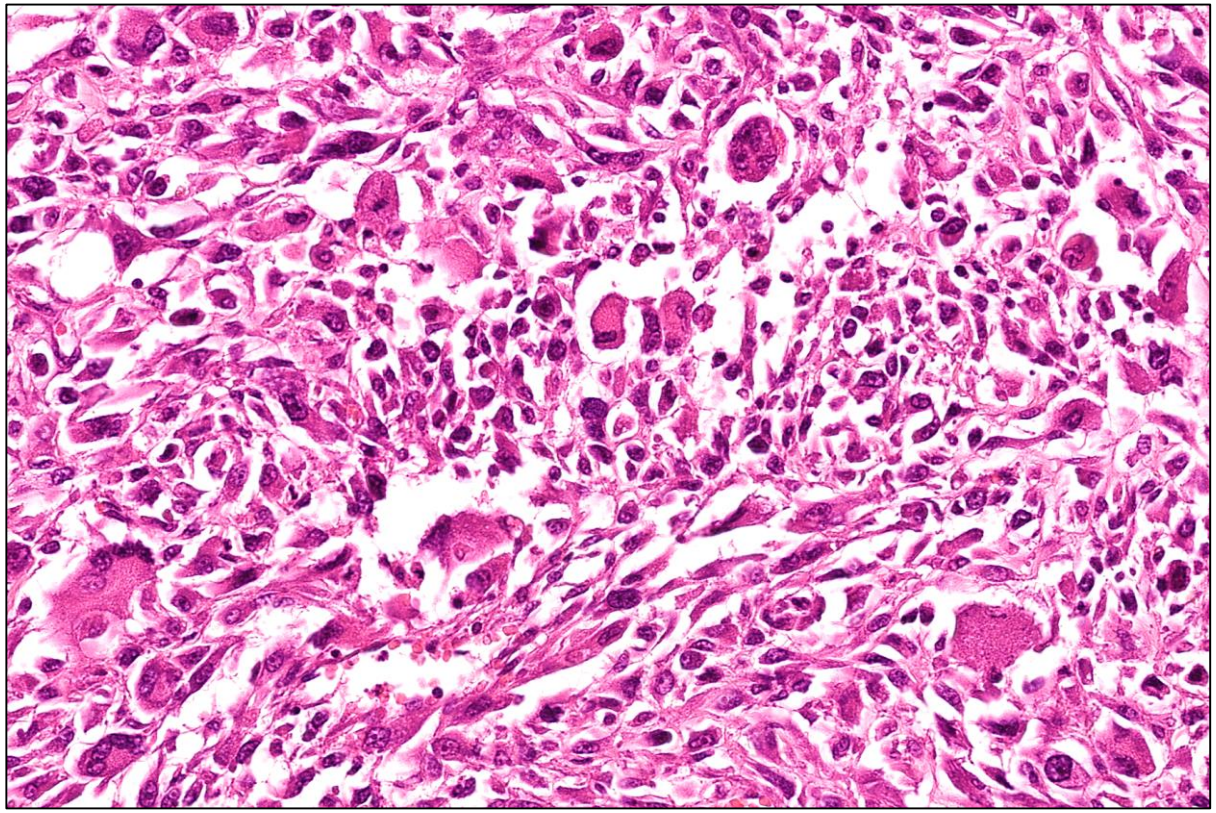

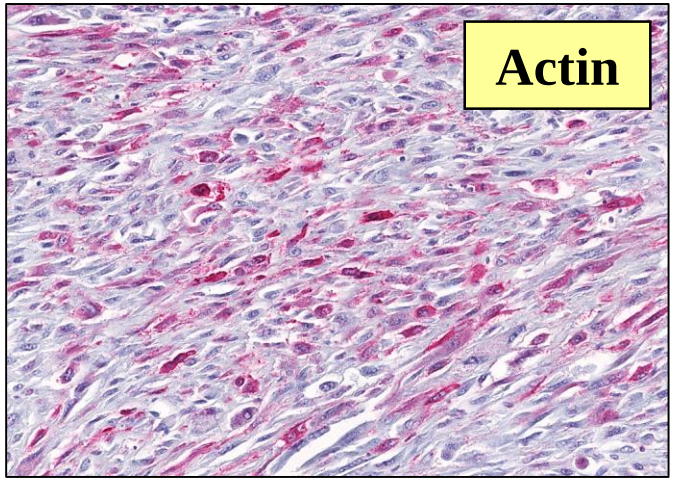
Actin

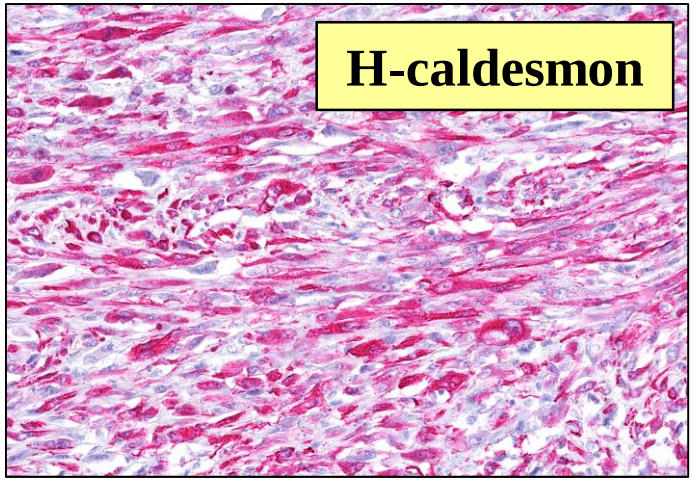
H-caldesmon

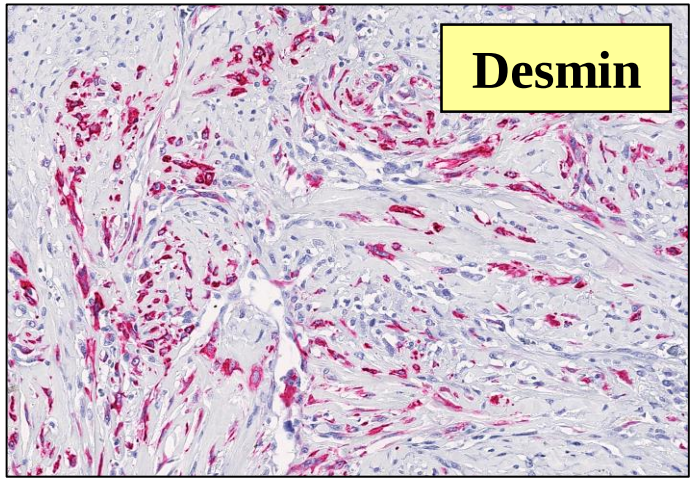
Desmin

Nipple adenoma

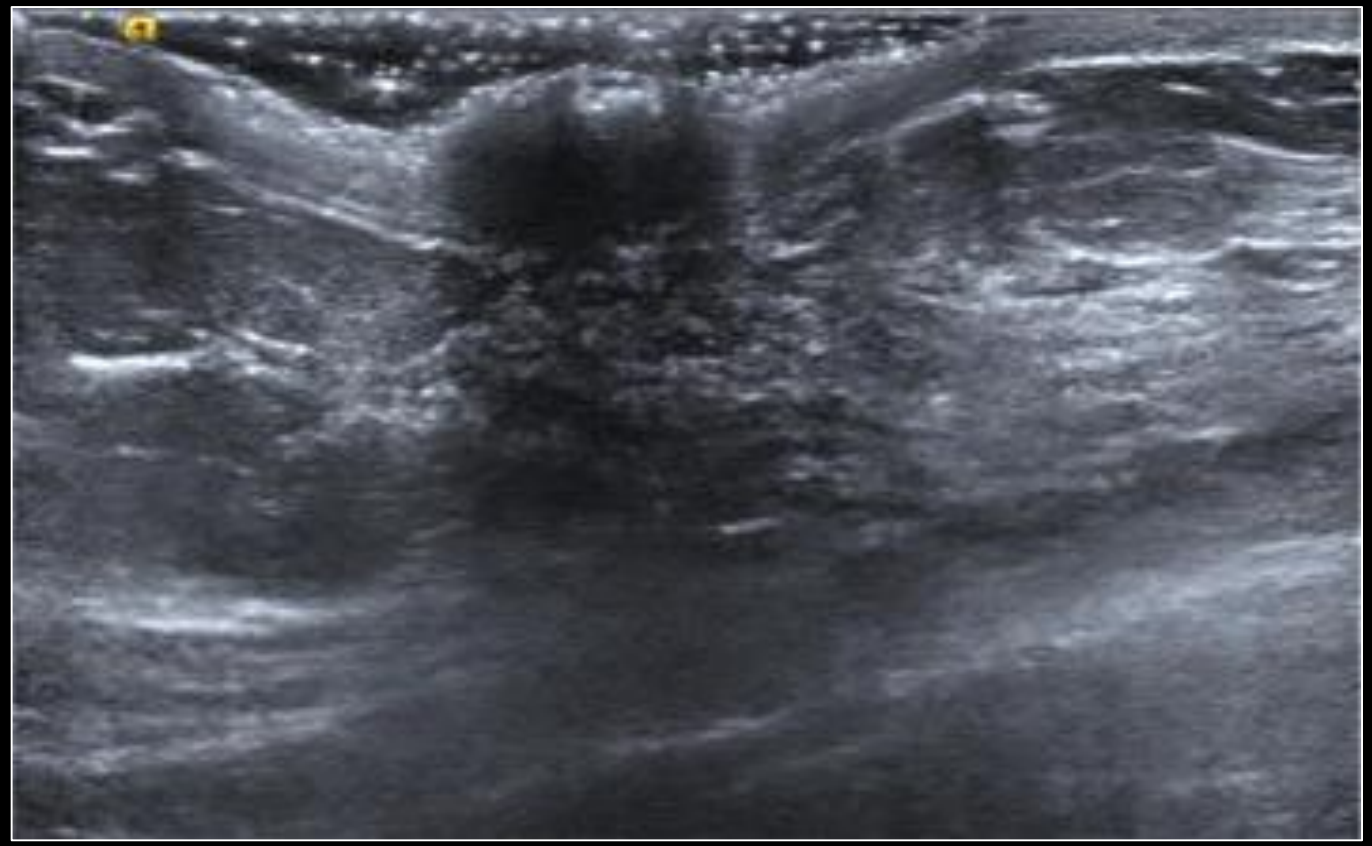

Nipple adenoma - Infiltrating syringomatous adenoma pattern

Obě benigní; výhradní lokalizace v areolo-mamilárním komplexu

Někteří je považují za spektrum jedné léze; strukturálně komplexní, pseudoinvazívní proliferace → CAVE **Ca !** - koincidence s Ca **raritní**

Histopathology

Original Article

Frequent *PIK3CA* activating mutations in nipple adenomas

Jau-Yu Liau, Yi-Hsuan Lee, Jia-Huei Tsai, Chang-Tsu Yuan, Chia-Yu Chu, Jin-Bon Hong, Yi-Shuan Sheen

First published: 21 July 2016 | https://doi.org/10.1111/his.13043 | Citations: 12

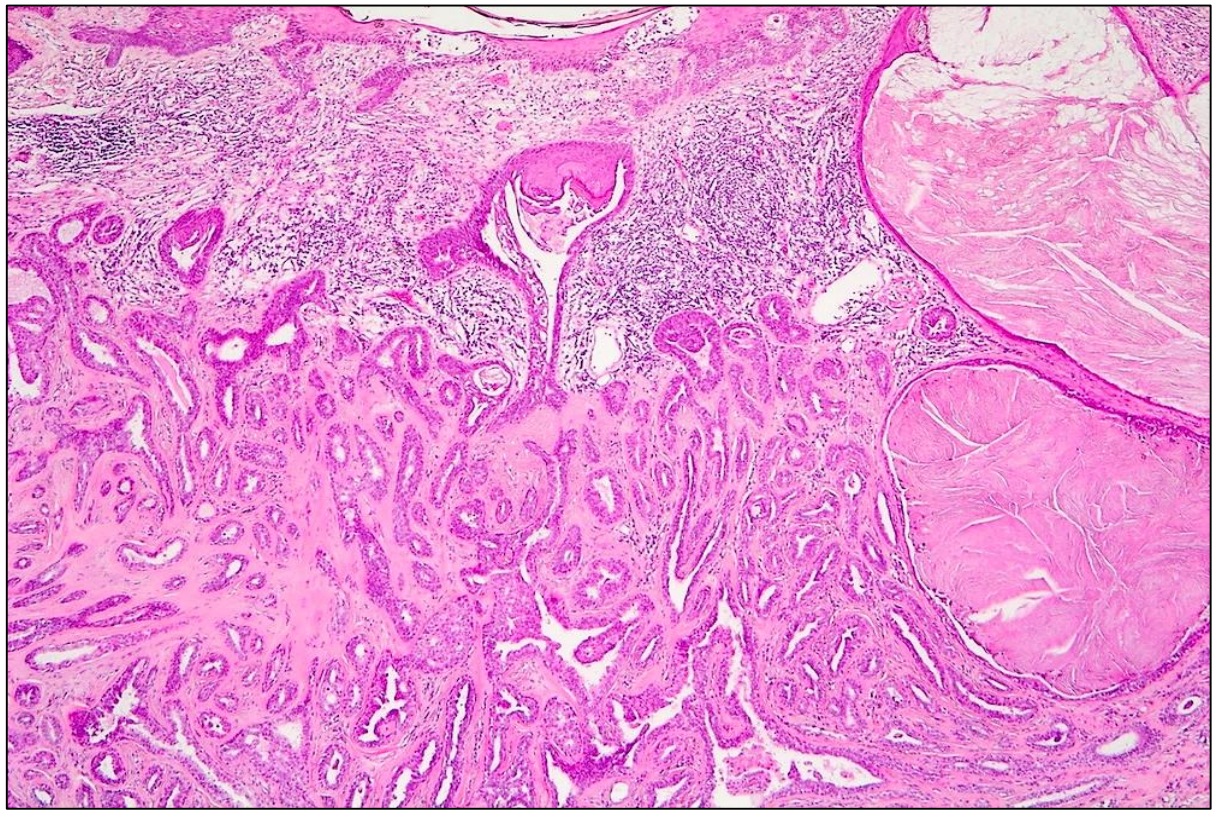

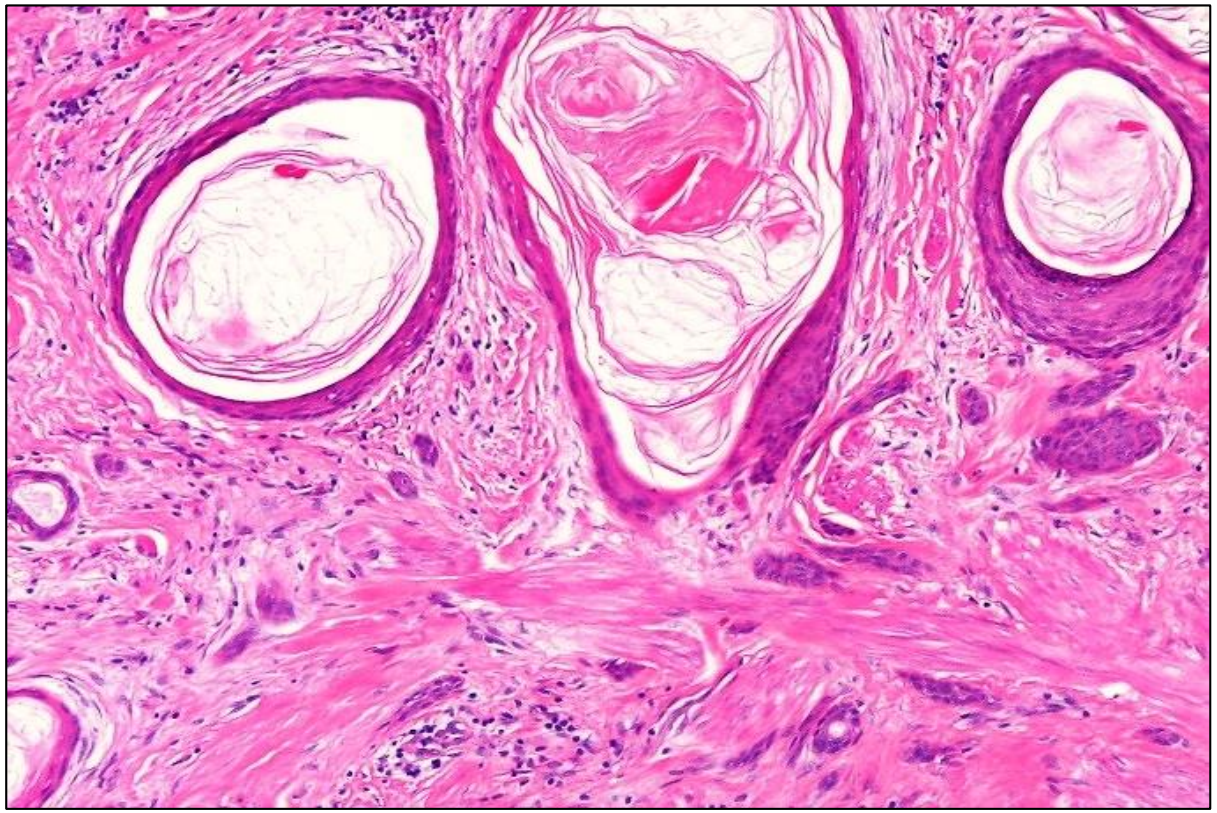

Nipple adenoma - papillary / adenosis-like pattern

Obě benigní; výhradní lokalizace v areolo-mamilárním komplexu

Někteří je považují za spektrum jedné léze; strukturálně komplexní, pseudoinvazívní proliferace → CAVE **Ca !** - koincidence s Ca **raritní**

Histopathology

Original Article

Frequent *PIK3CA* activating mutations in nipple adenomas

Jau-Yu Liau, Yi-Hsuan Lee, Jia-Huei Tsai, Chang-Tsu Yuan, Chia-Yu Chu, Jin-Bon Hong, Yi-Shuan Sheen

First published: 21 July 2016 | https://doi.org/10.1111/his.13043 | Citations: 12

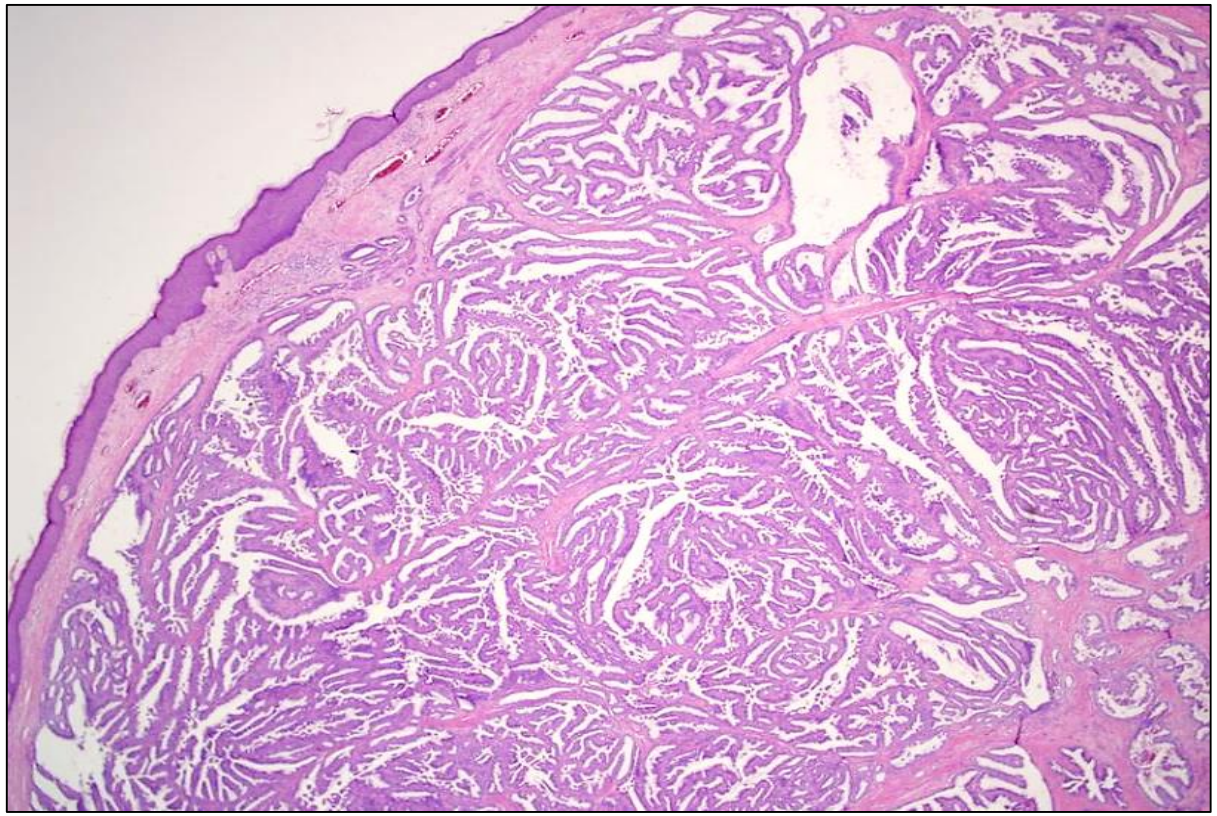

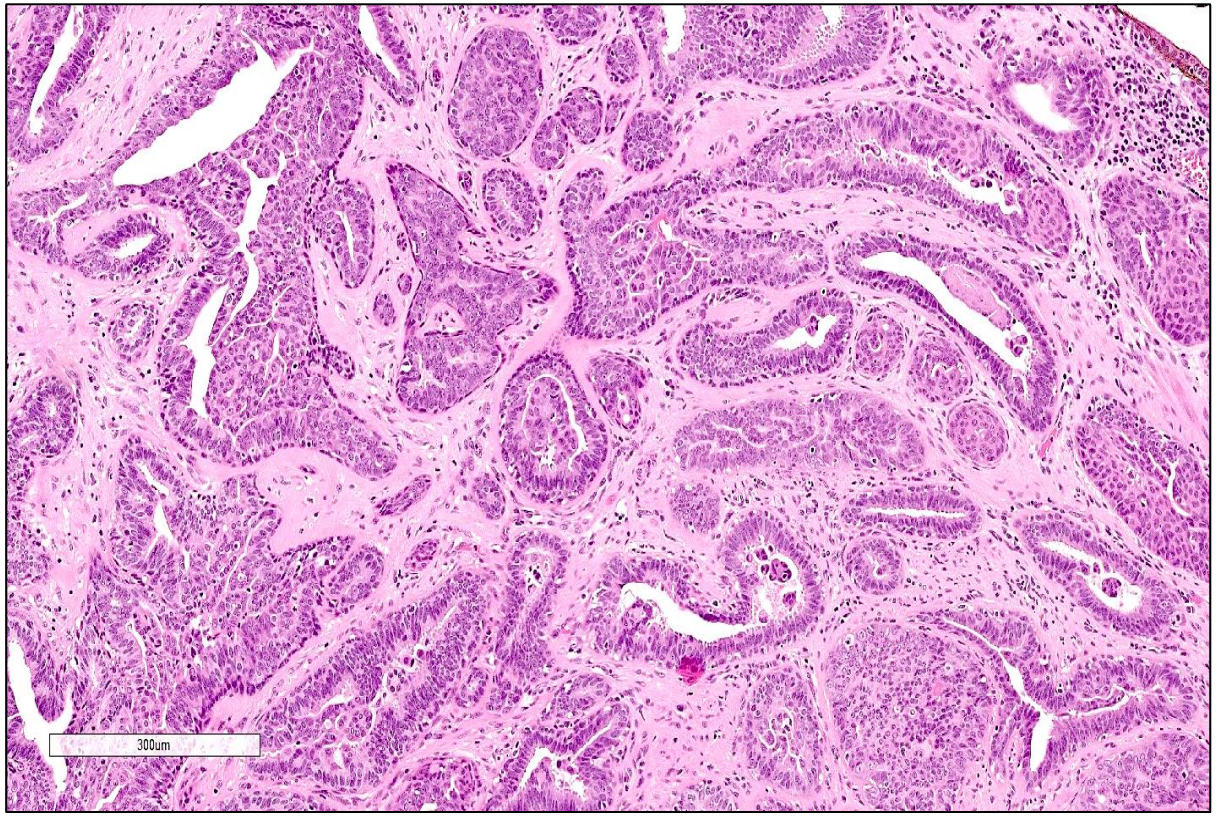

Ann Dermatol Vol. 33, No. 2, 2021
pISSN 1013-9087 · eISSN 2005-3894
https://doi.org/10.5021/ad.2021.33.2.182

CASE REPORT

Cryosurgery as a Minimally Invasive Alternative Treatment for a Patient with Erosive Adenomatosis of the Nipple

Kyung-Nam Bae[1,2], Kihyuk Shin[1], Woo-Il Kim[1], Min-Young Yang[1], Won-Ku Lee[1], Hoon-Soo Kim[1,2], Hyun-Chang Ko[1], Byung-Soo Kim[1,2], Moon-Bum Kim[1,2], Gun-Wook Kim[3]

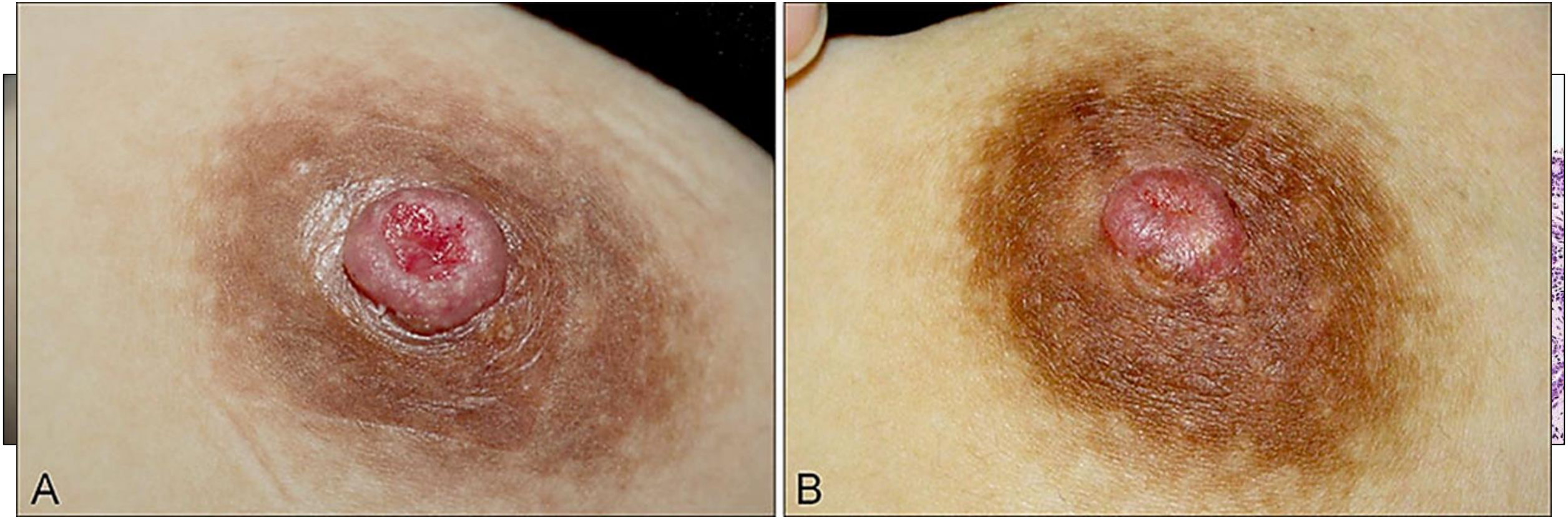

Dx. - LG adenosquamous carcinoma

Uložen ve vlastní žláze

V okolí RSL / papilomu

Časté lymfocytární agregáty

Indolentní **3N** tumor

Prakticky **ne**metastázuje …

Extirpace, bez další terapie

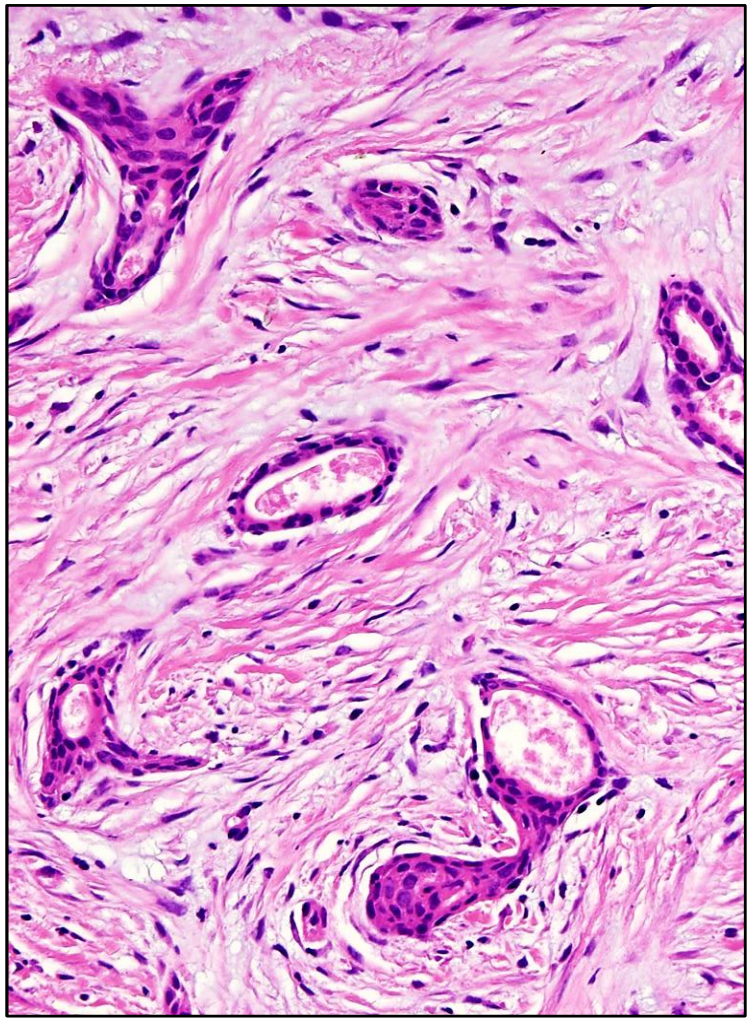

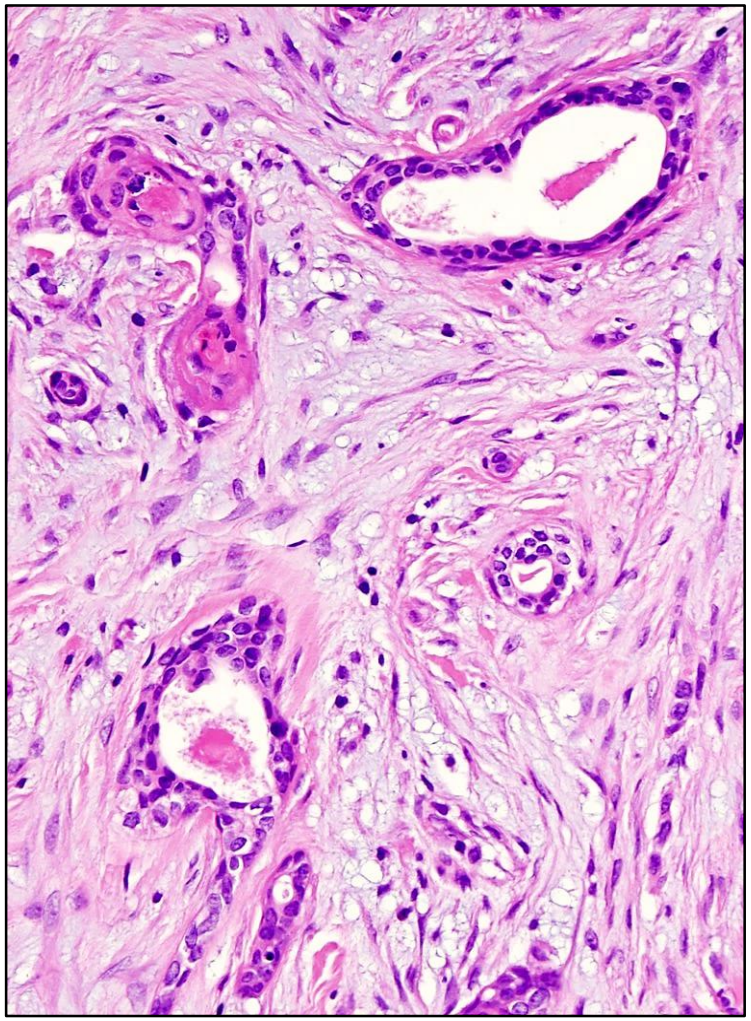

žena, **67** let

Dg. patologa: **Tubulární karcinom s přechodem do metaplastického karcinomu ?**

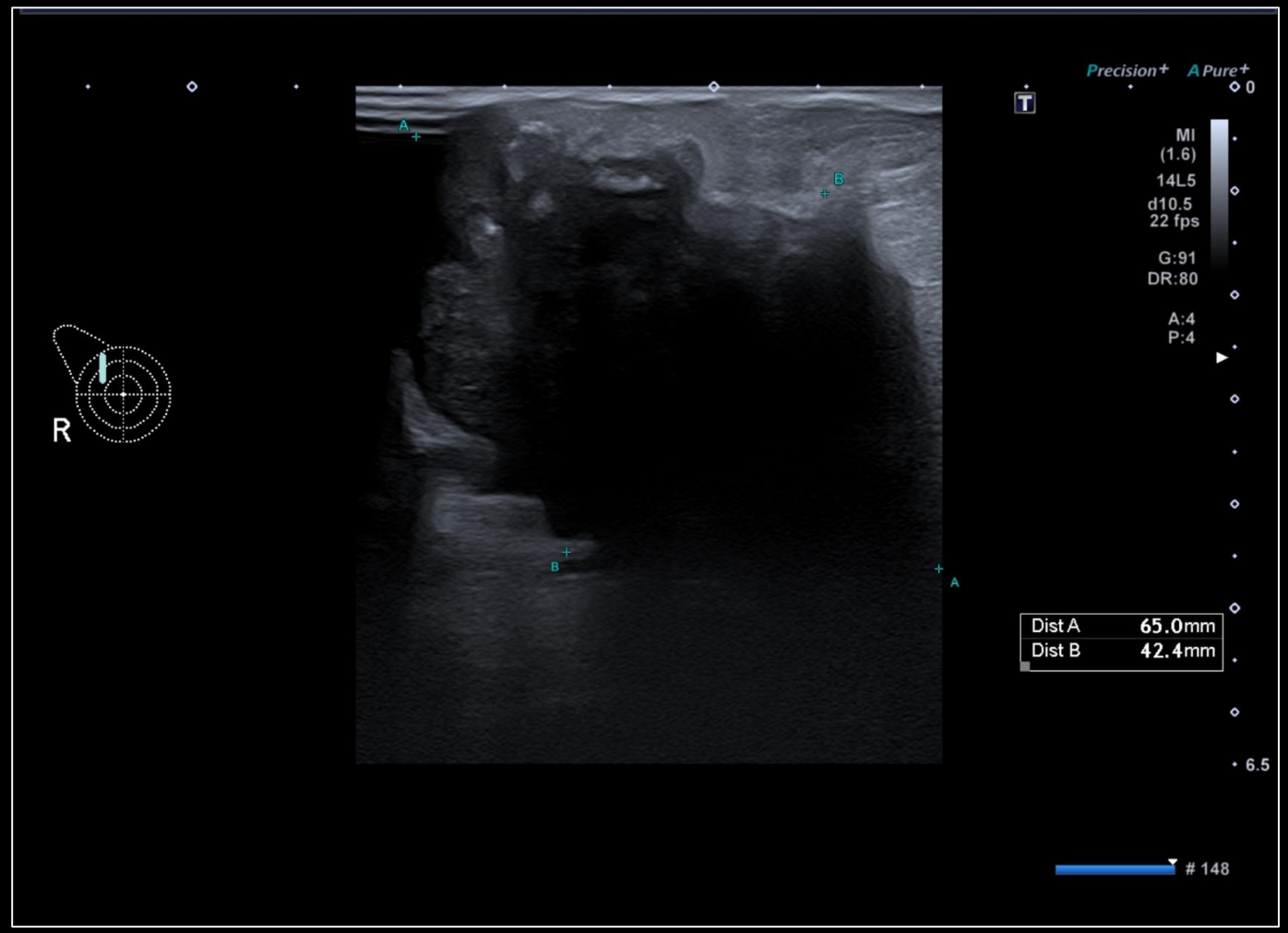

laskavě Dr. Beran, Mediag, KV

32 354/24
0
1
2
3
4
5
6
7
8
9
10

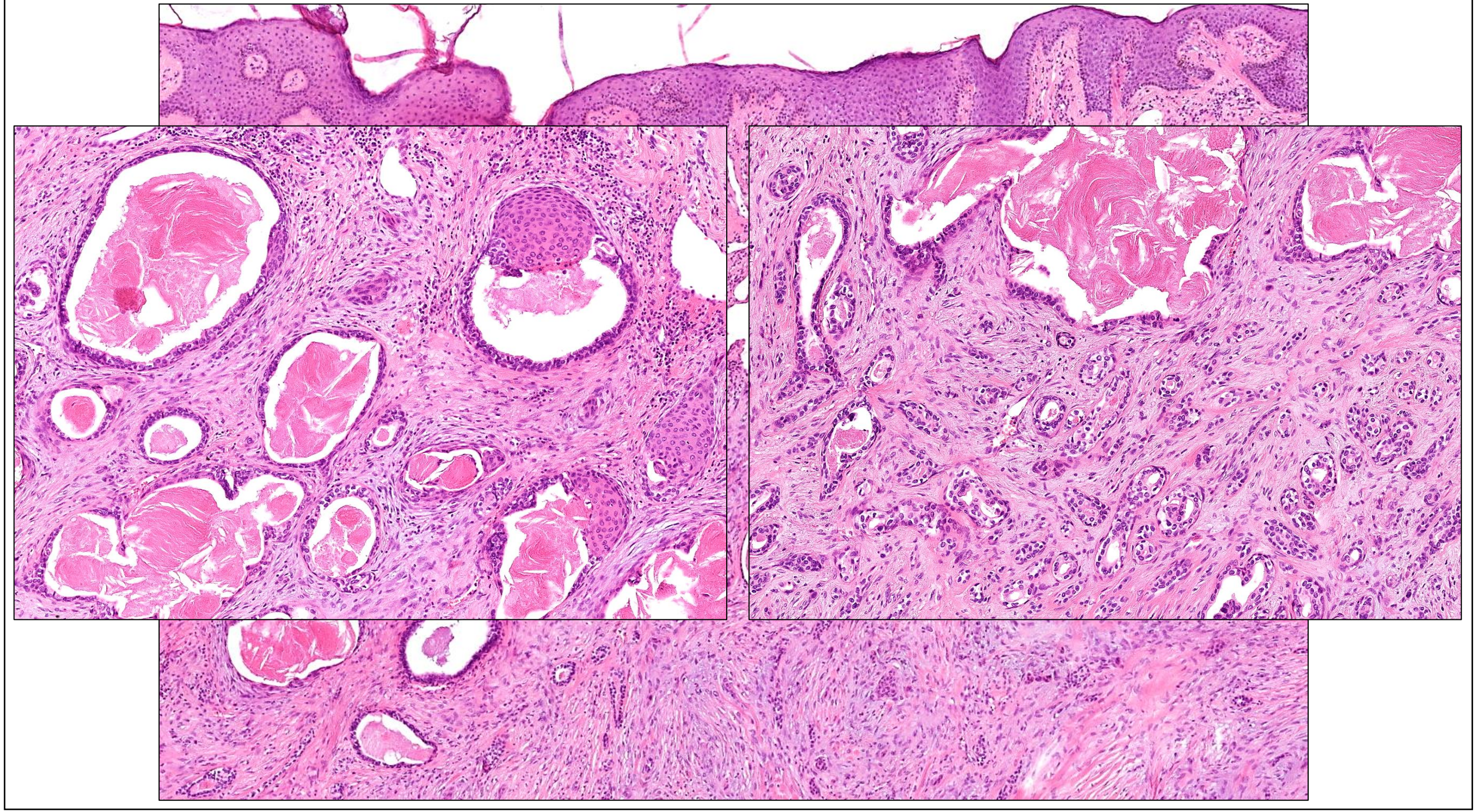

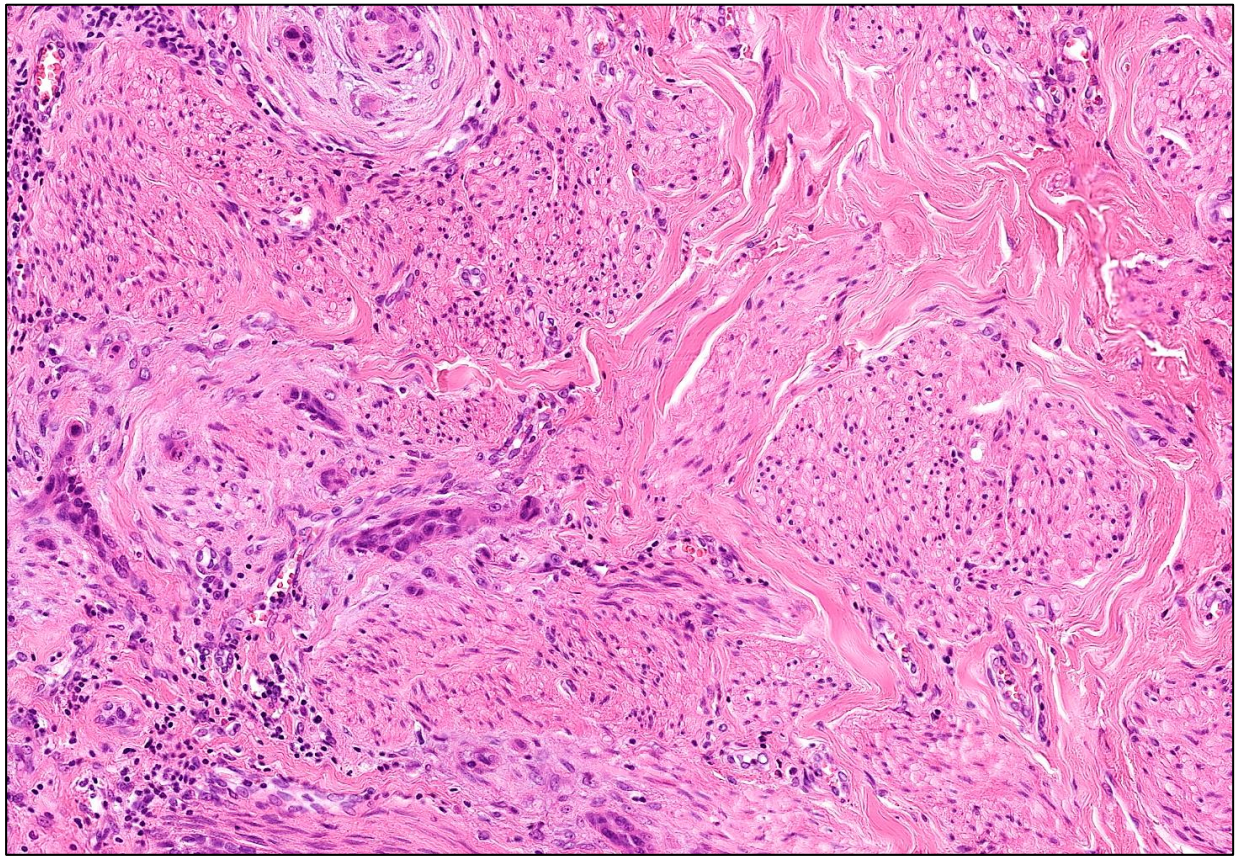

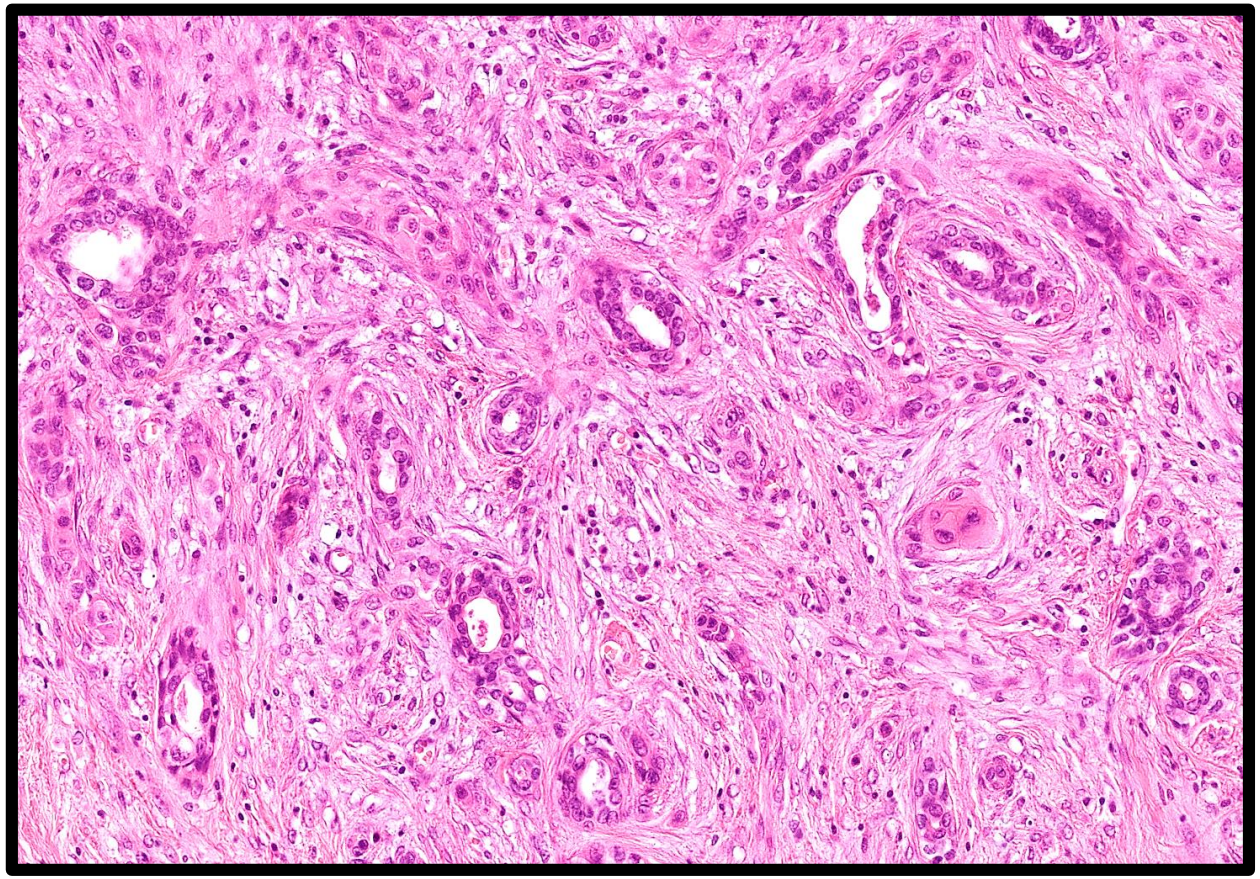

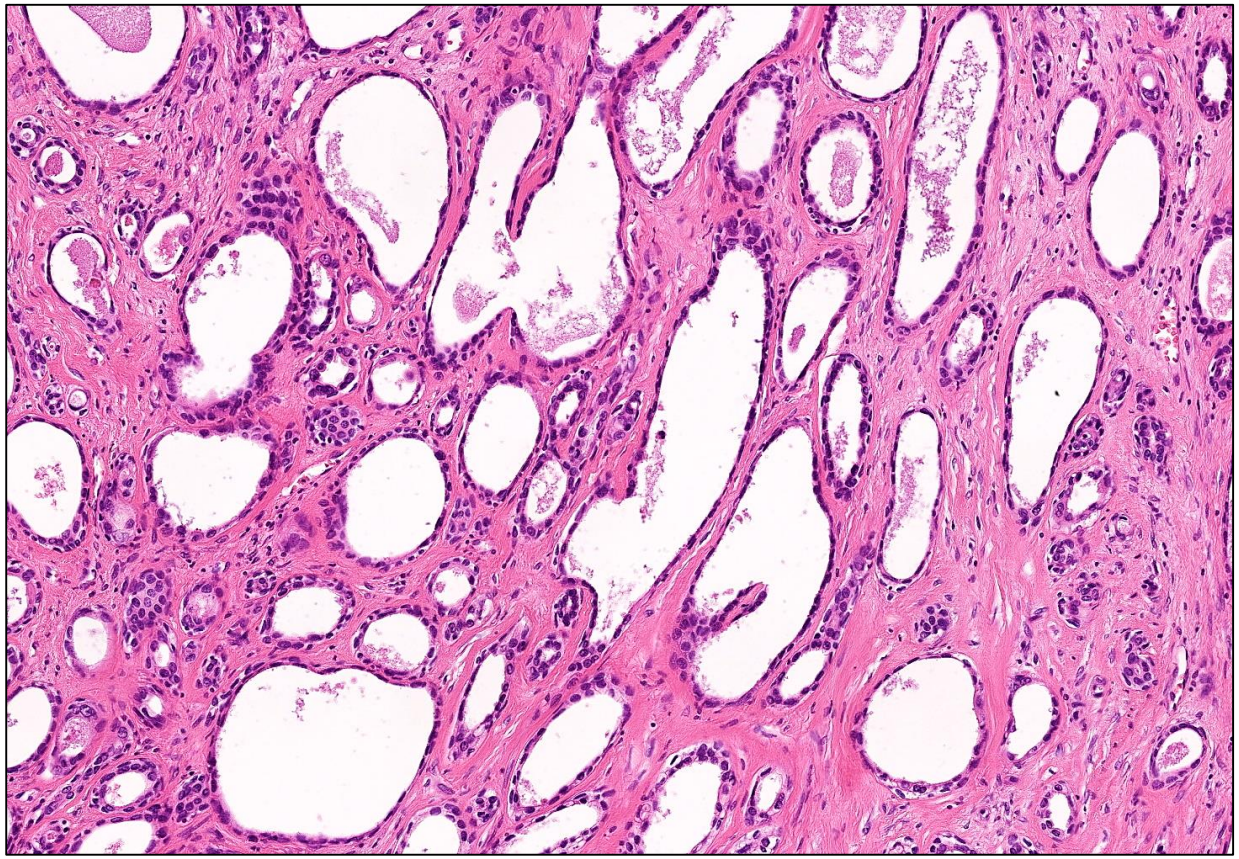

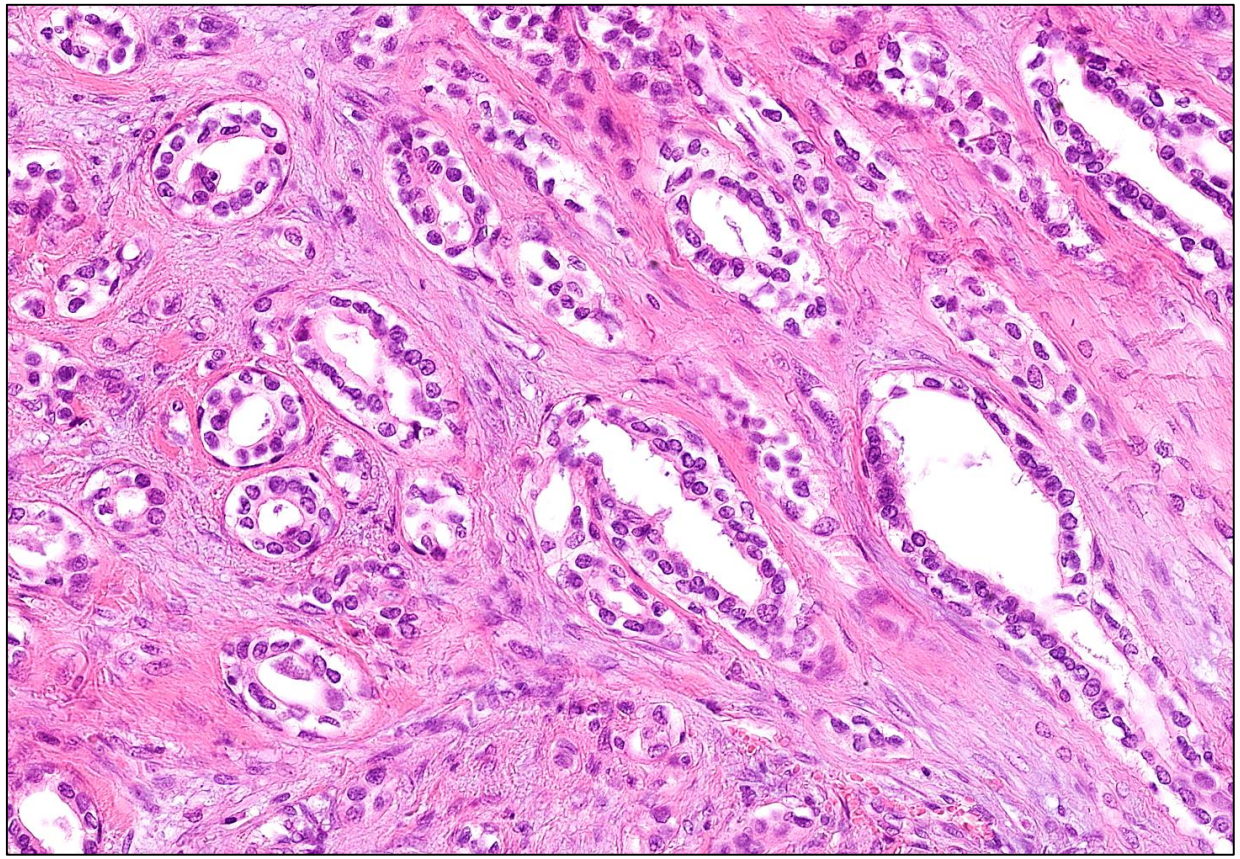

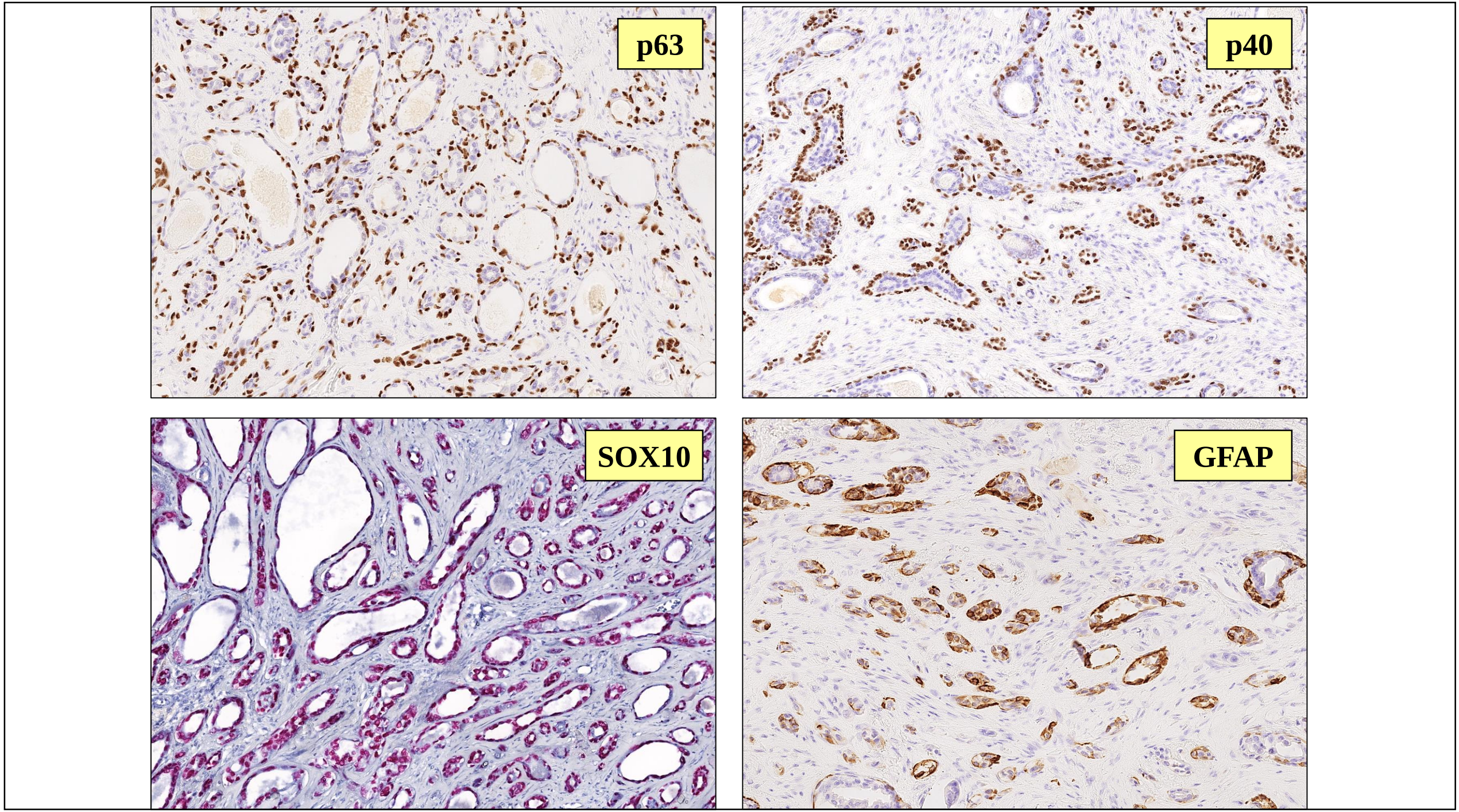
p63
p40
SOX10
GFAP

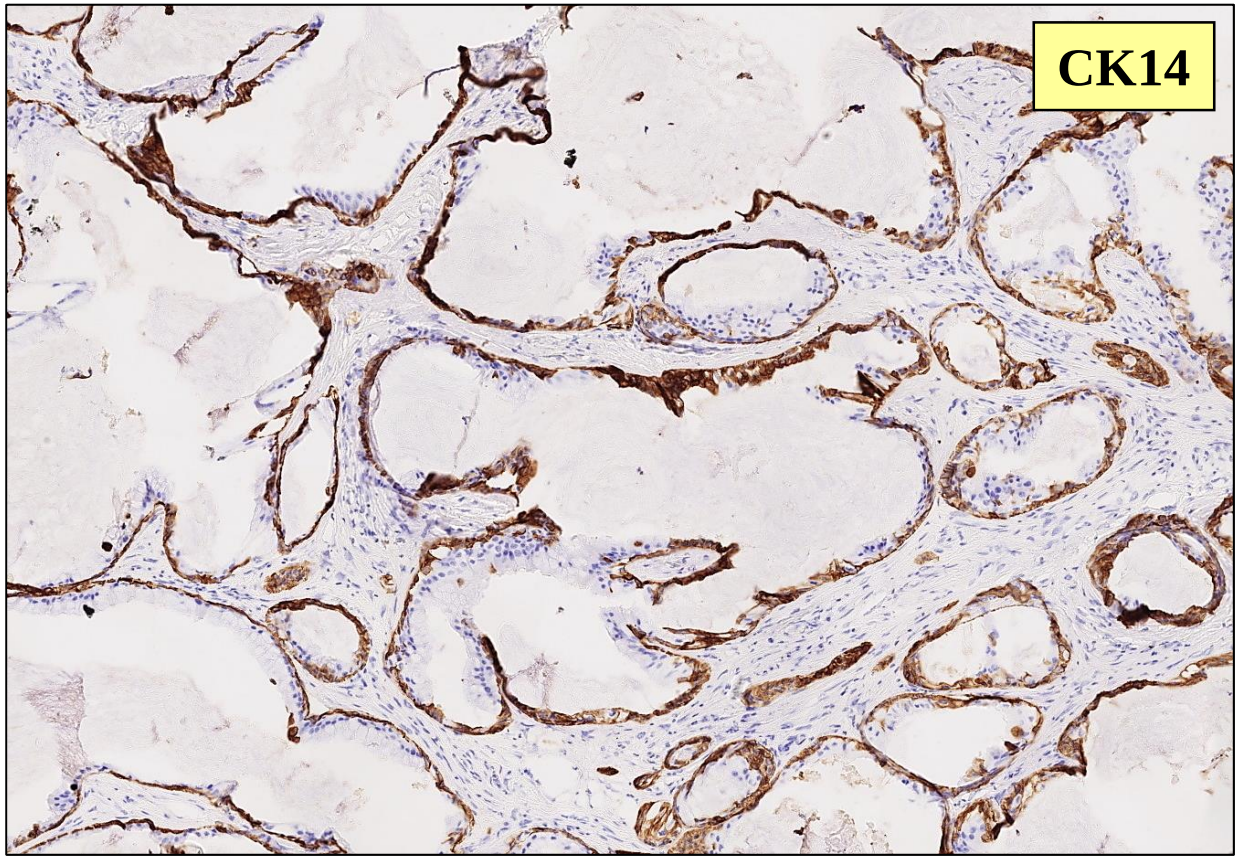
CK14

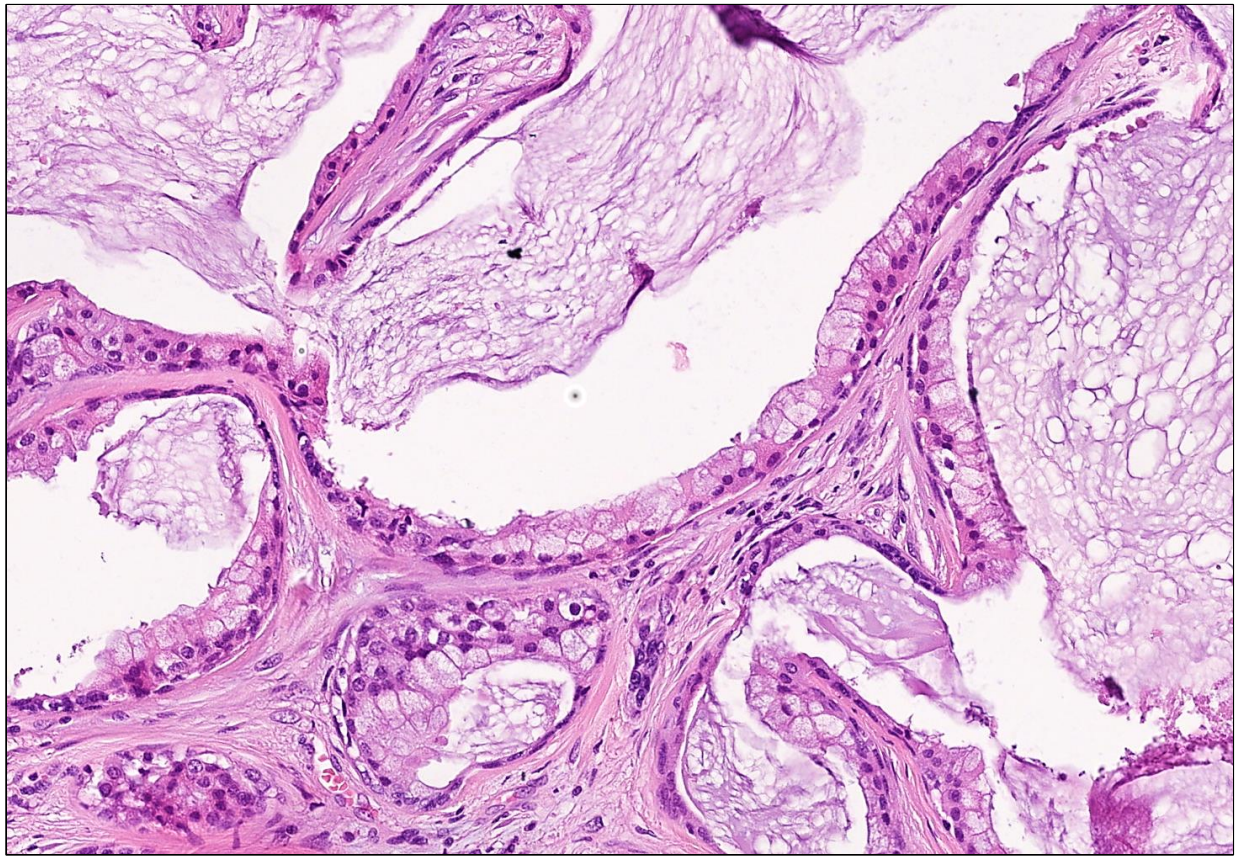

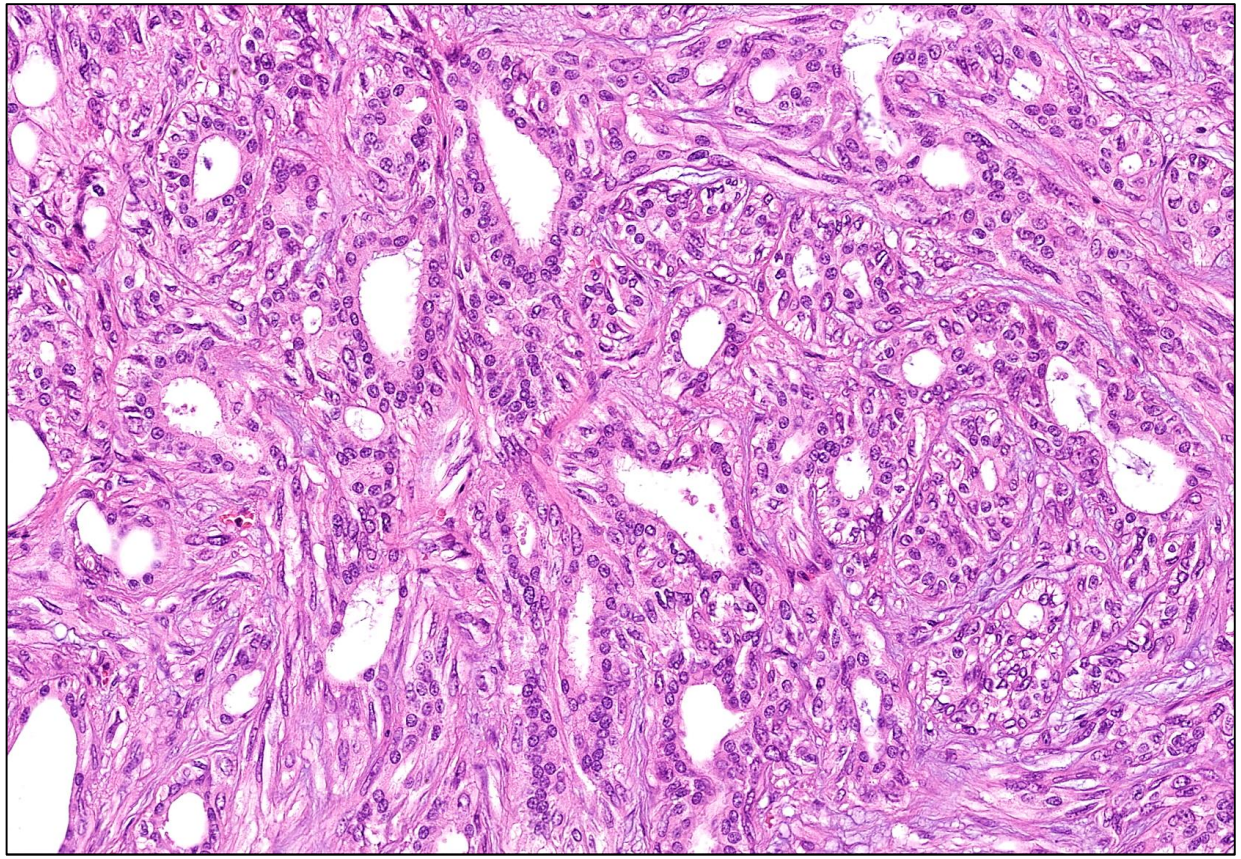

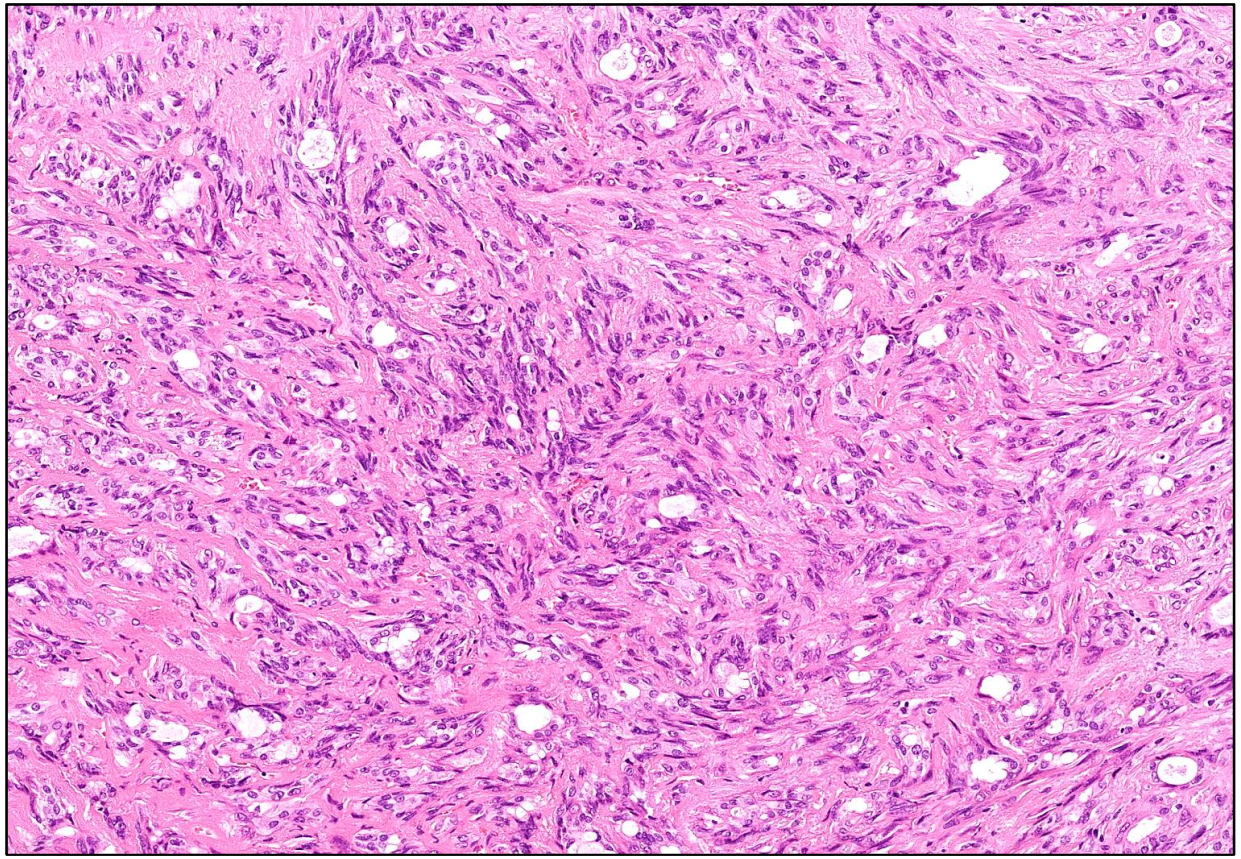

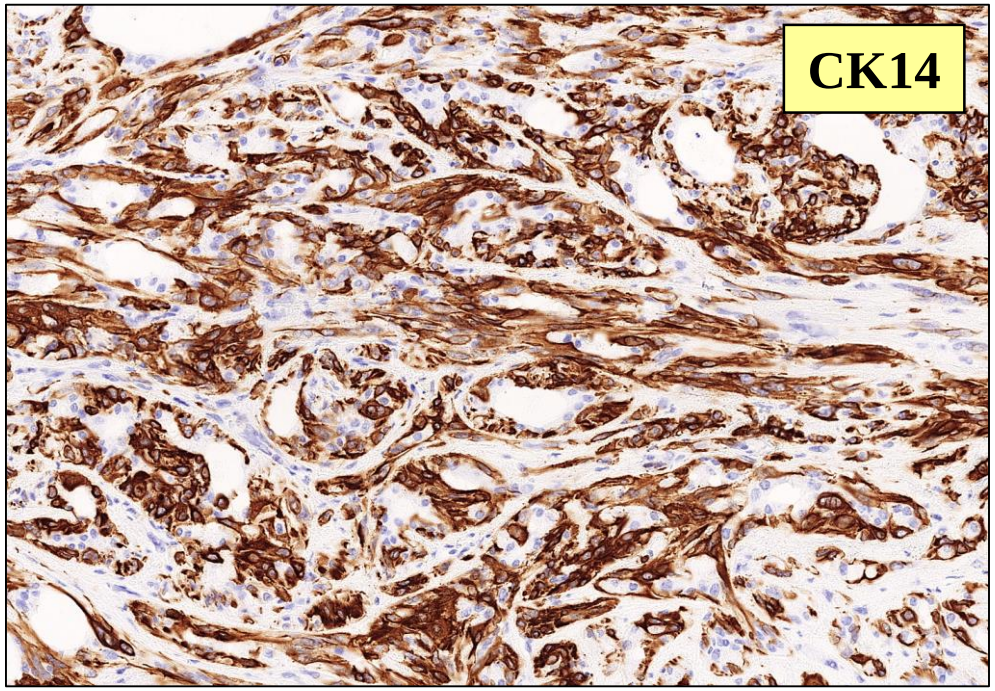
CK14

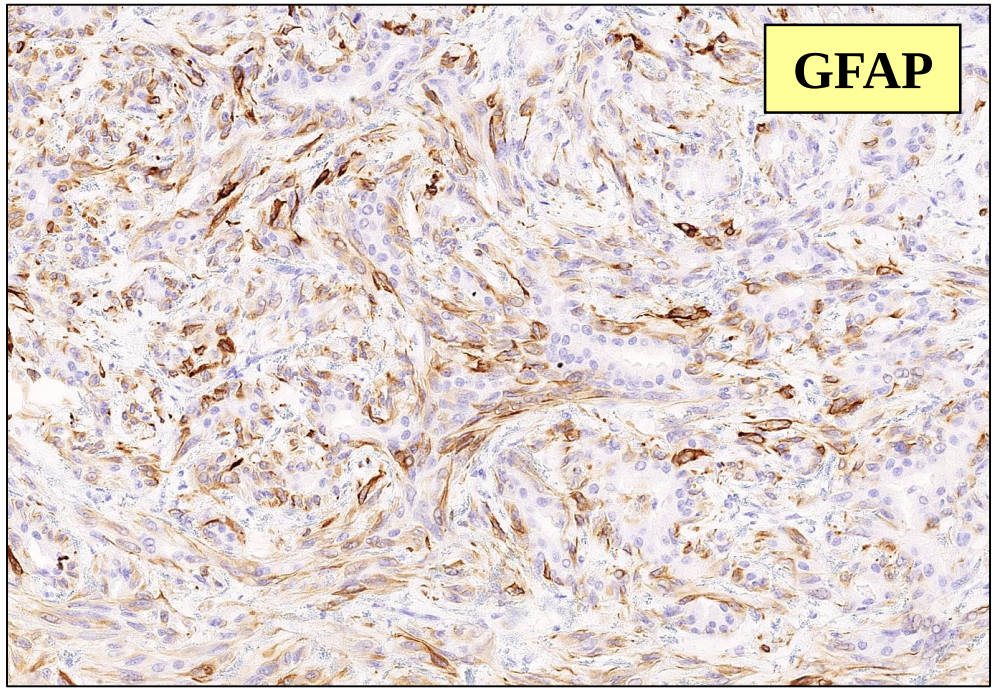
GFAP

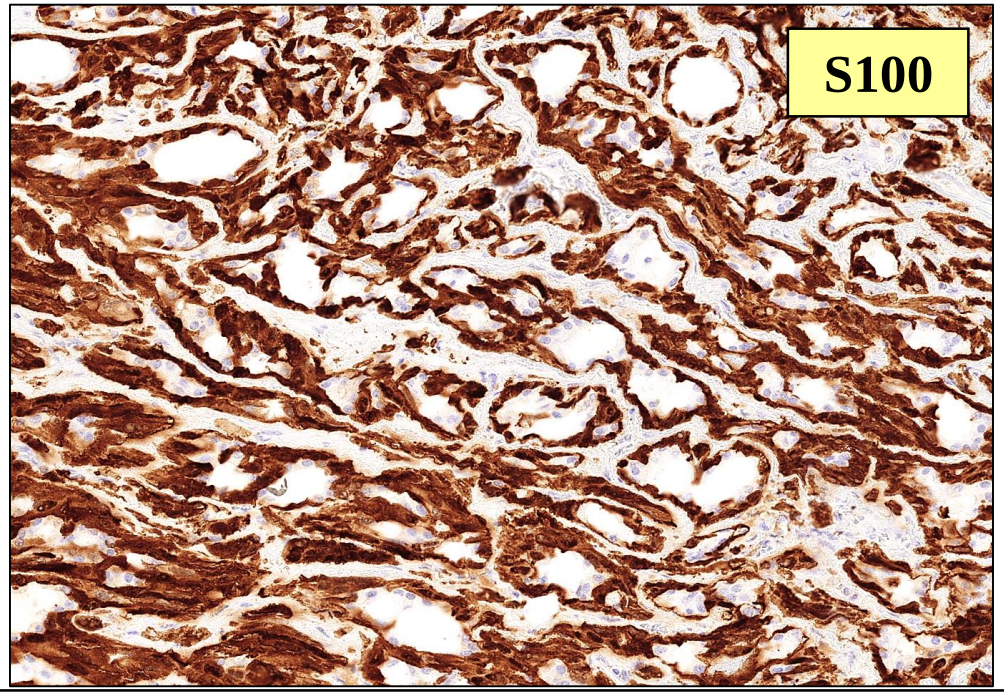
S100

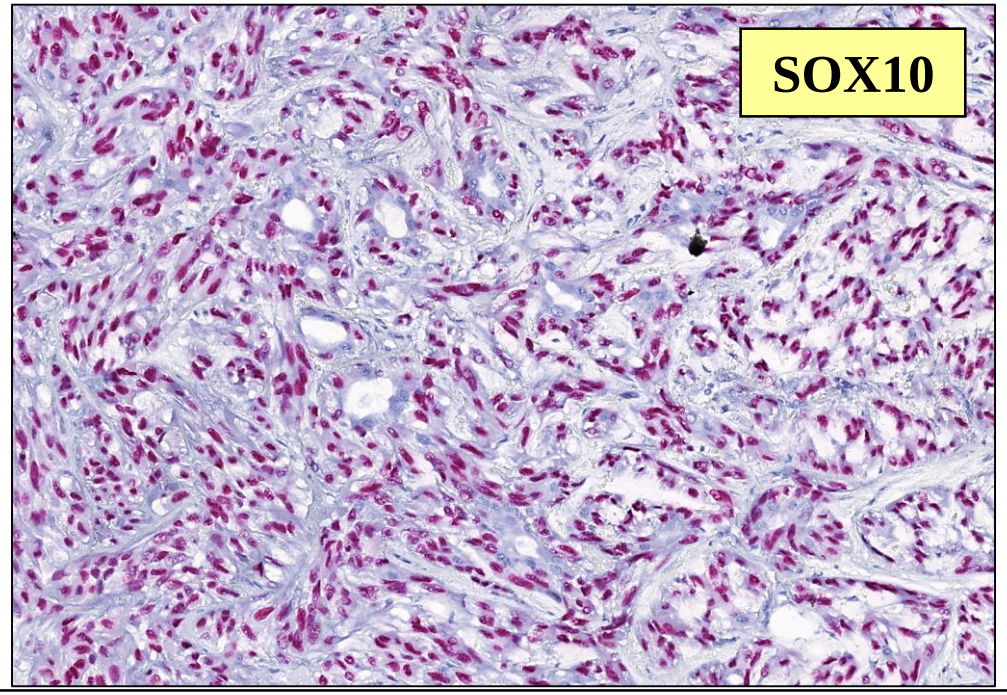
SOX10

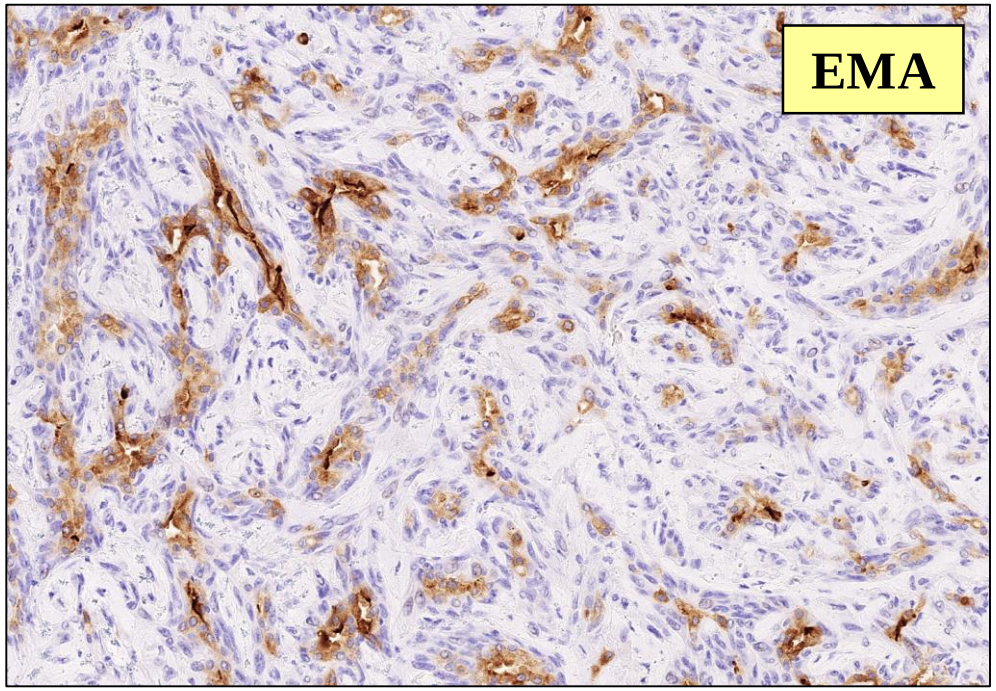
EMA

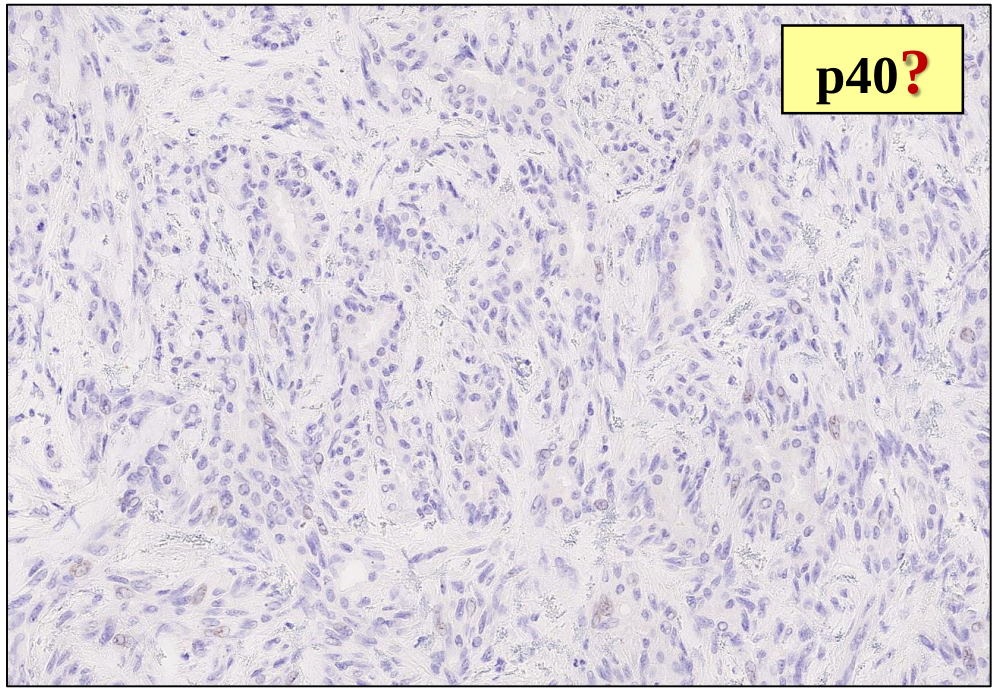
p40?

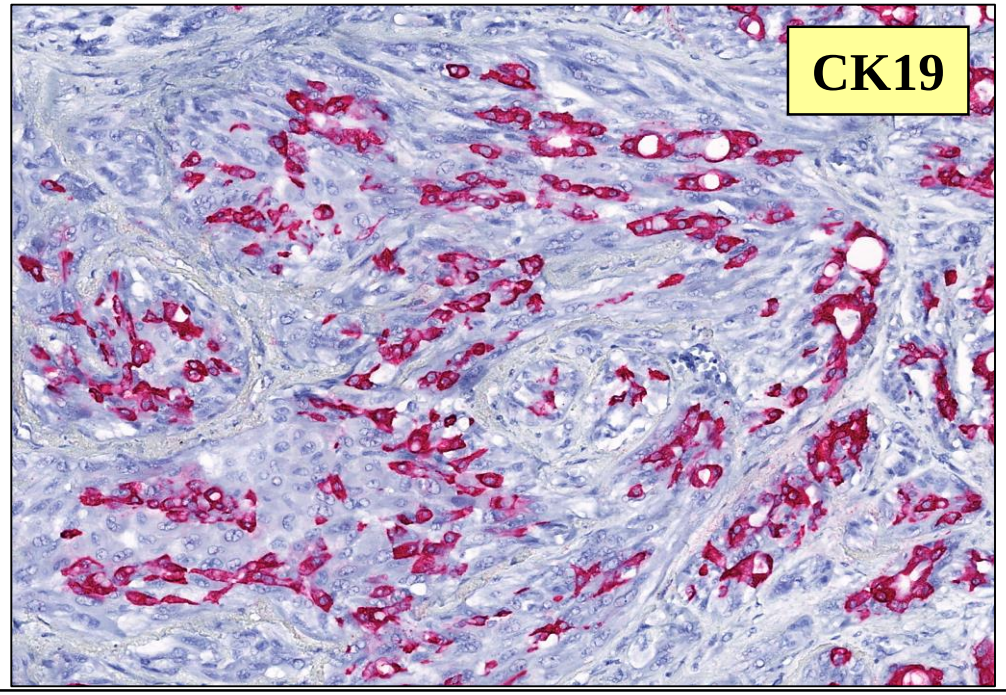
CK19

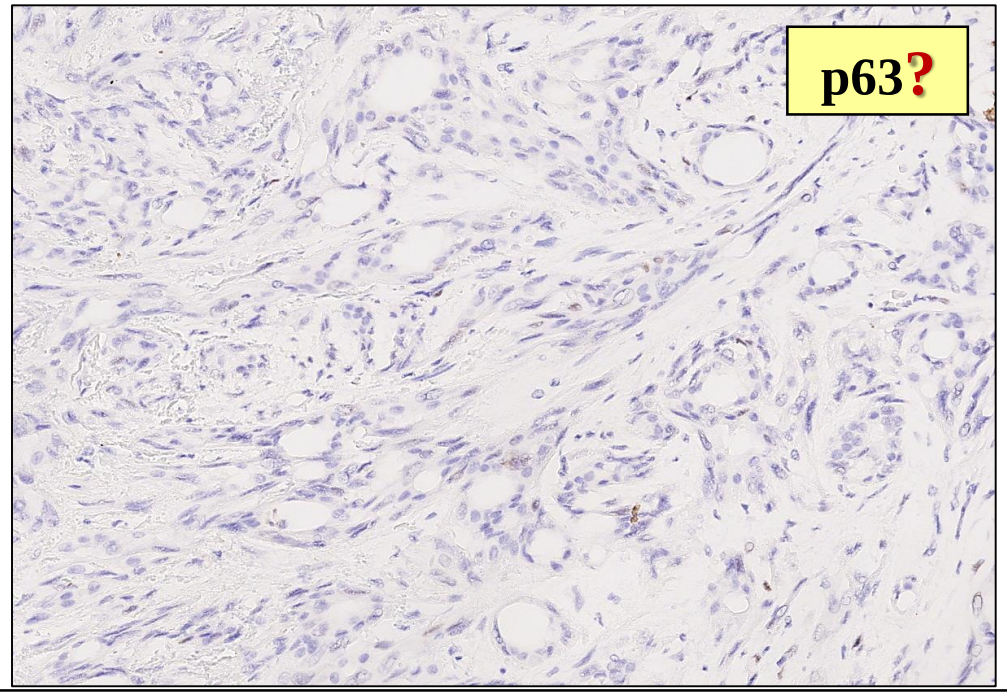
p63?

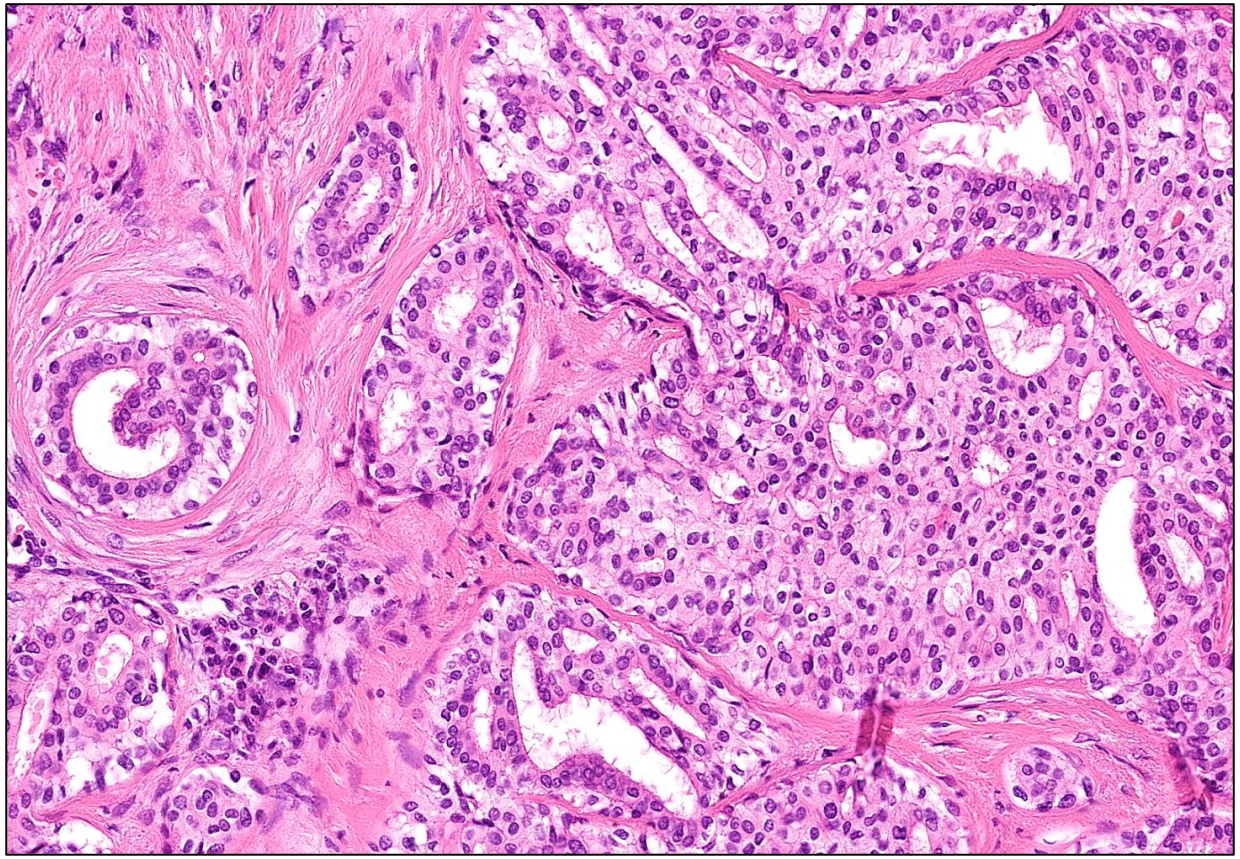

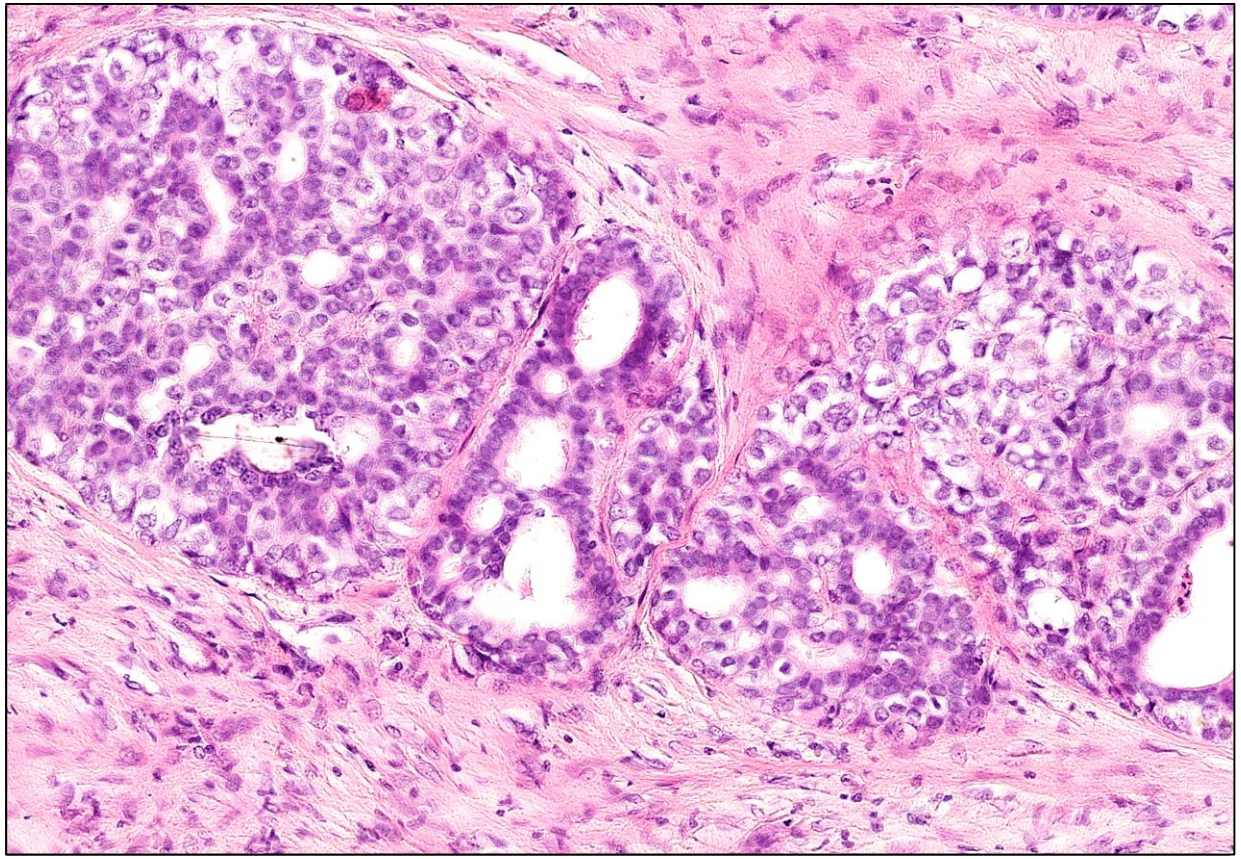

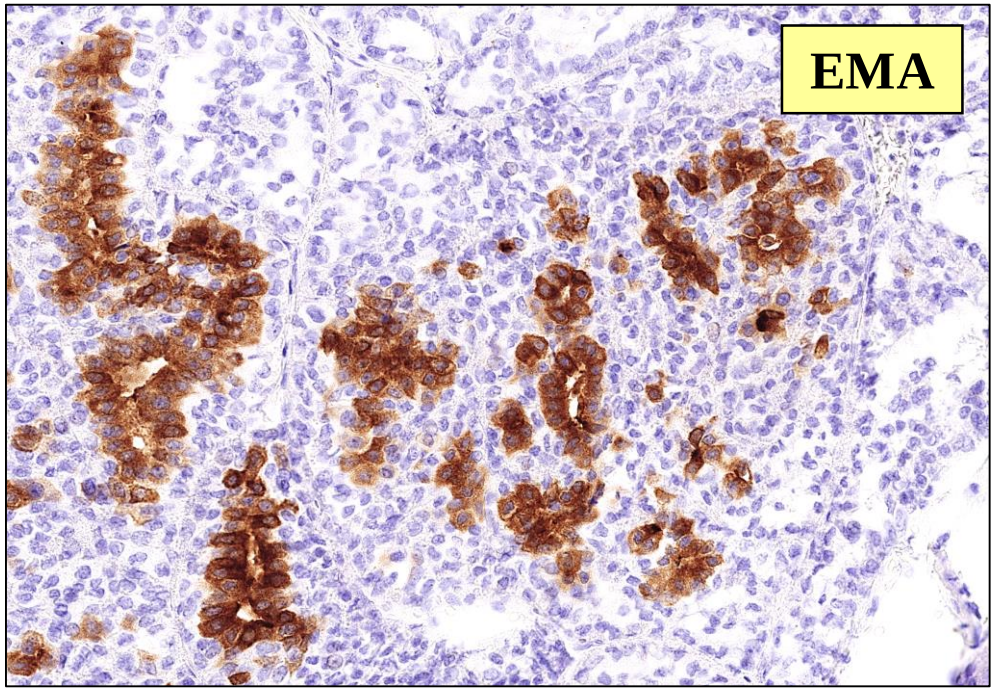
EMA

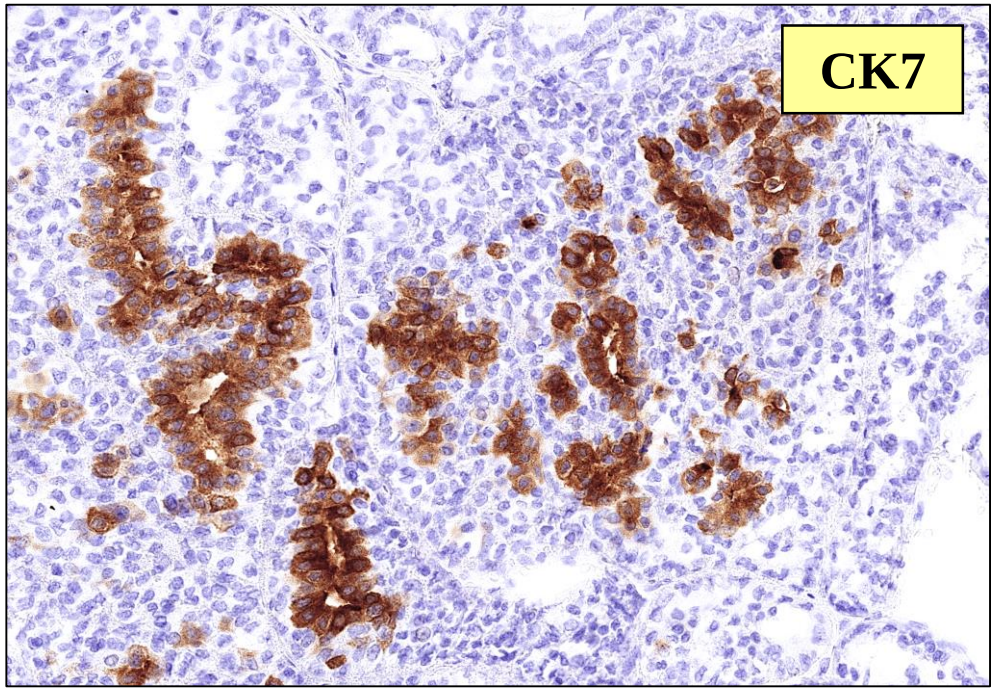
CK7

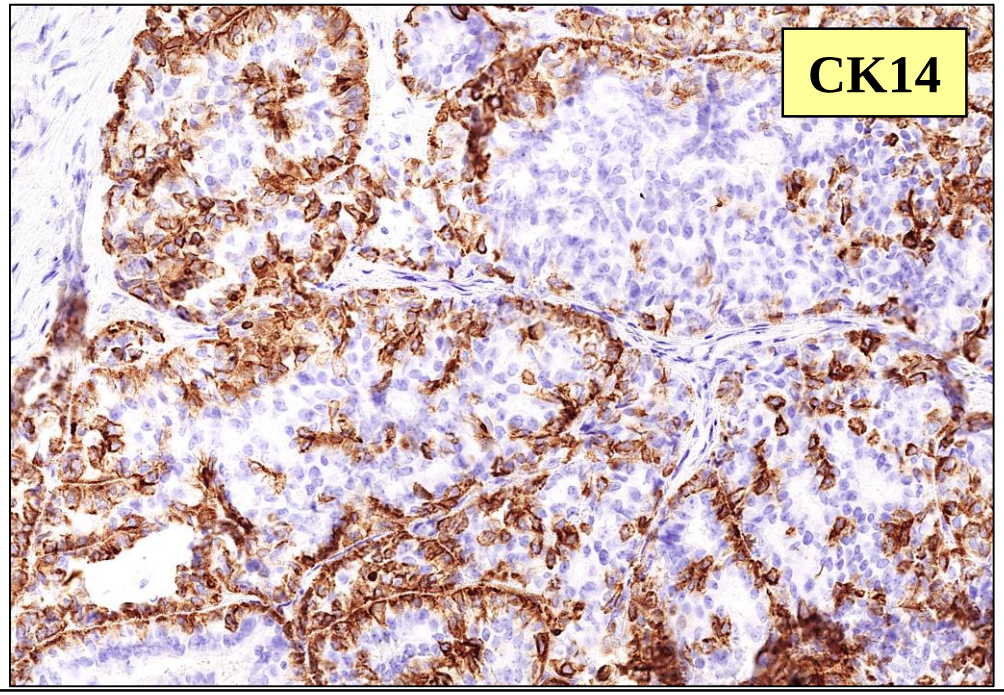
CK14

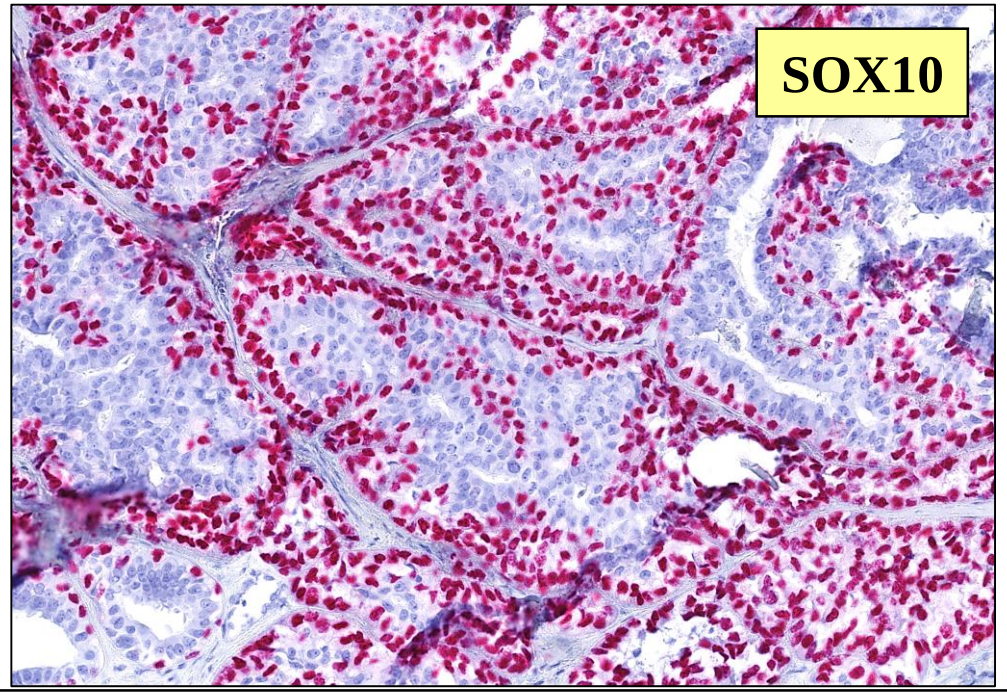
SOX10

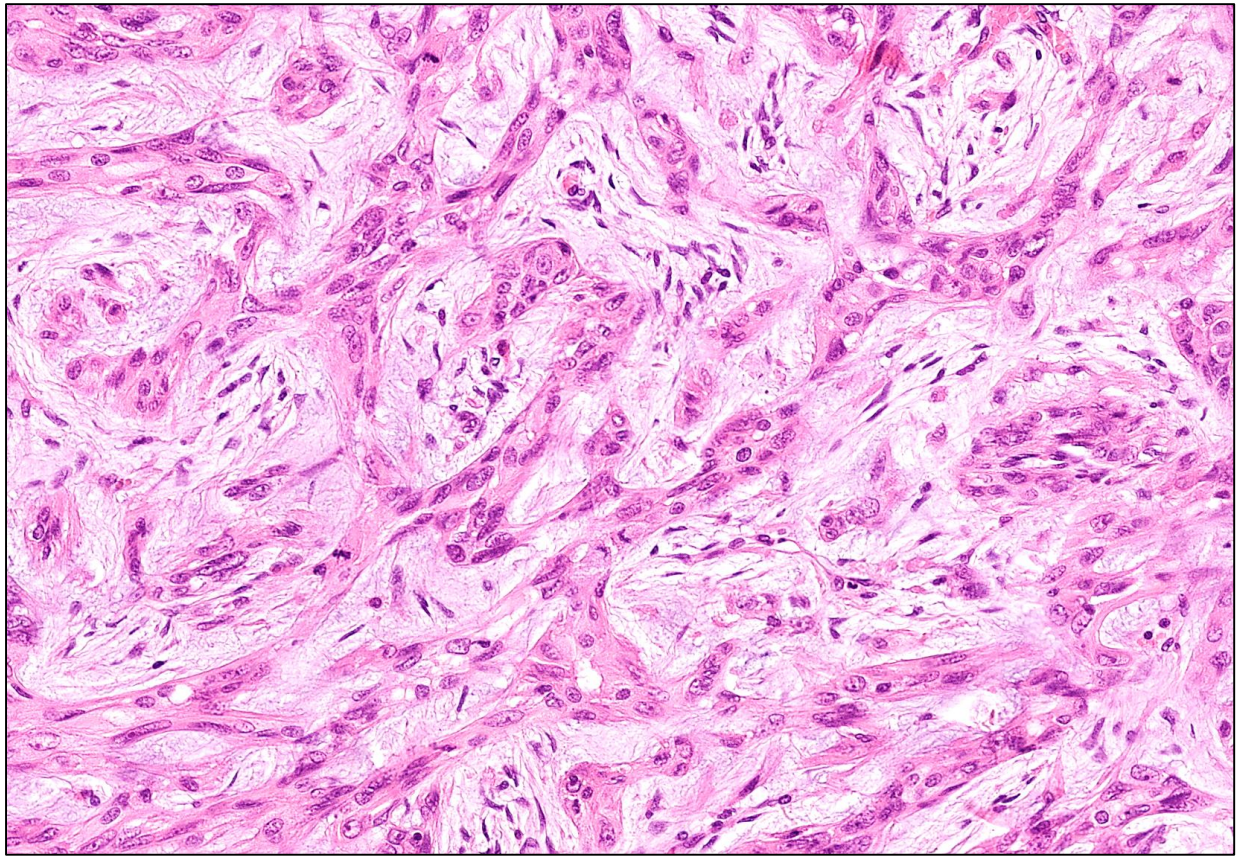

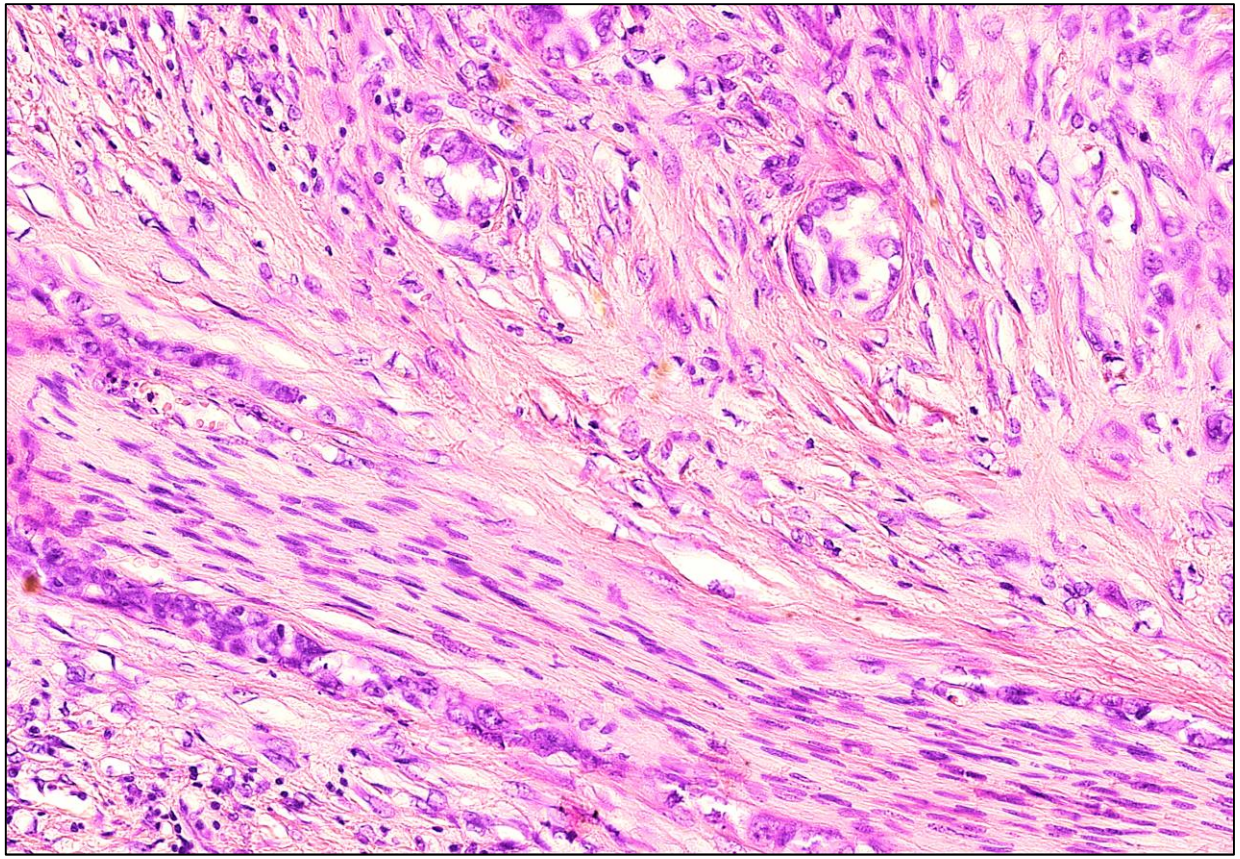

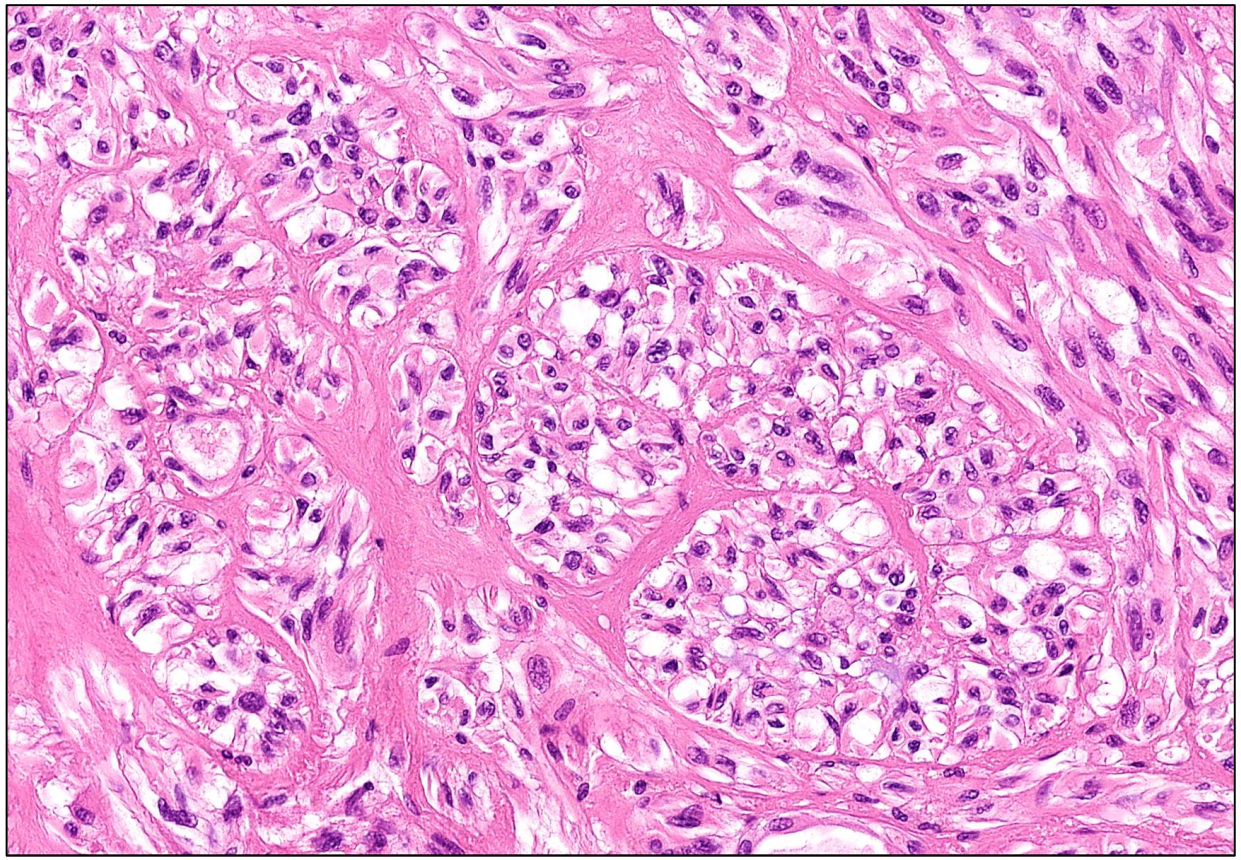

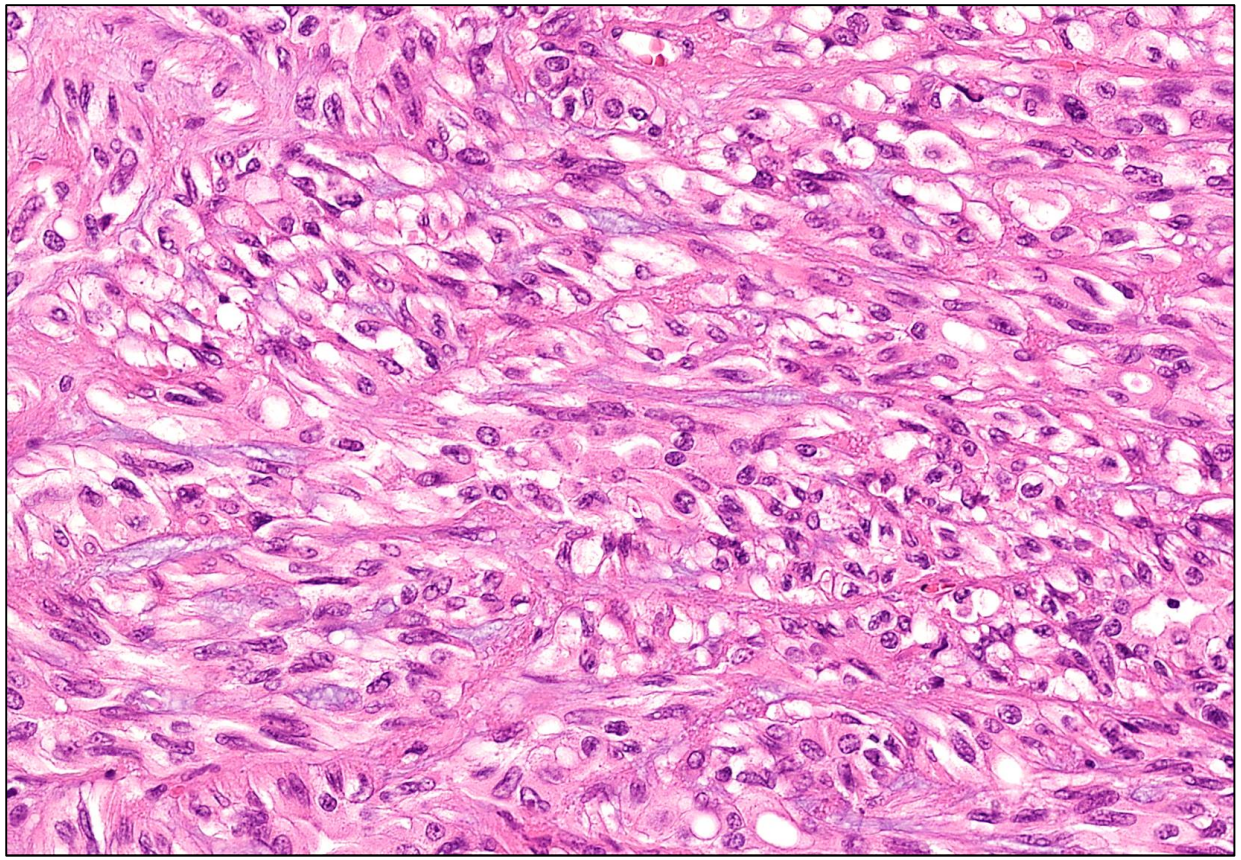

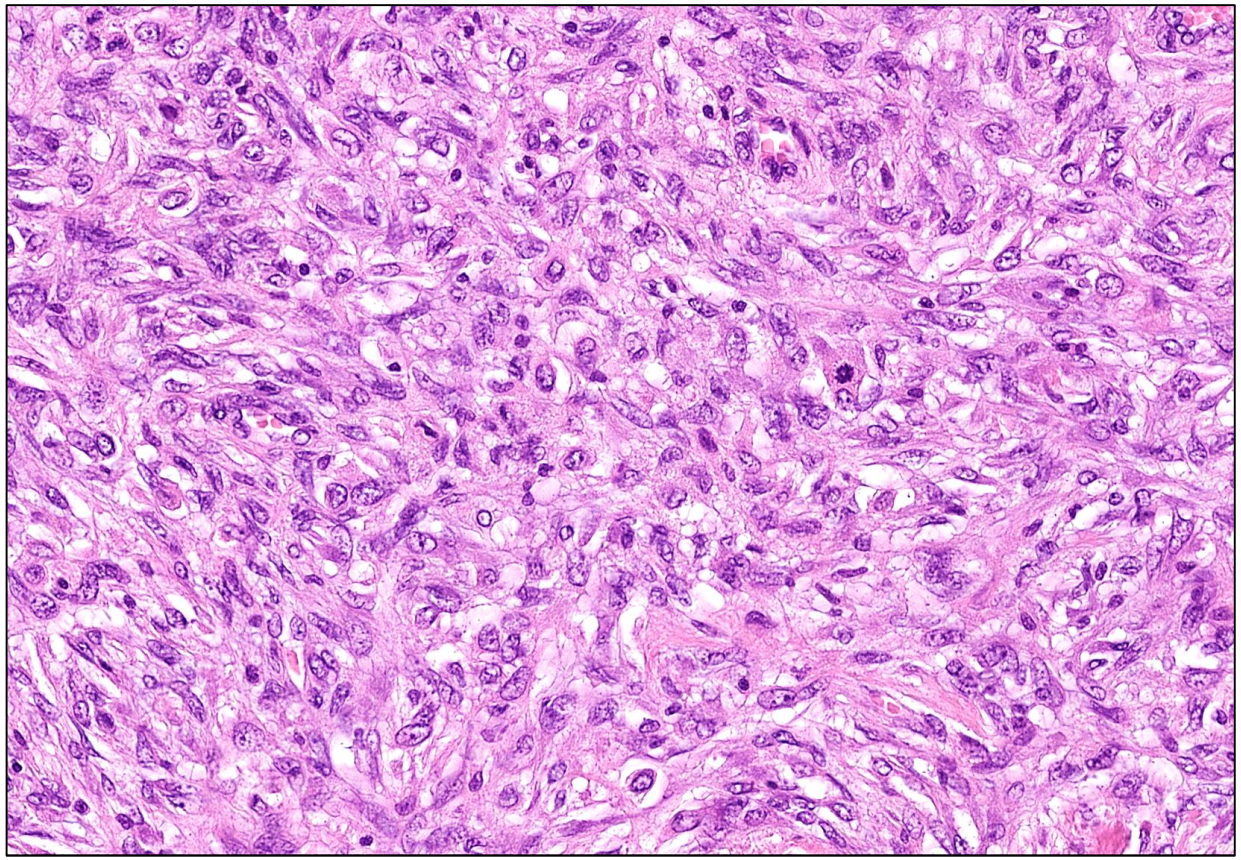

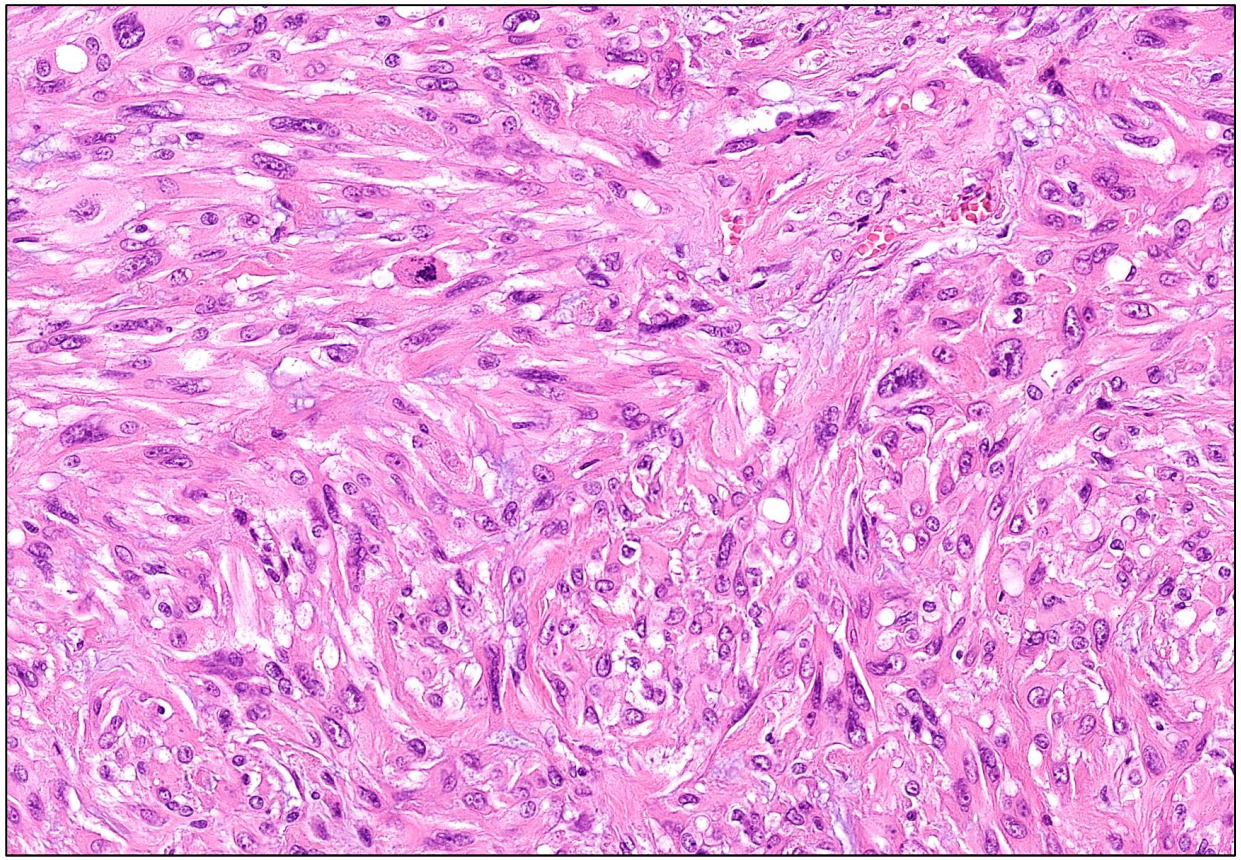

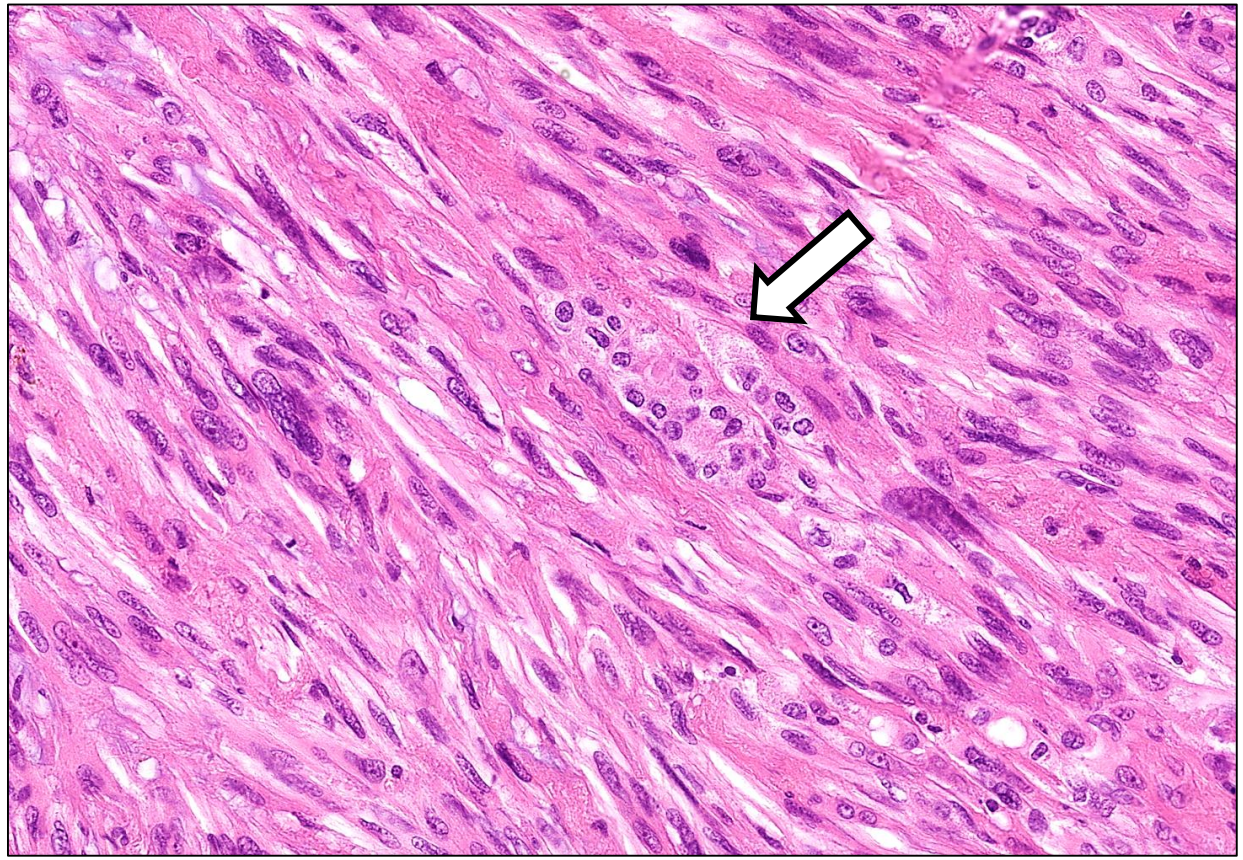

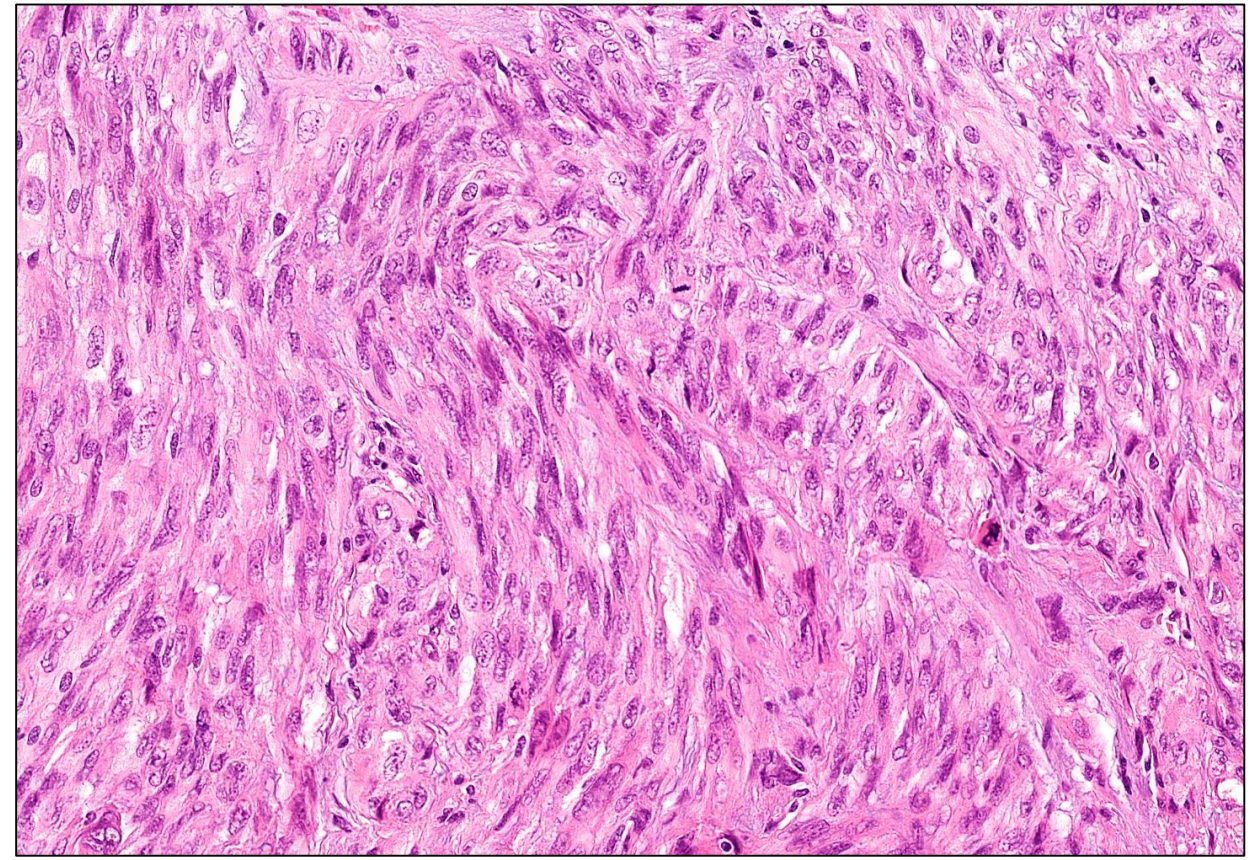

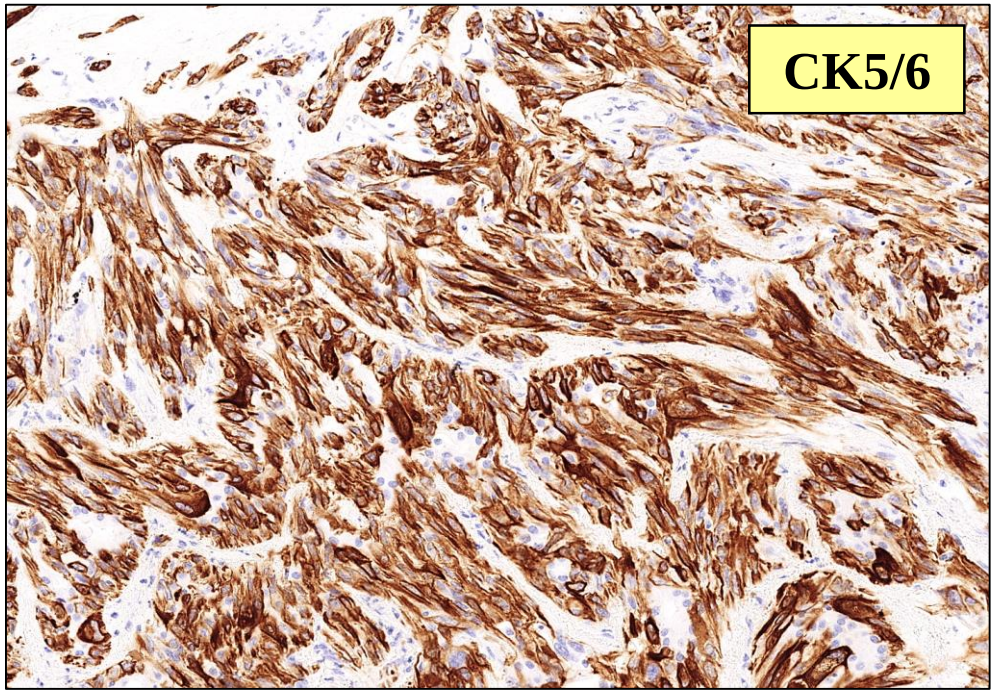
CK5/6

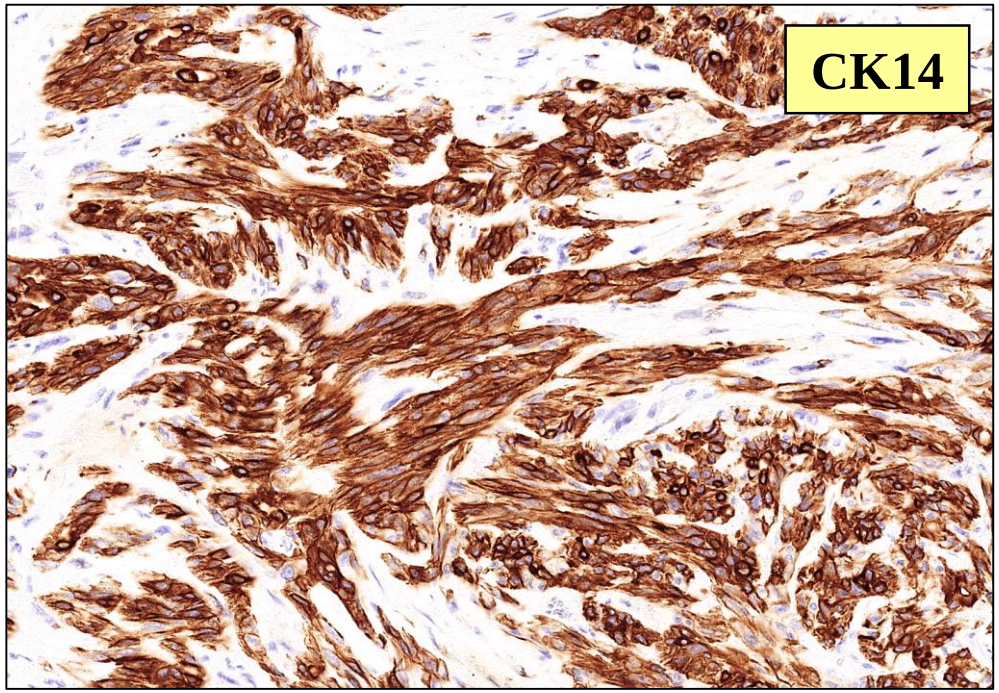
CK14

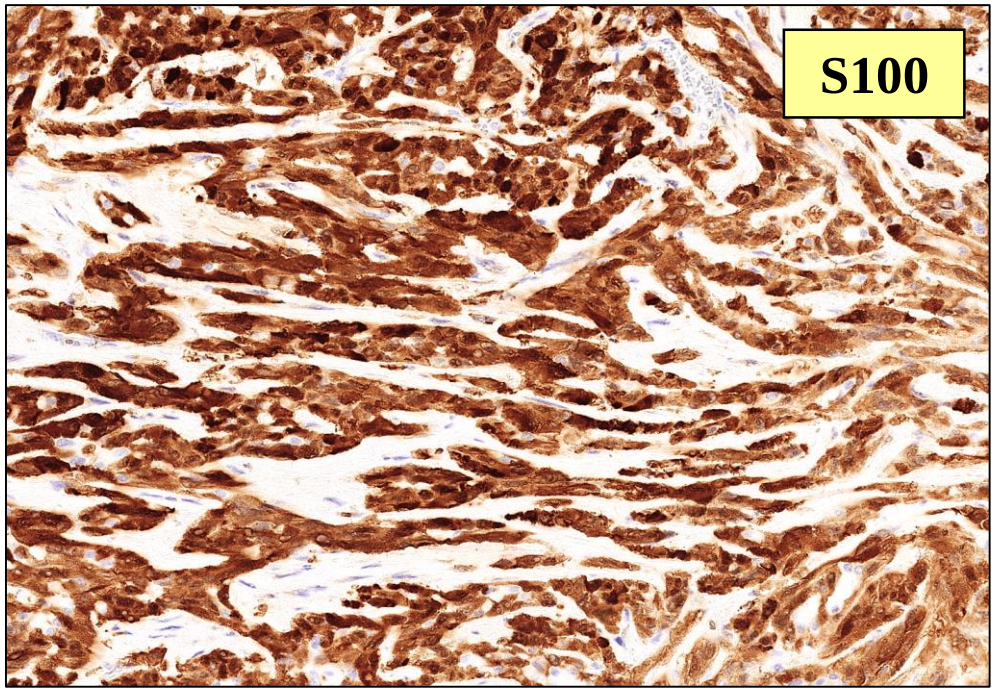
S100

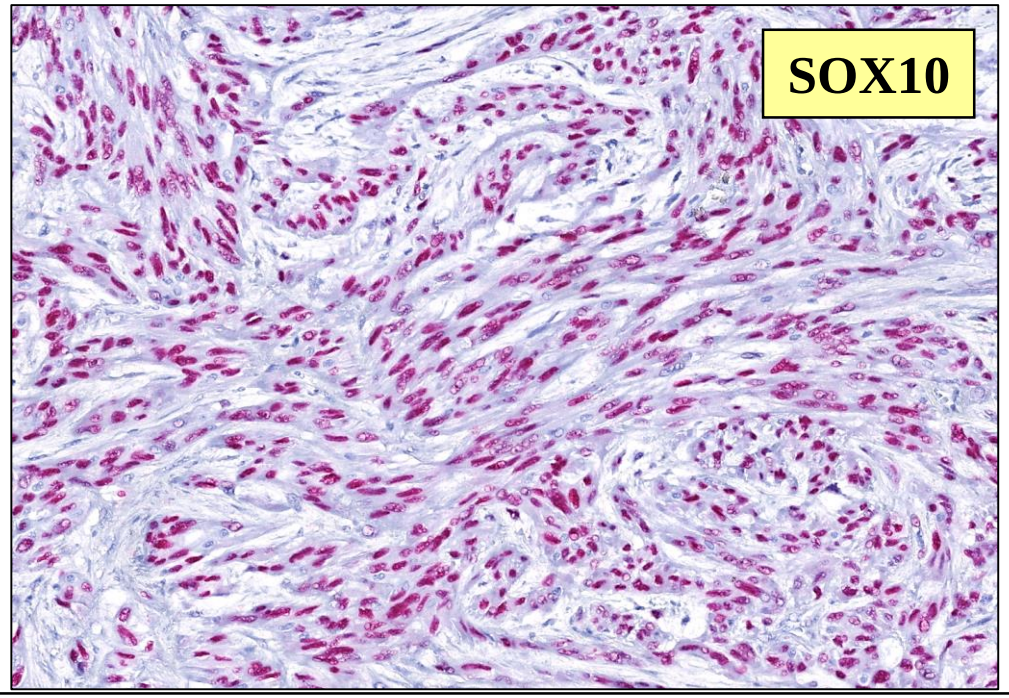
SOX10

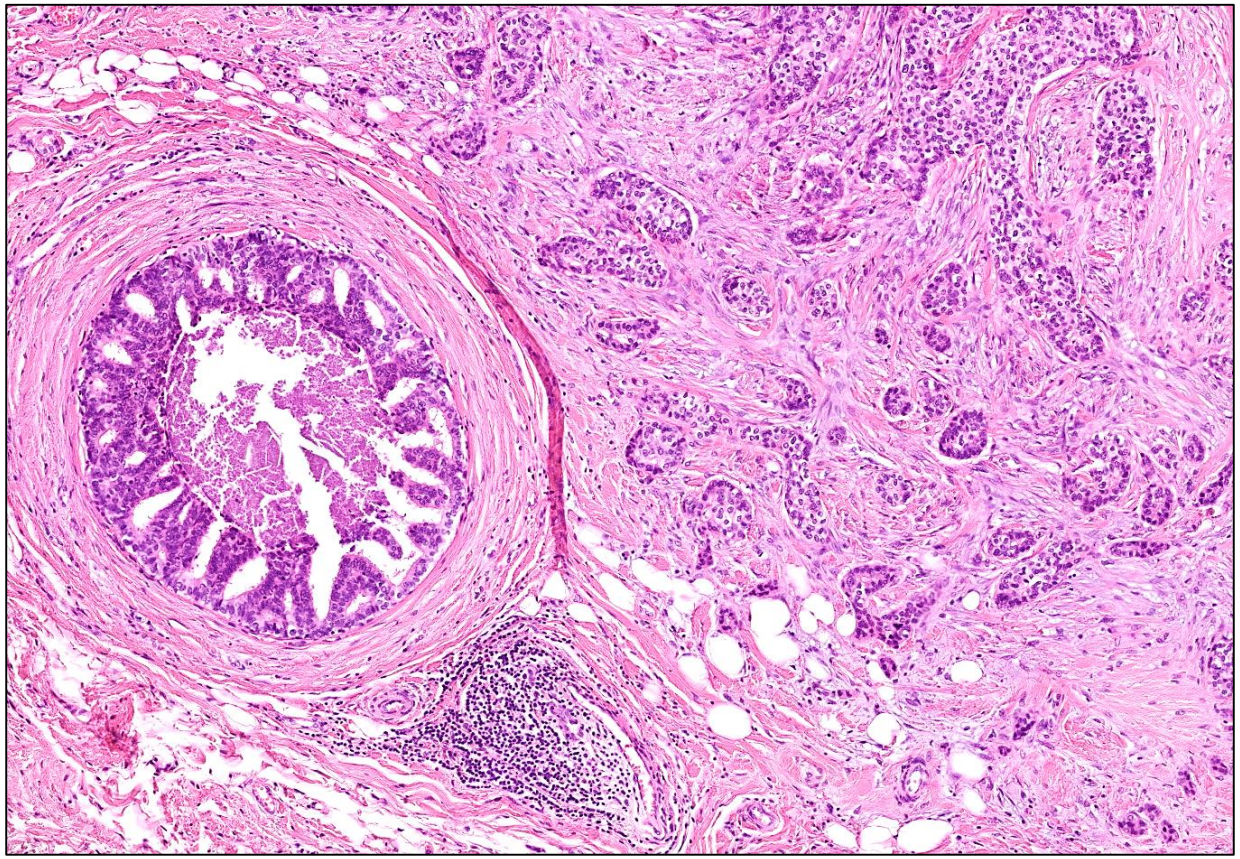

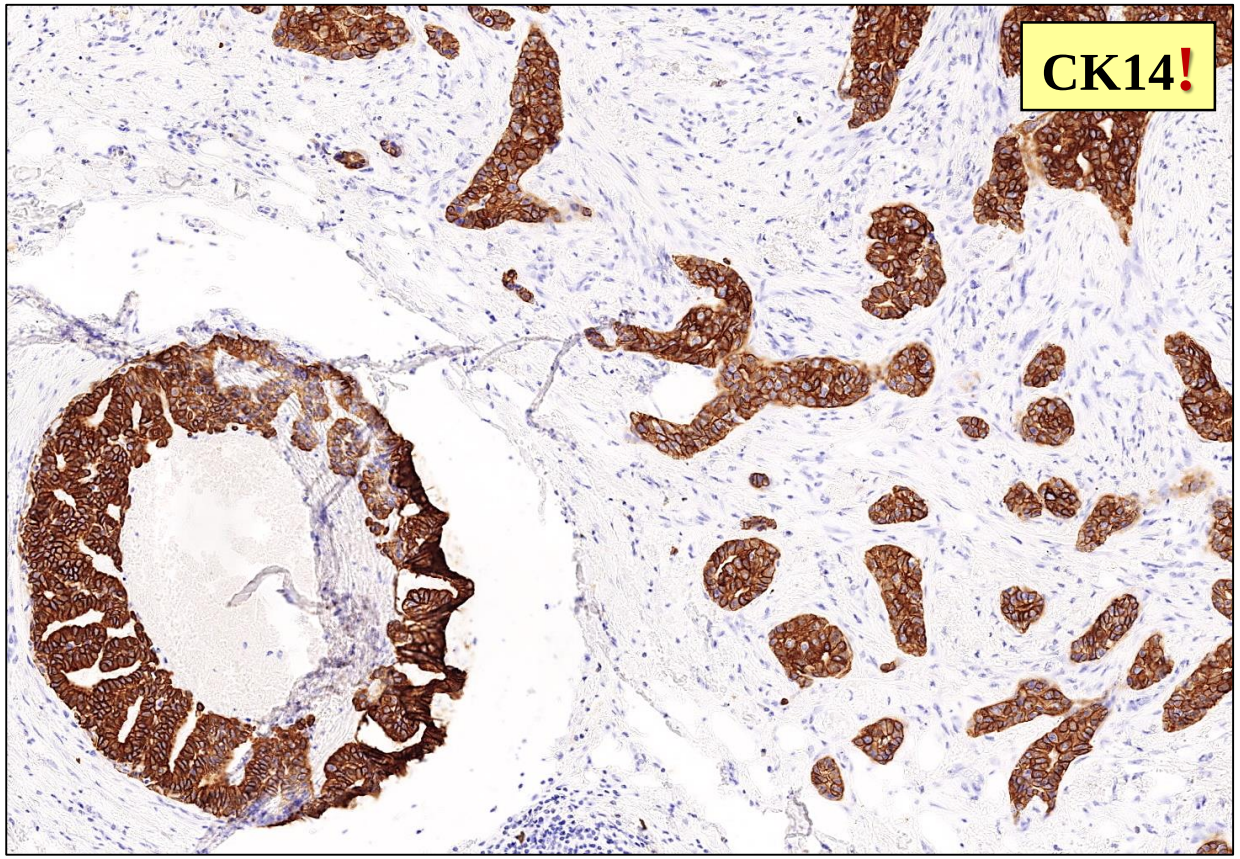
CK14!

Diagnóza



Maligní **Adenomyoepiteliom**

(vřetenobuněčný metaplastický (myoepiteliální) karcinom vznikající v AME)

Co to je ta povrchová benigní komponenta **?**

Nipple adenoma / **syringomatous adenoma** **vs.** benigní **AME…**

Vzájemný **vztah** obou komponent **?**

Kolize/koincidence **dvou lézí** **vs.** **Malignizace jediné léze…**

Molekulární genetika

„Benigní“

mutace **PIK3R1** c.227_246del.
PIK3R1 c.1700_1720del.

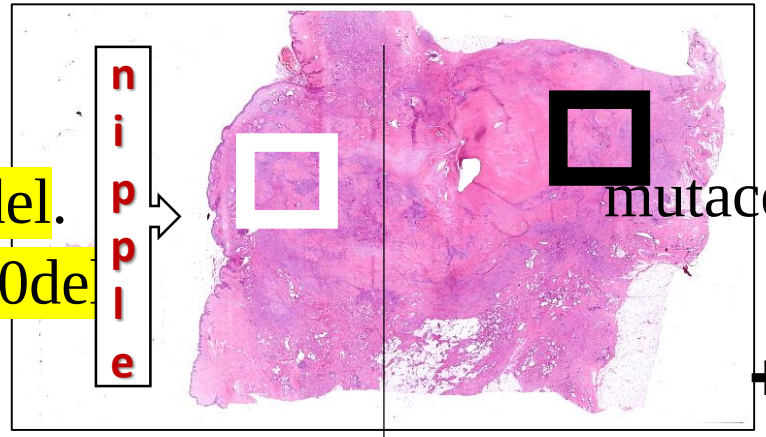

Malignní

mutace **PIK3R1** c.227_246del.
PIK3R1 c.1700_1720del.
+ **HRAS** p.(Gln61Leu)

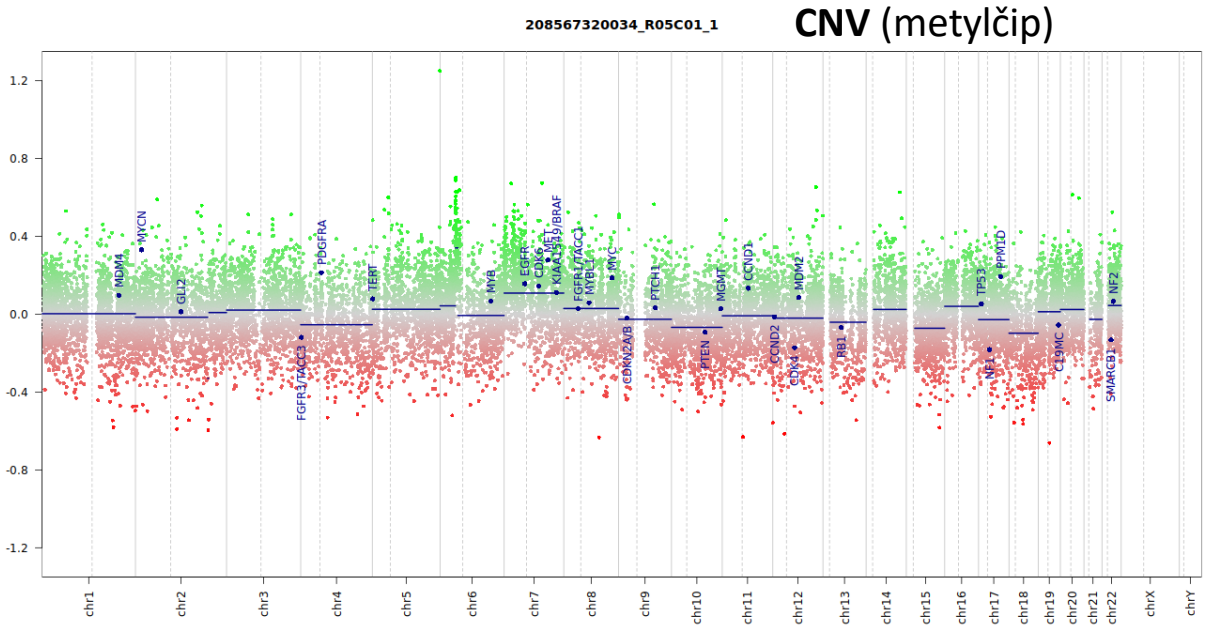

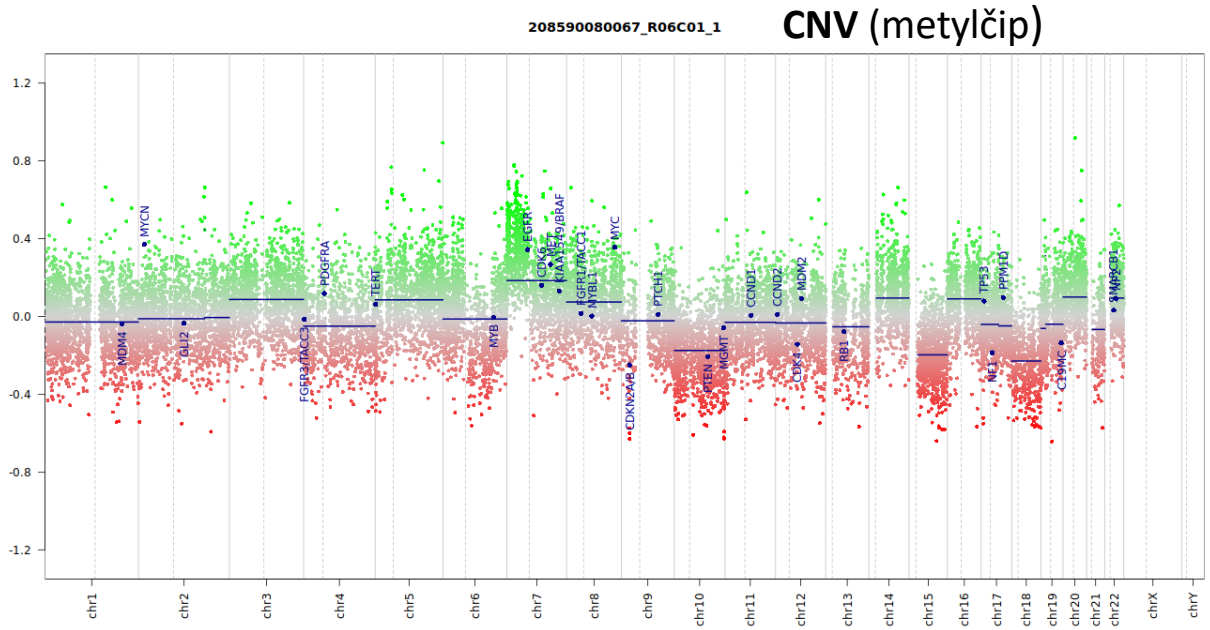

Chr. +3, +5, +7, -9p, -10, +14, -15, +16, -18, +20, +22.



Adenomyoepiteliom prsu

(AME) (Breast, WHO 2019)

Organoidně uspořádaná bifázická léze tvořená vnitřní luminální a periferní myoepiteliální složkou; zastoupení obou složek je variabilní.

Biologie nejistá; možný vznik jednoznačného CA z obou komponent (izolovaně, vzácně **i společně**)

ICD-O code: 8983/**0** Adenomyoepiteliom
8982/**3** **Maligní** adenomyoepiteliom



Epiteliální-myoepiteliální karcinom (EMECa)

(H&N, WHO 2022)

Totožná léze slinných žláz

původně nazývána jako adenomyoepiteliom resp. světlobuněčný adenom …

Nyní považovány za LG malignitu (mts < 5%)

ICD-O code: 8562/**3** Epi-myoepiteliální **karcinom**

< 70% maligně se chovajících tumorů má mutaci genu **HRAS**

Adenomyoepiteliom prsu

Kde je hranice mezi maligním a benigním AME ?

Lze určit, která komponenta AME malignizuje ?

Znamená mts benigního AME jasnou malignitu ?

Proč **identická** léze extramamárně je karcinom ?

Je AME mamární analogon salivárního EMECa ?

Chovají se všechny EMECa maligně ?

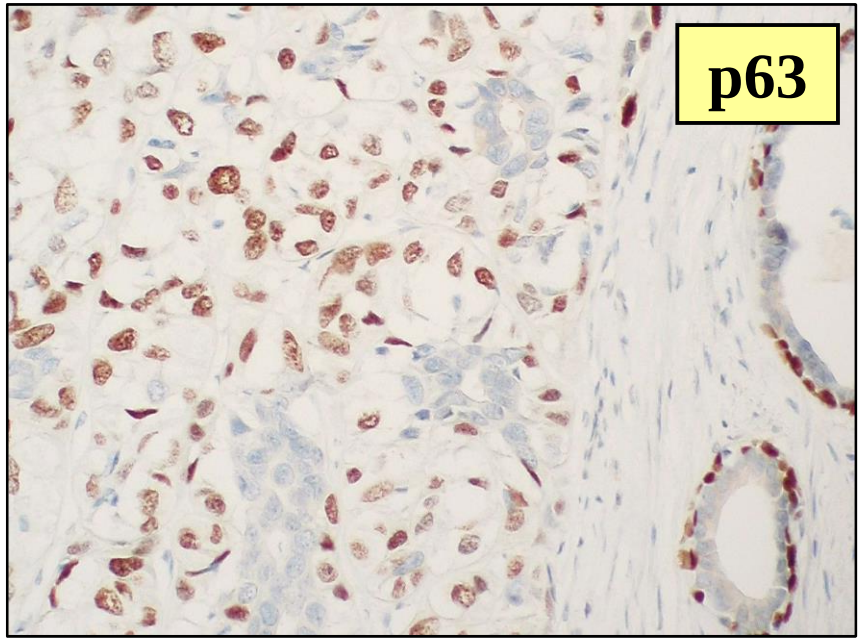

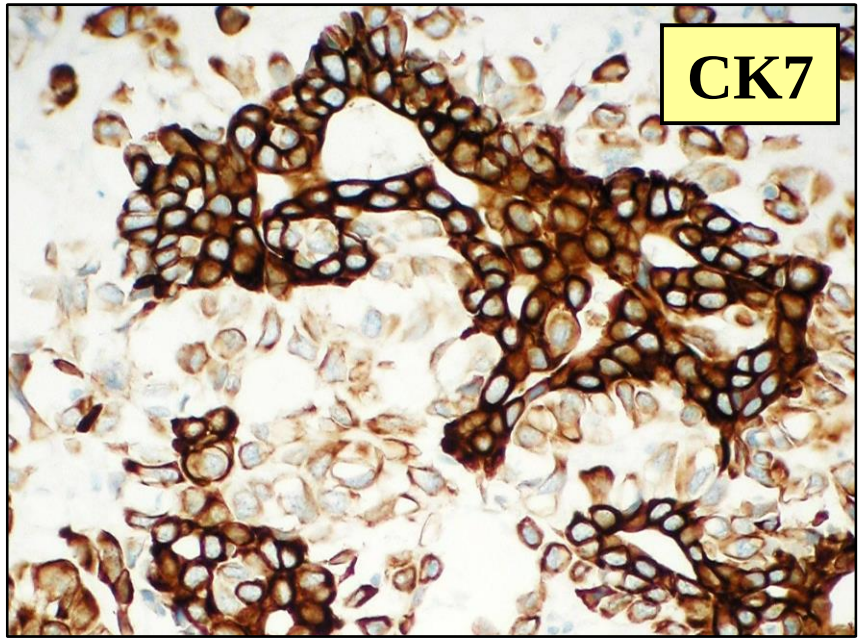

Virchows Arch (1998) 433:285–287 © Springer-Verlag 1998

LETTERS TO THE EDITOR

G. Seifert

Are adenomyoepithelioma of the breast and epithelial-myoepithelial carcinoma of the salivary glands identical tumours?

…adenomyoepiteliom prsu je identická léze jako epimyoepiteliální CA slinných žláz, bronchu či kůže…

… identická terminologie by se měla používat pro tumory s identickou morfologií, bez ohledu na jejich různou orgánovou lokalizaci …

…existuje benigní AME (**epimyoepiteliální adenom**) **i maligní** AME (**epimyoepiteliální CA**) **mléčné žlázy**





Amedeo Modigliani

Děkuji za pozornost