Virtuálny sklíčkový seminár

Peter Szépe

Lymfoproliferatívne ochorenia CNS

8. Východoslovenský bioptický seminár, 27.-28.apríl 2018, Košice

Prípad č. 1

- žena, 38 rokov
- Tu cerebri lobi TPO l.dx.
- konzultácia PAO UNLP, KE

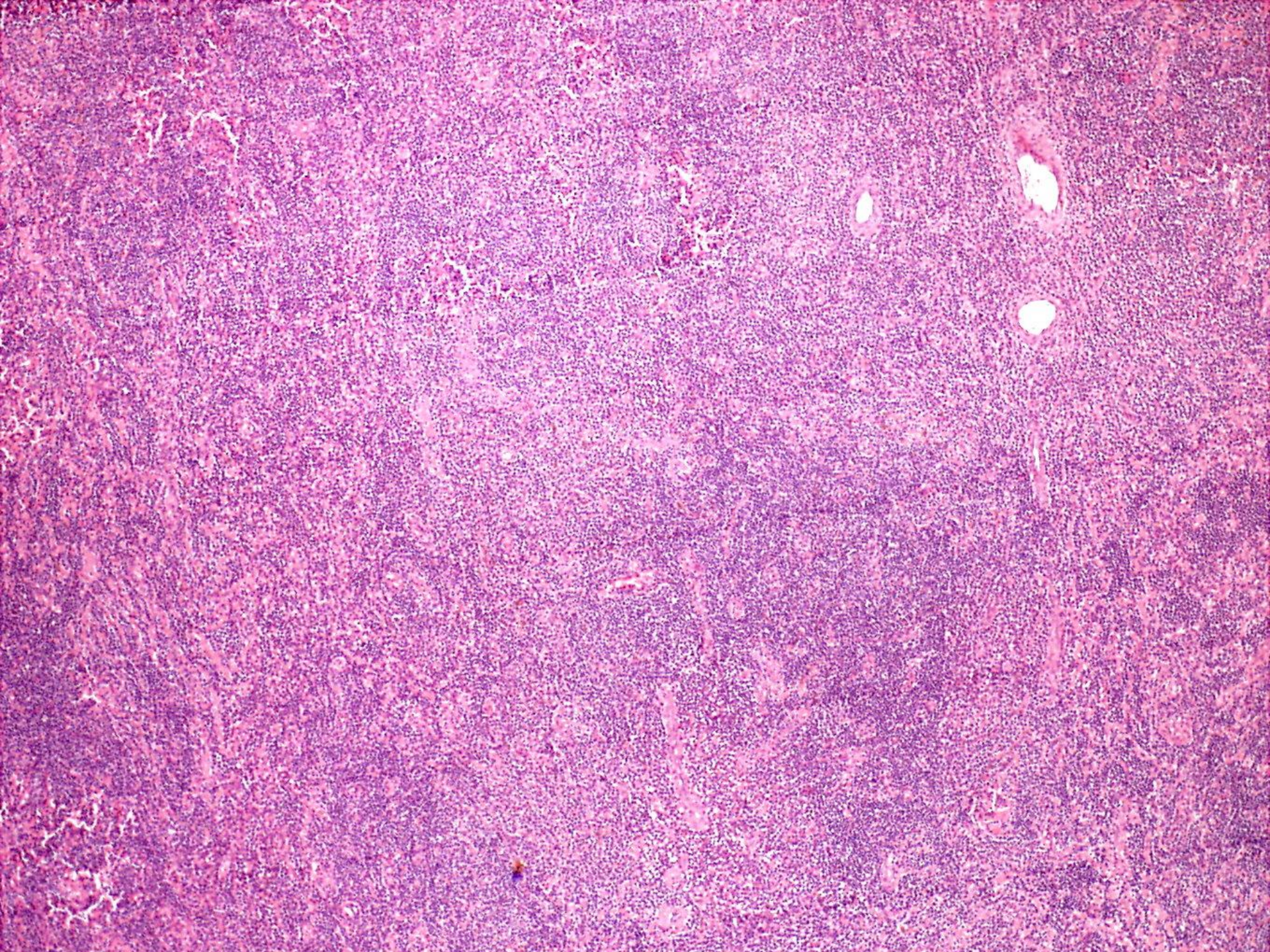

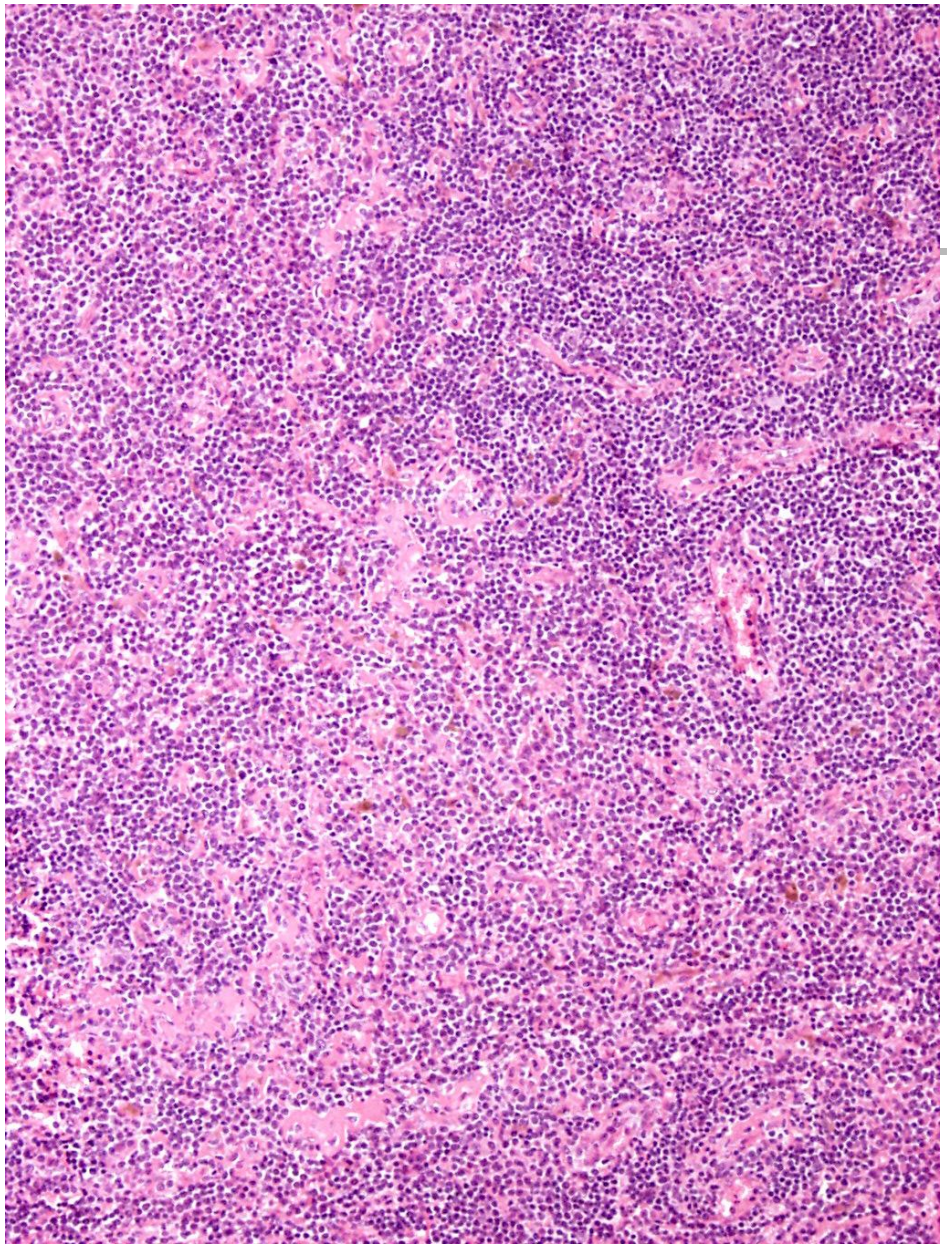

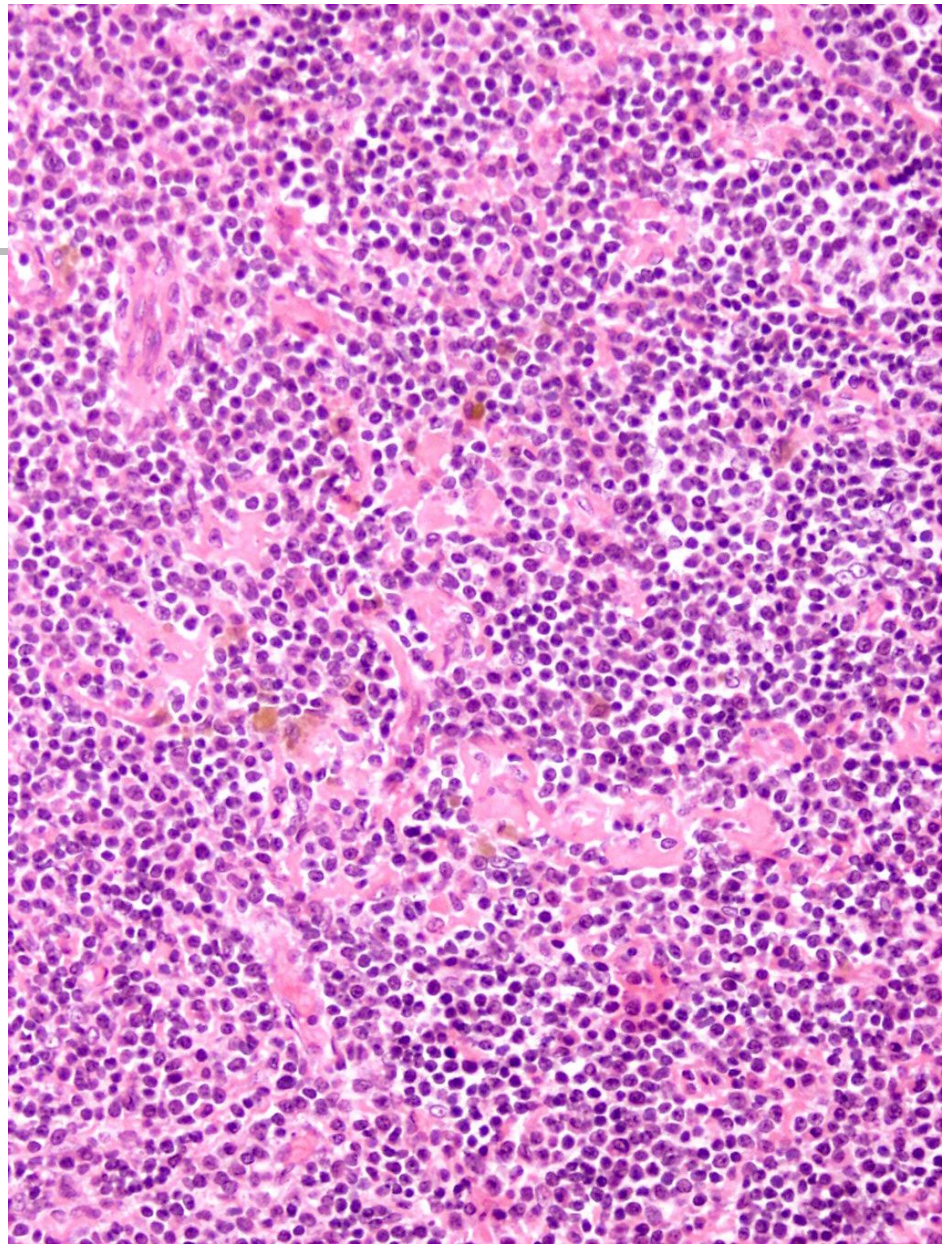

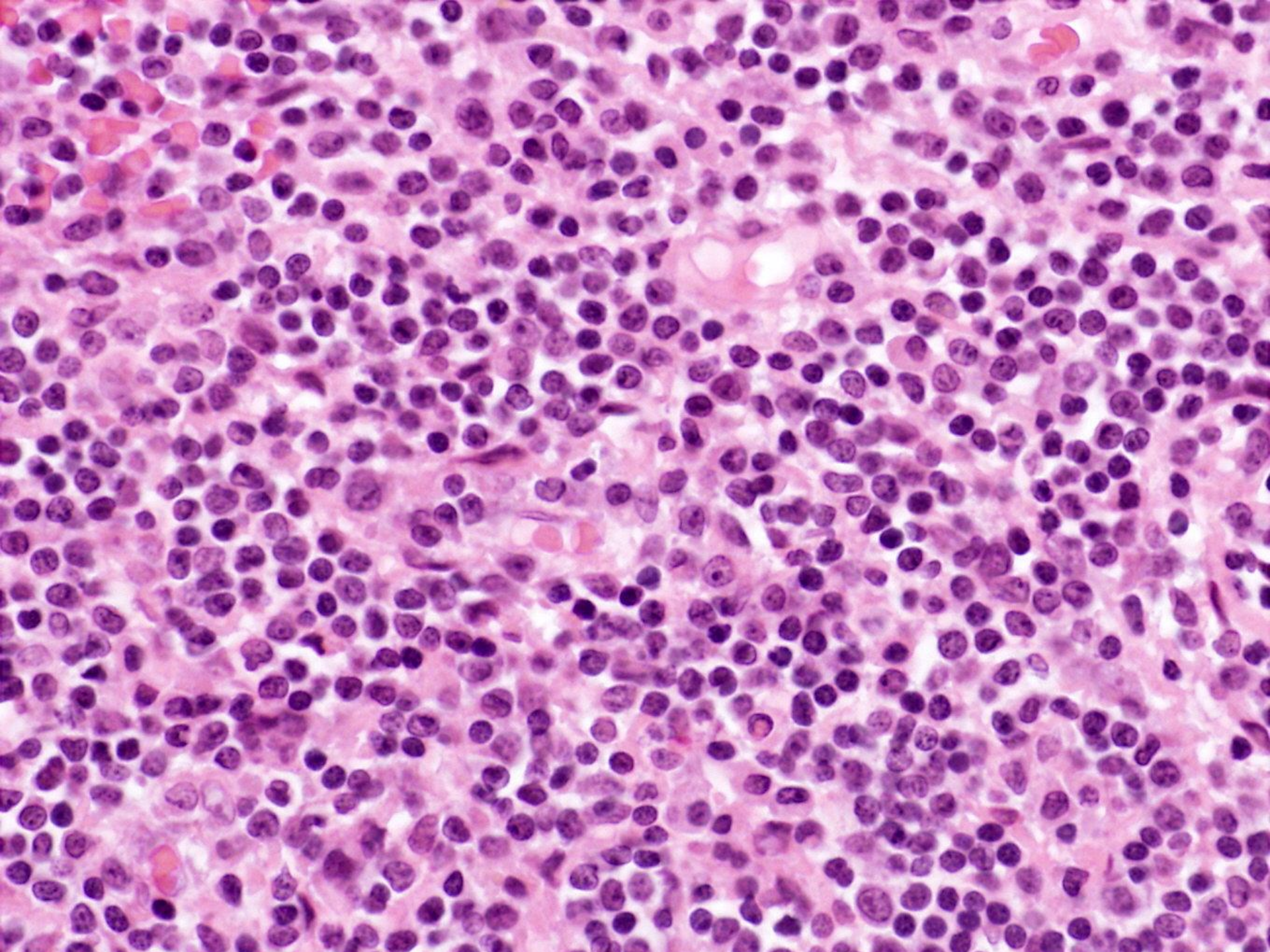

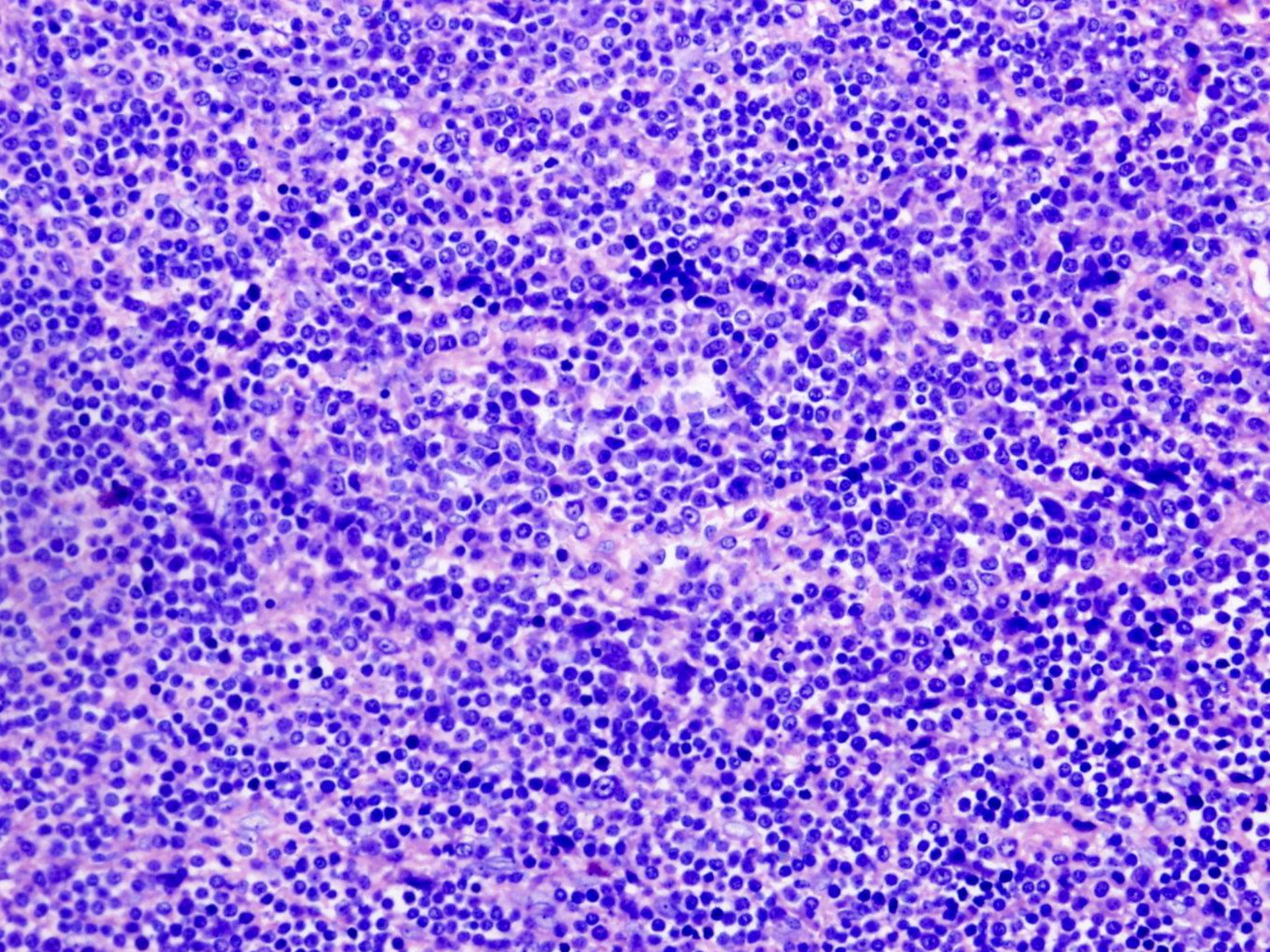

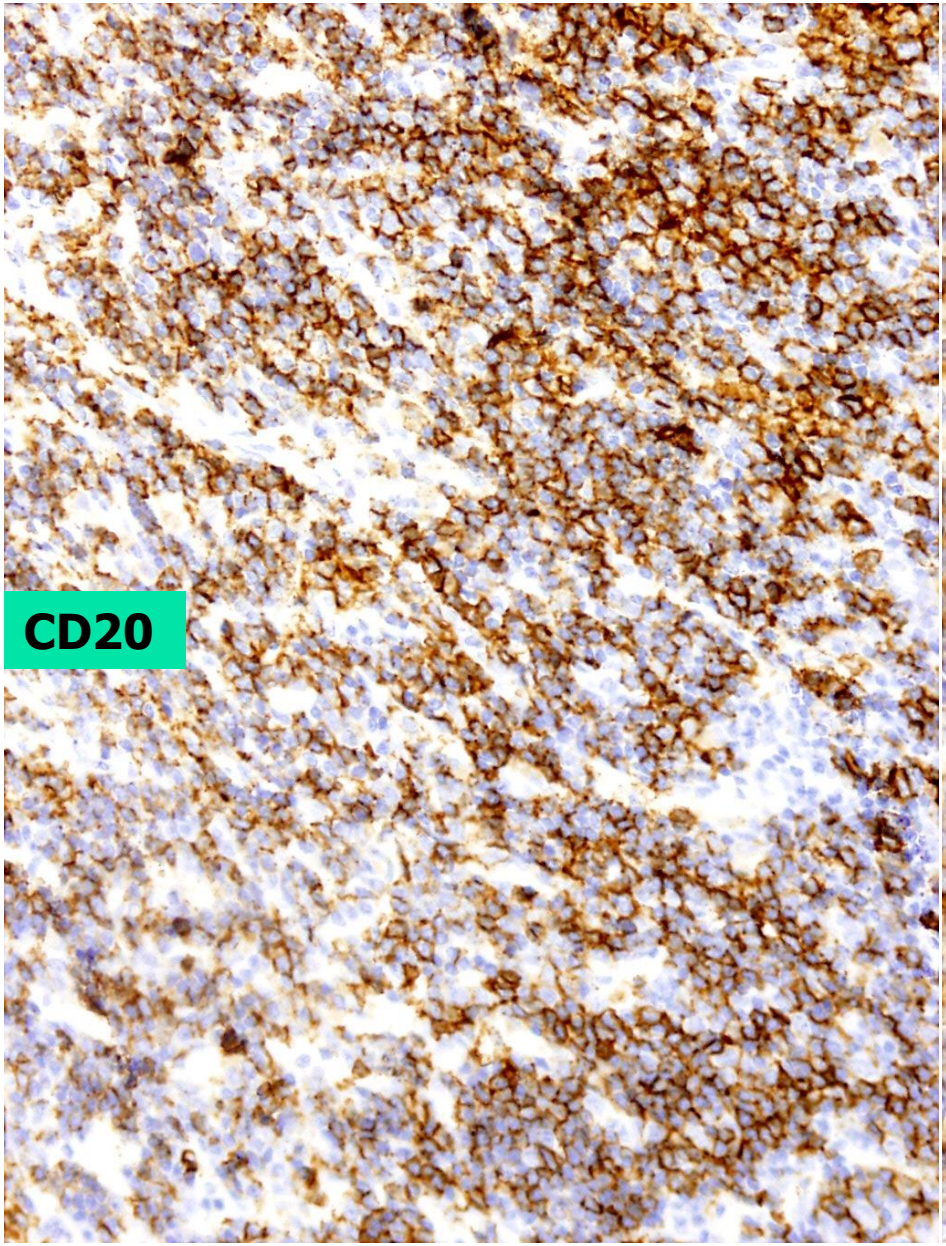
CD20

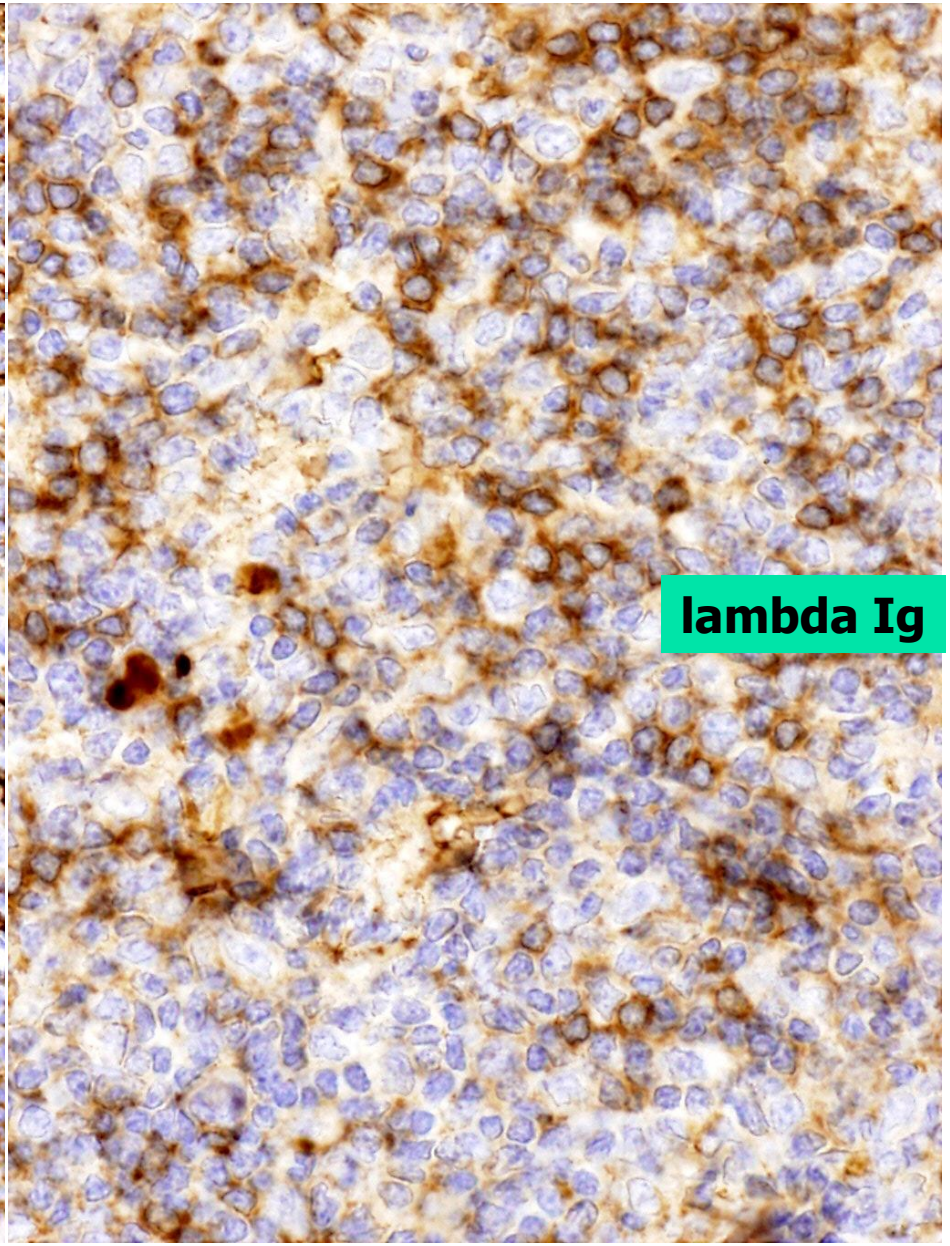
lambda Ig

Imunoprofil:

- Pozitivita:

  CD20, CD79a, bcl-2, monotypický s-Ig typu lambda ľahkého reťazca

- Negativita:

  CD3, CD5, CD10, CD23 a cyklín D1

Záver:

Malobunkový B-NHL v extranodálnej lokalizácii, ktorý je aj vzhľadom k absencii bližších klinicko-hematologických údajov (KO ?, dif. KO?, lymfadenomegália?, splenomegália ?) obtiažne klasifikovateľný (NOS).

Dodatok:

Vzhľadom k potvrdenej, pomerne rozsiahlej, infiltrácii KD (MUDr. Poliaková - Klinická patológia Prešov, ďakujeme) ide skôr o prejav systémového B-NHL, než o primárny B-NHL v oblasti CNS (najskôr z buniek marginálnej zóny). Preto odporúčame kompletné hematologické vyšetrenie so zabezpečením FC analýzy na vylúčenie, resp. potvrdenie možného leukemického procesu (PLL?) a uvítame spätný oznam o tejto korelácii (čakáme 8 rokov...)

Prípad č. 2

- muž, 49 rokov
- pacient s dg. TU cerebri l.dx, susp. lymfóm, indikovaná histologizácia
- konzultácia z Cytopathos, BA

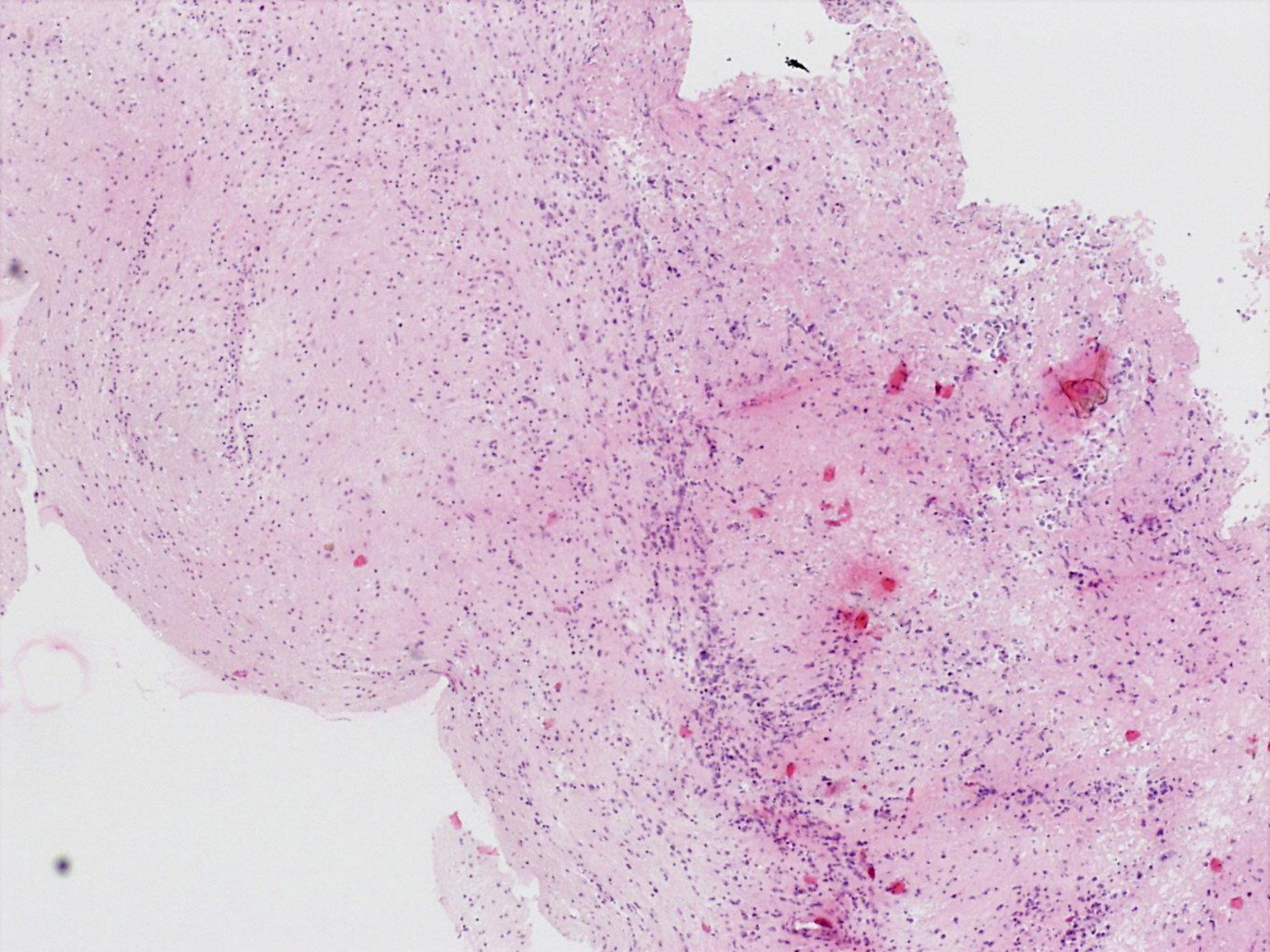

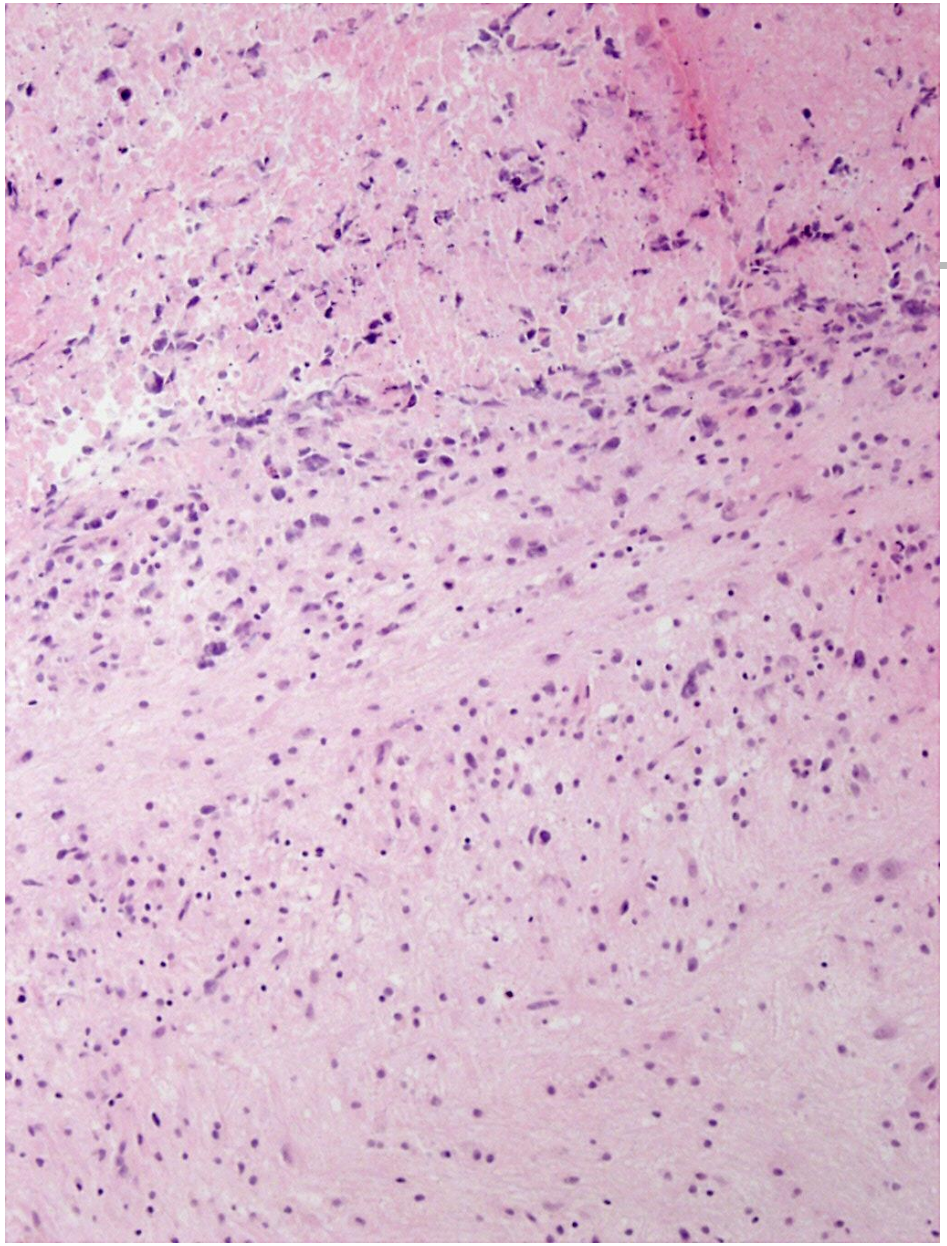

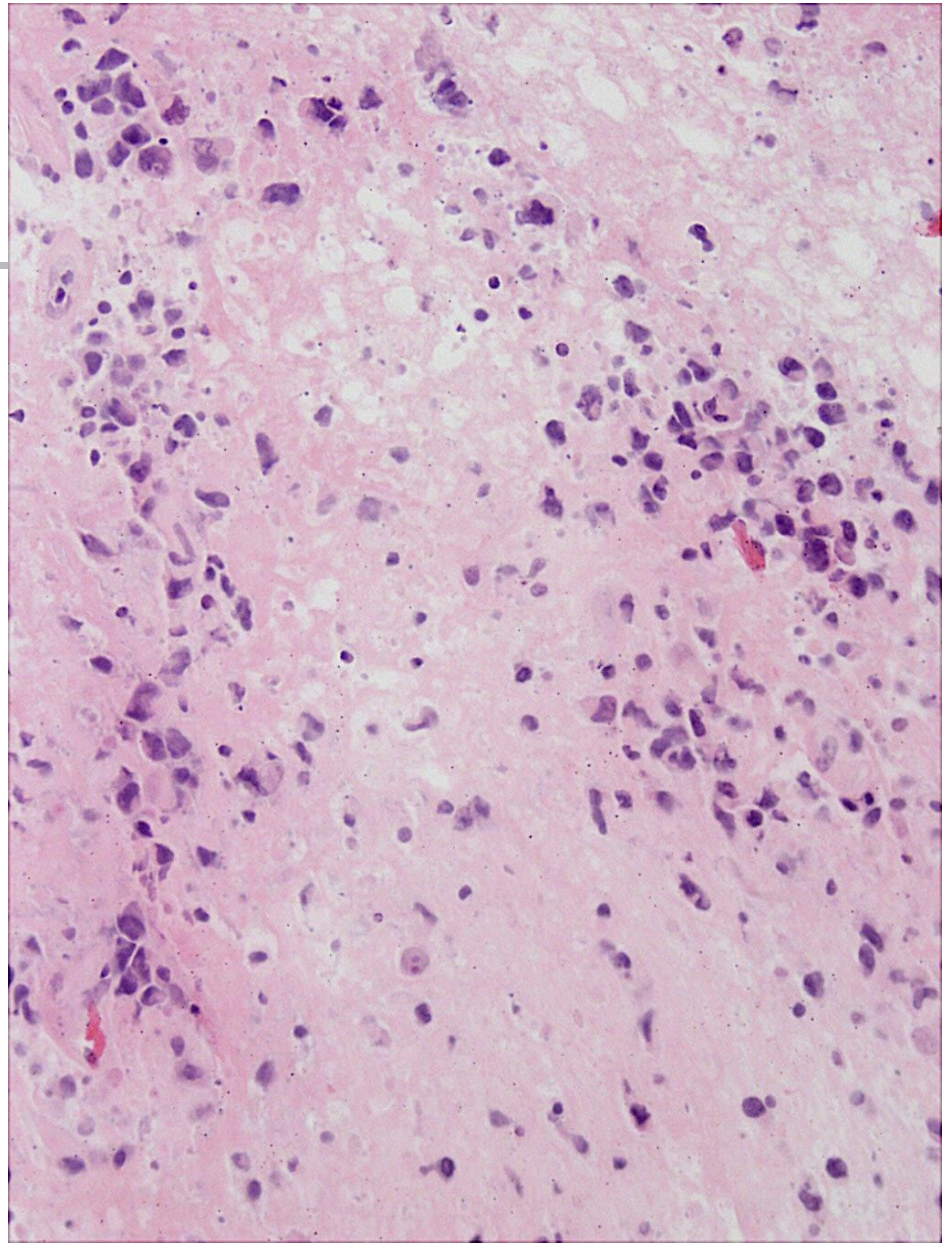

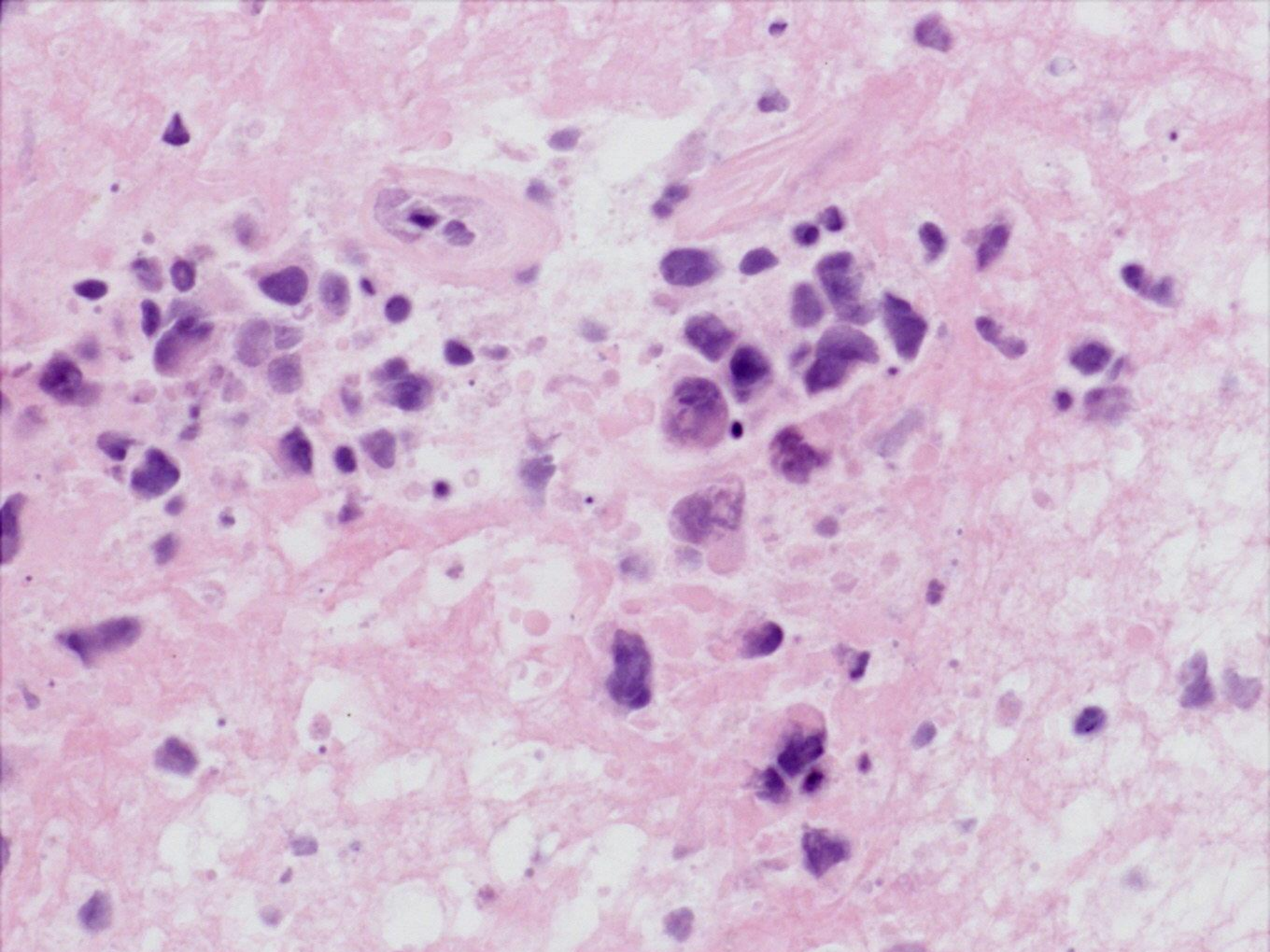

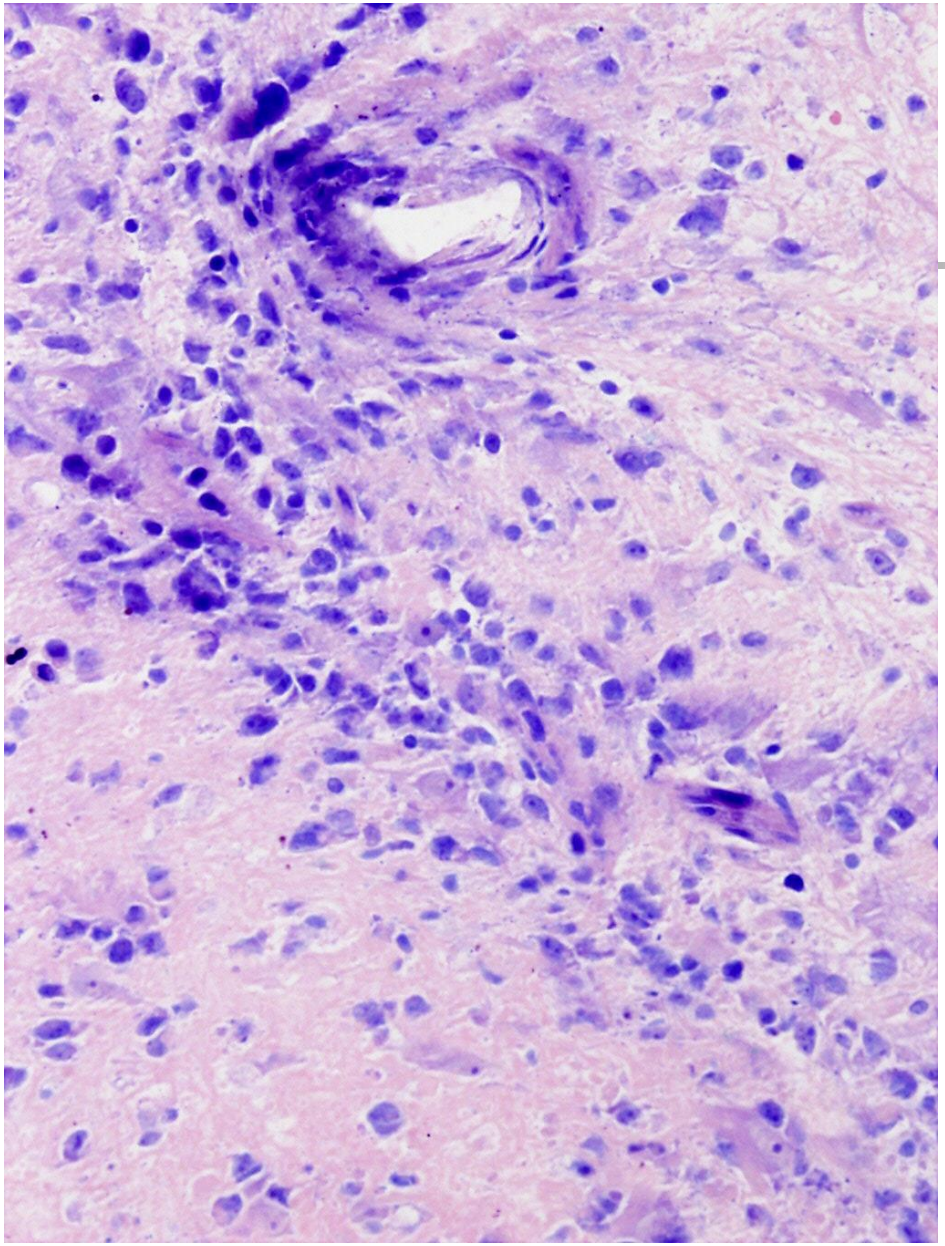

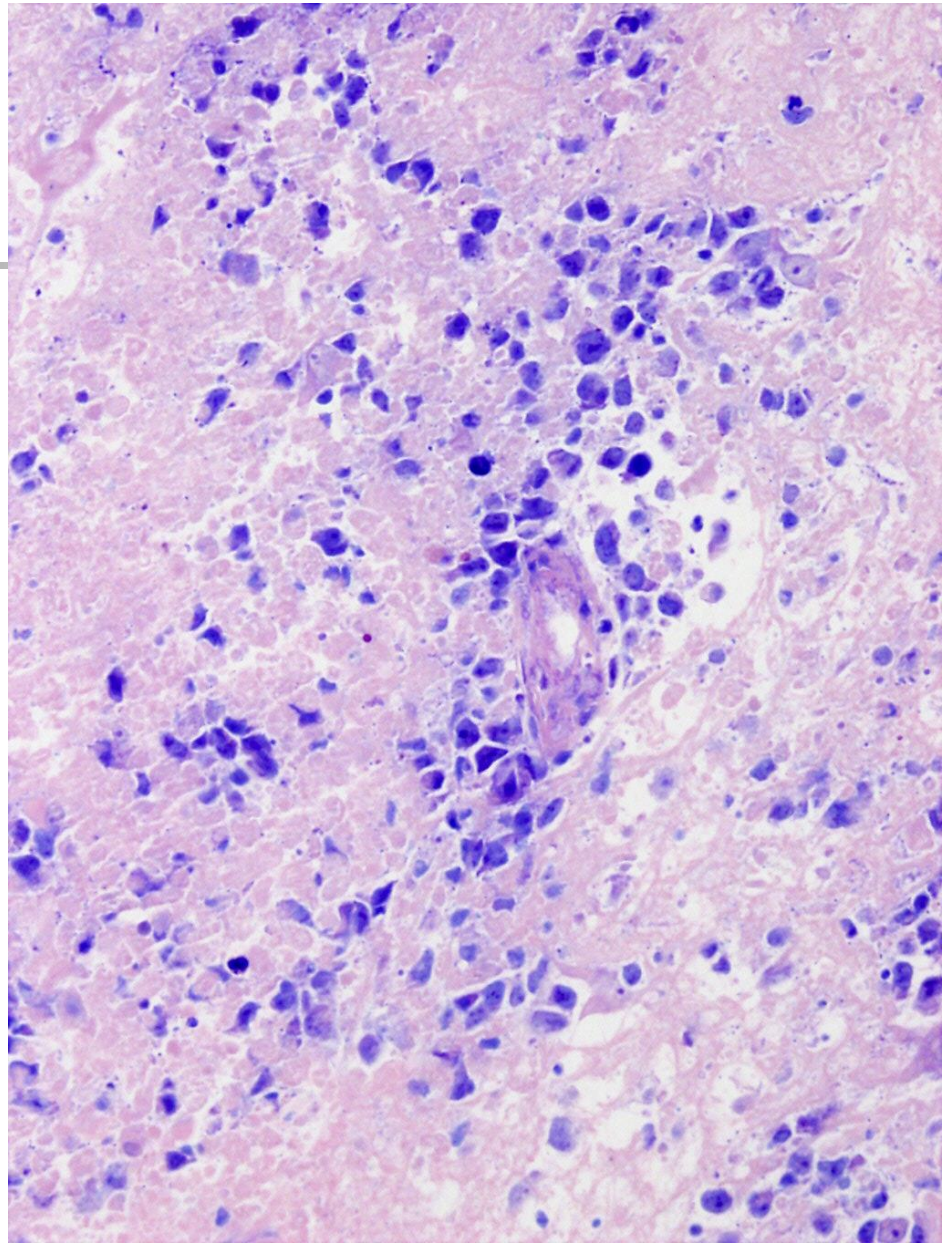

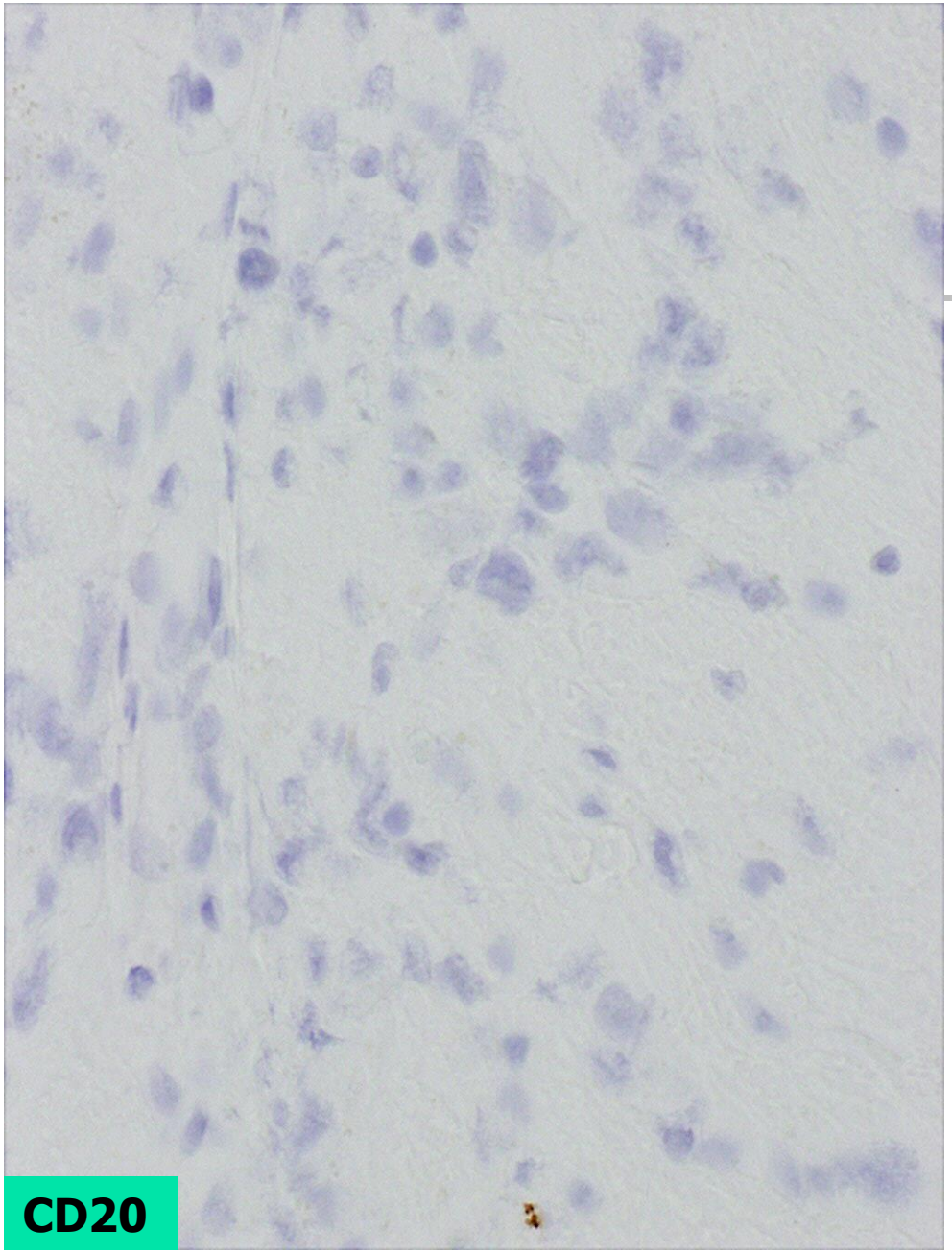
CD20

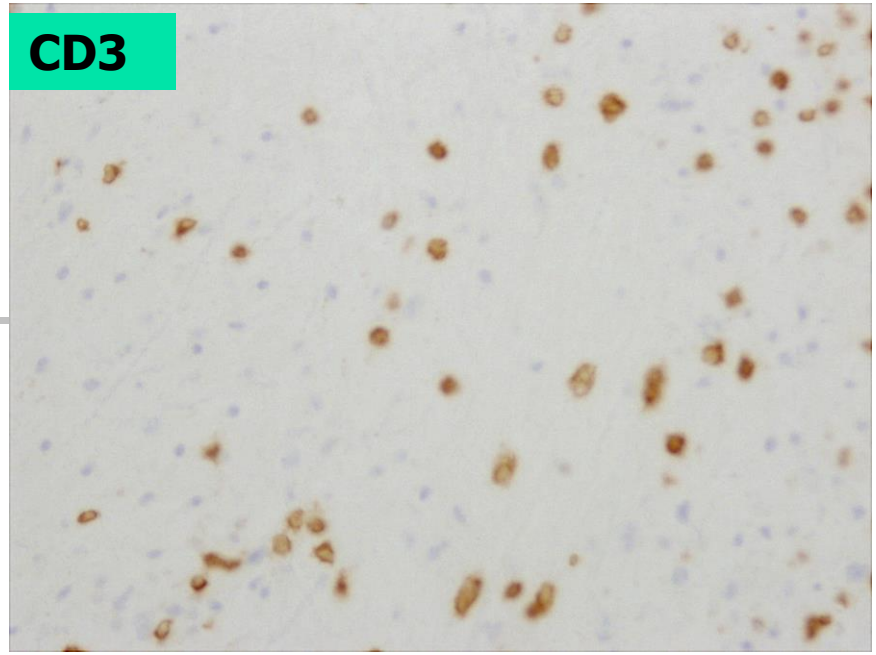
CD3

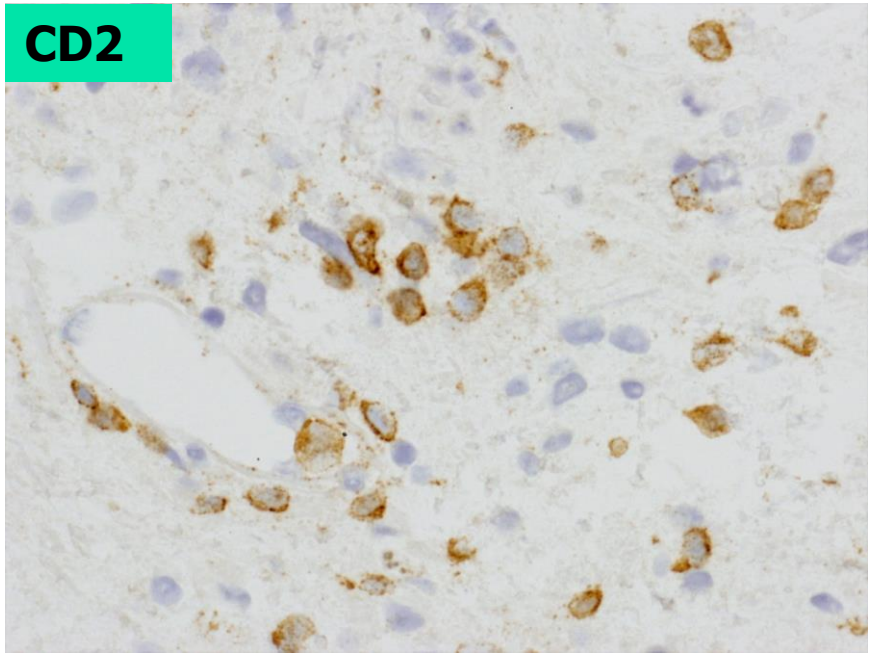
CD2

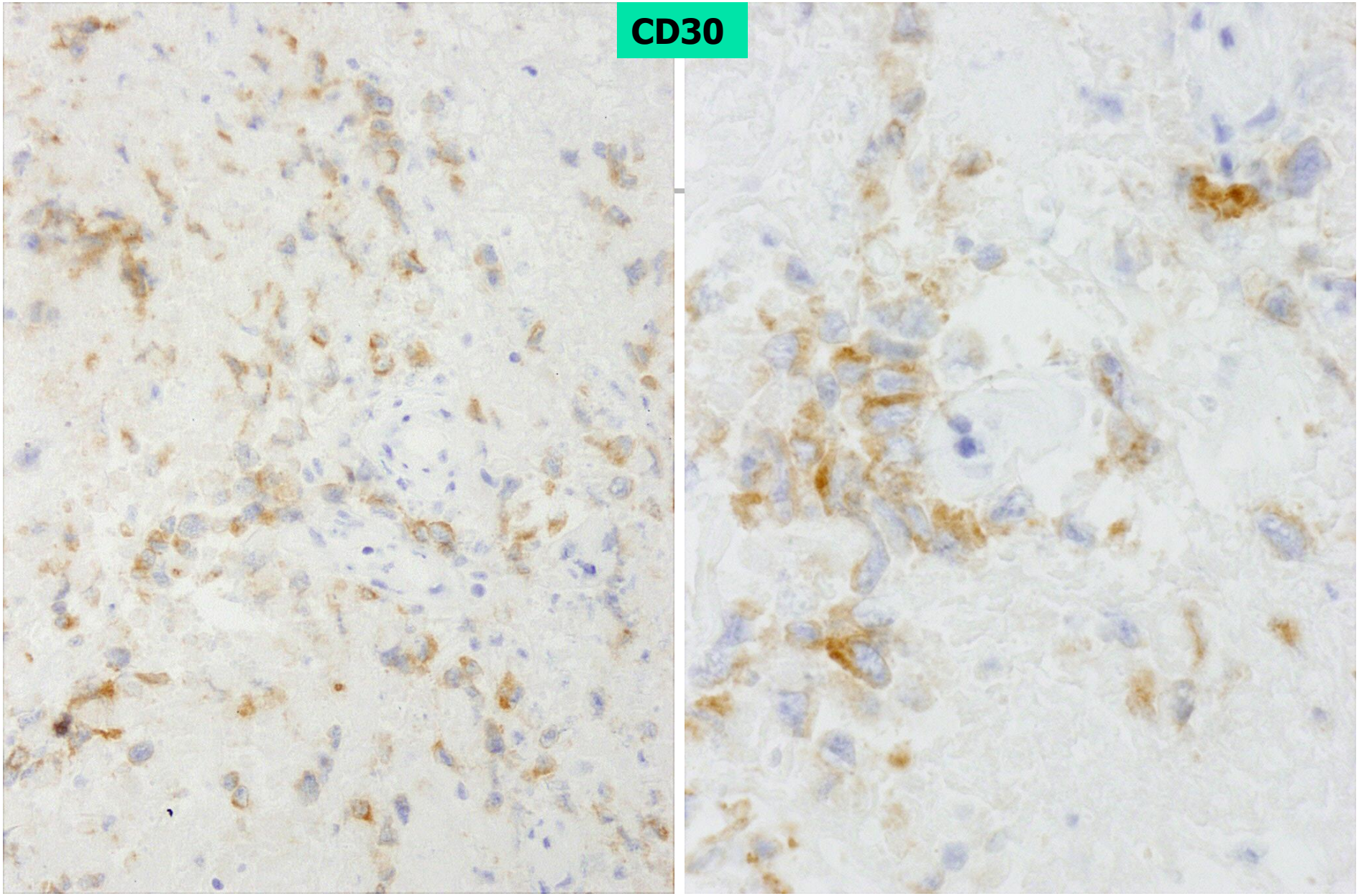
CD30

Imunoprofil:

- Pozitivita: sčasti CD2 a CD3, CD30 (CD45)
- Negativita: CD20, PAX-5

Z á v e r :

Infiltrácia tkaniva mozgu CD30+ PTCL typu ALCL, ALK1 negatívny.

PRIMÁRNY ?

Údaje k 1. biopsii
(PAO TT pred 4 rokmi)

- muž, 45 rokov, tumor ilea
- algodyspeptické potiaže a podozrenie na Ca pľúc, možná MTS, realizovaná VATS – nie je výsledkok
- prijatý na laparotómiu pre nepriechodnosť a známky dráždenia peritonea
- pri laparotómii zistená peritonitída pri perforácii t. čreva, v oblasti ilea stenóza – možný tumor. Podobné stenózy po celom t. čreve (10x), priechodné a ponechané, jedna vytvárala sigmojejunálnu fistulu.
- odobrané aj LU a časť omenta, ktoré bolo pritiahnuté k perforácii
- **Dg.: Mnohopočetný primárny Tu tenkého čreva s hmatnými MTS v II. segmente pečene, dif. dg. Crohnova choroba**

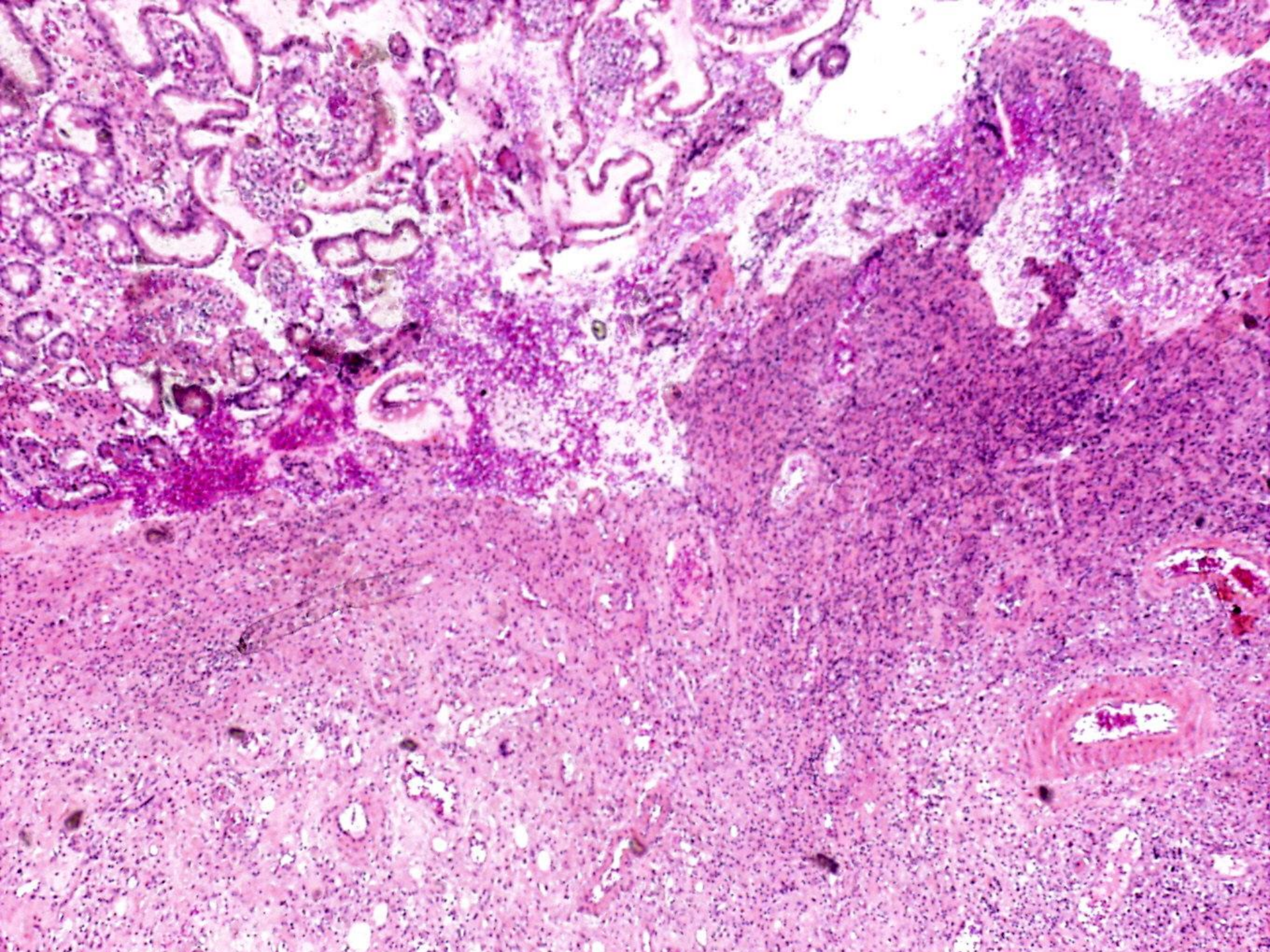

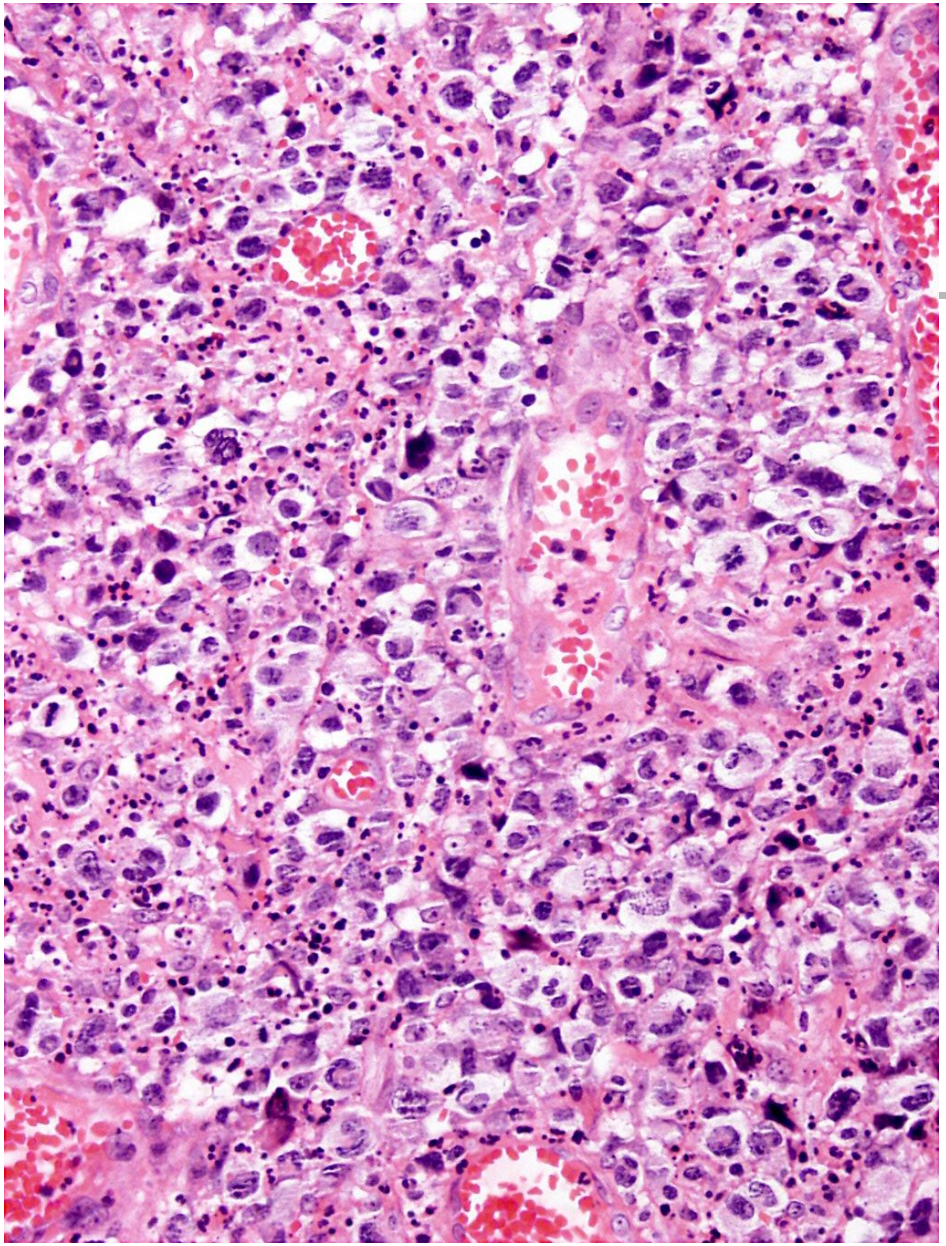

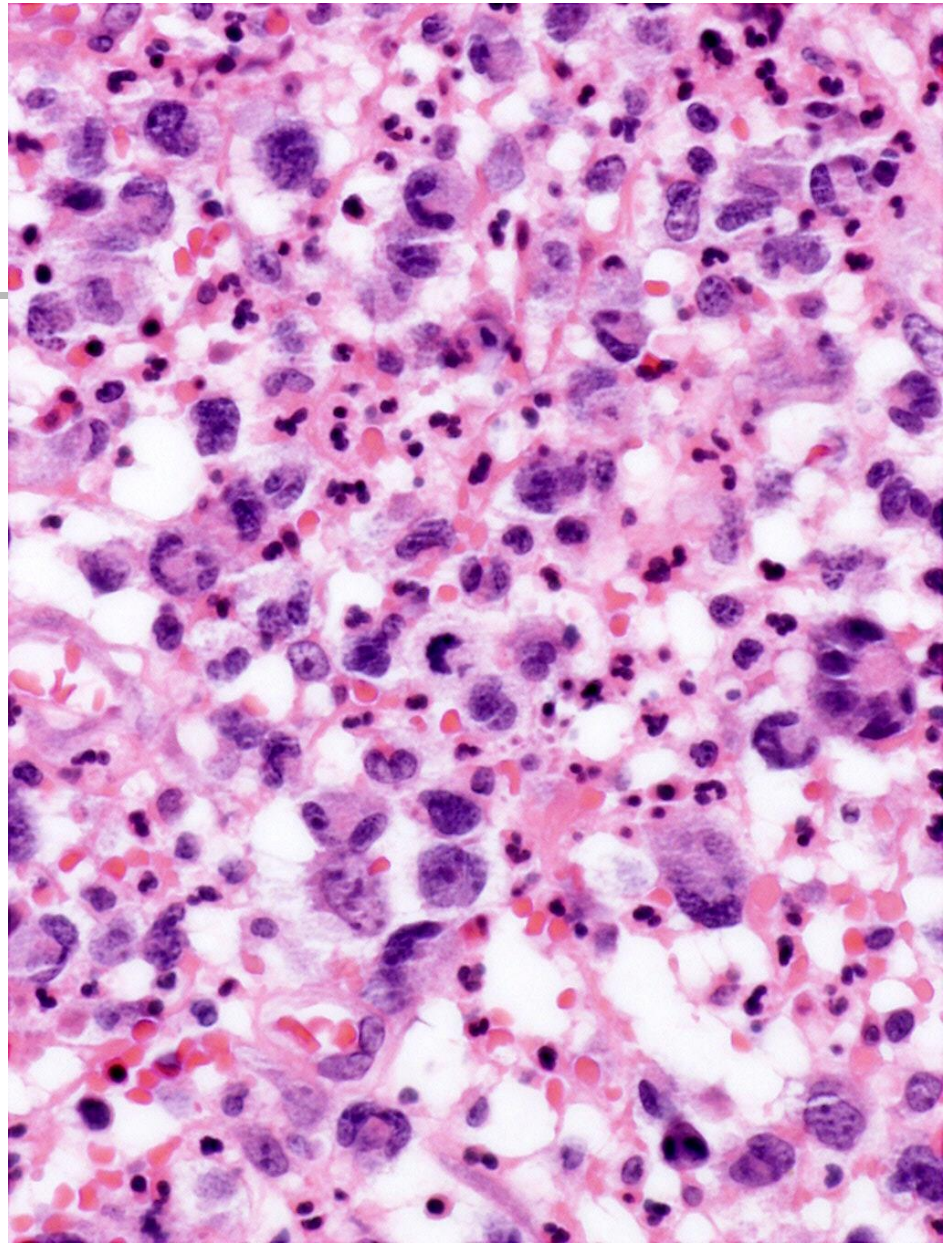

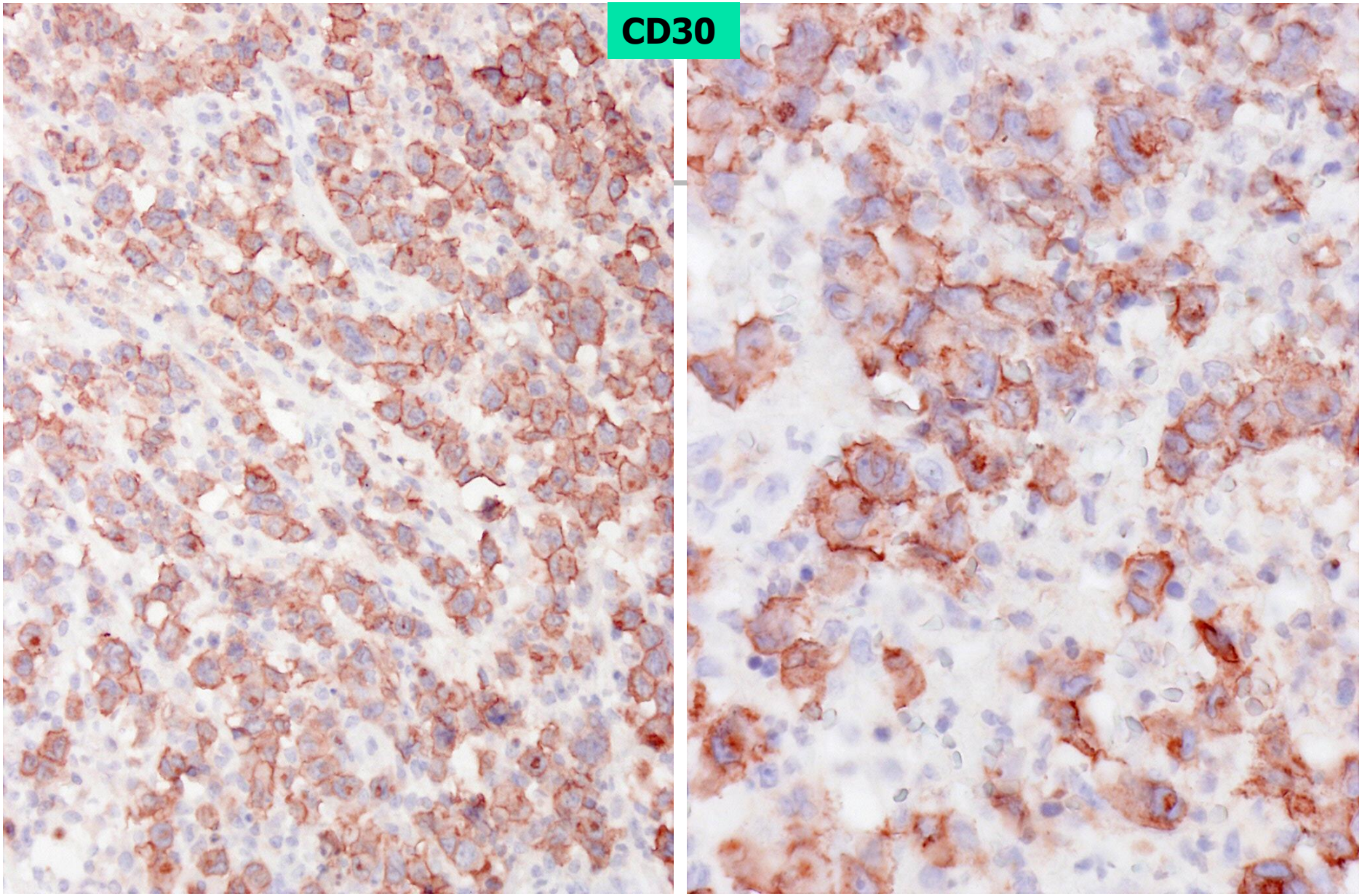
CD30

Imunoprofil:

- Pozitivita: CD3, CD30, (CD45+/-, EMA)
- Negativita: CD20, ALK1, (CK, CEA, chromogranín A)

Záver:

Veľkobunkový anaplastický T-bunkový lymfóm (ALCL) v extranodálnej lokalizácii, ktorý je ALK-1 negatívny bez infiltrácie regionálnej LU.

Dodatok

- údaj o primárnej biopsii nebol uvedený na sprievodke – sekundárny ALCL
- pacient bol liečený pred odberom tkaniva mozgu Dexametazonom (2x4 mg/ deň) bez údaja na sprievodke (dodatočne zistené)

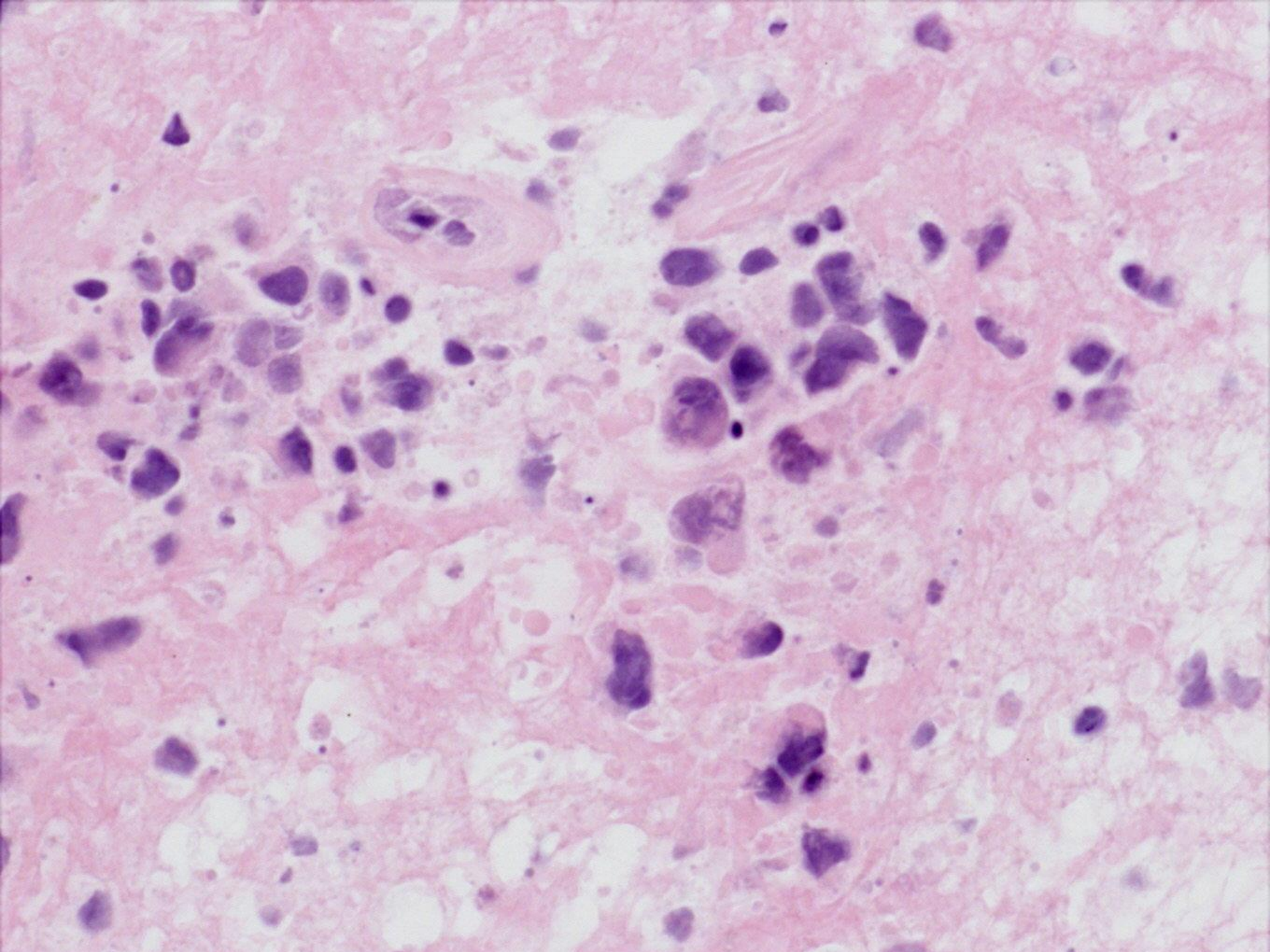

Prípad č.3

- žena, 60 rokov
- intracerebrálny tumor charakteru gliómu F.-T. l.dx.
- konzultácia PAO ZA

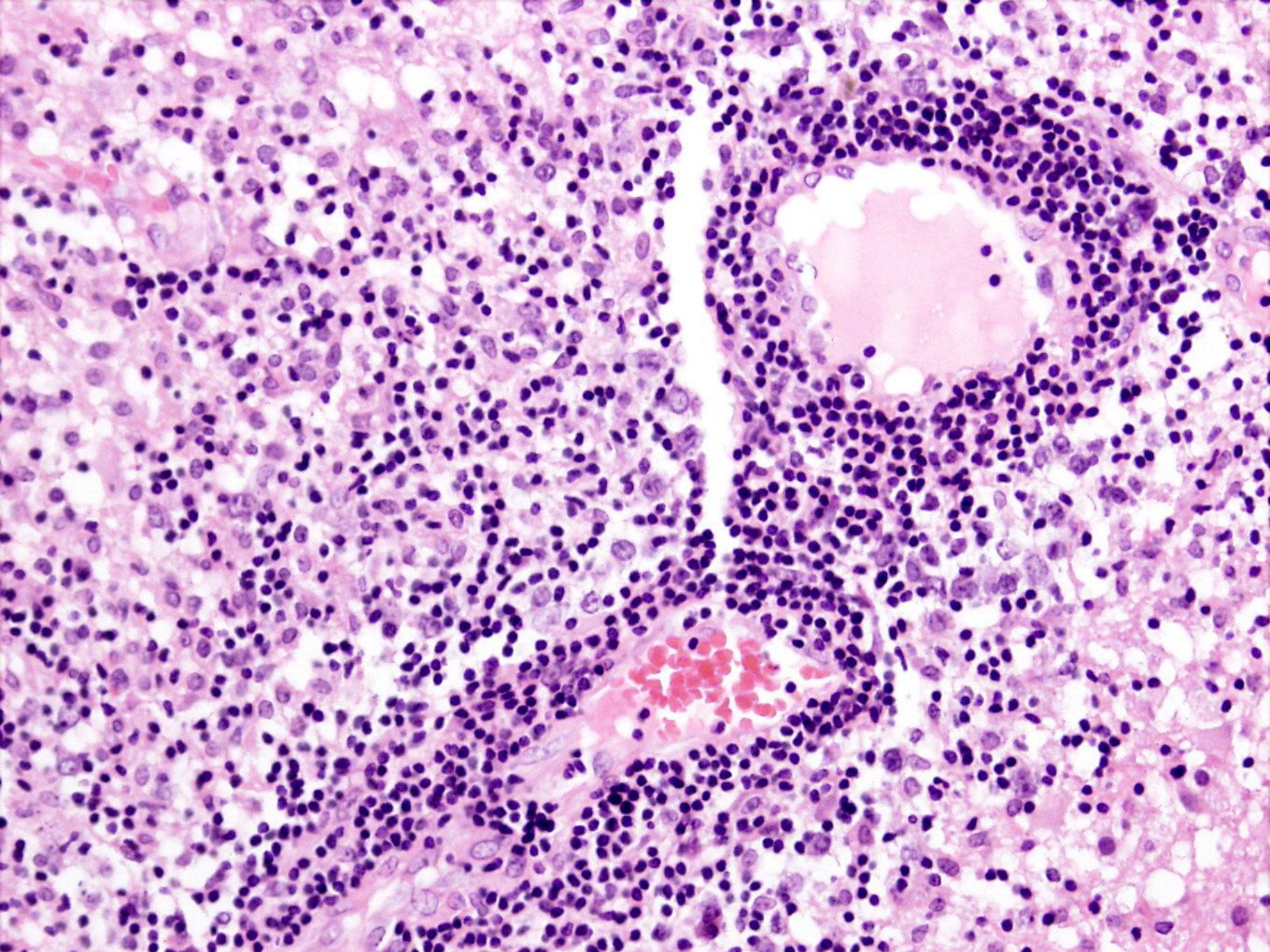

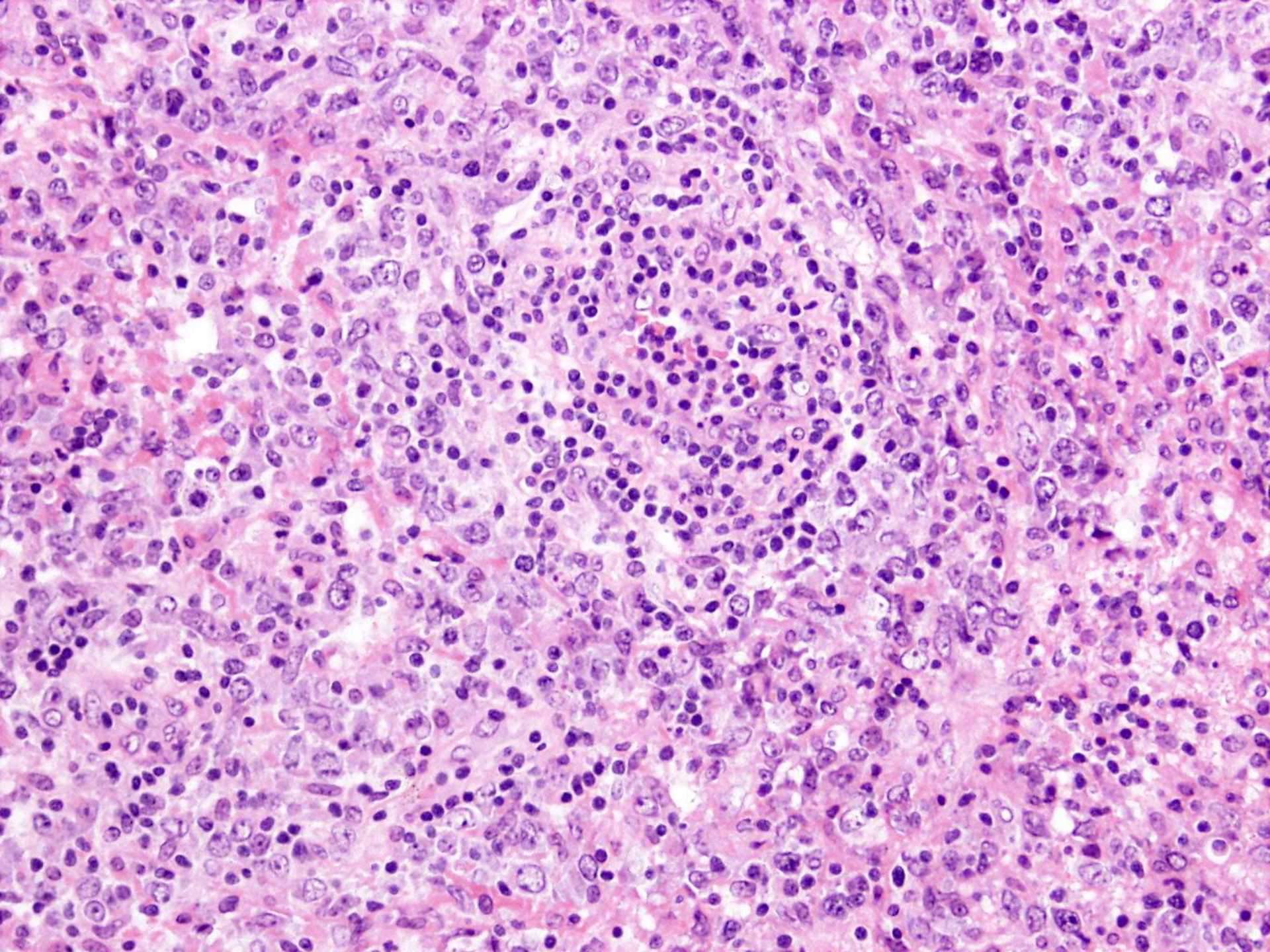

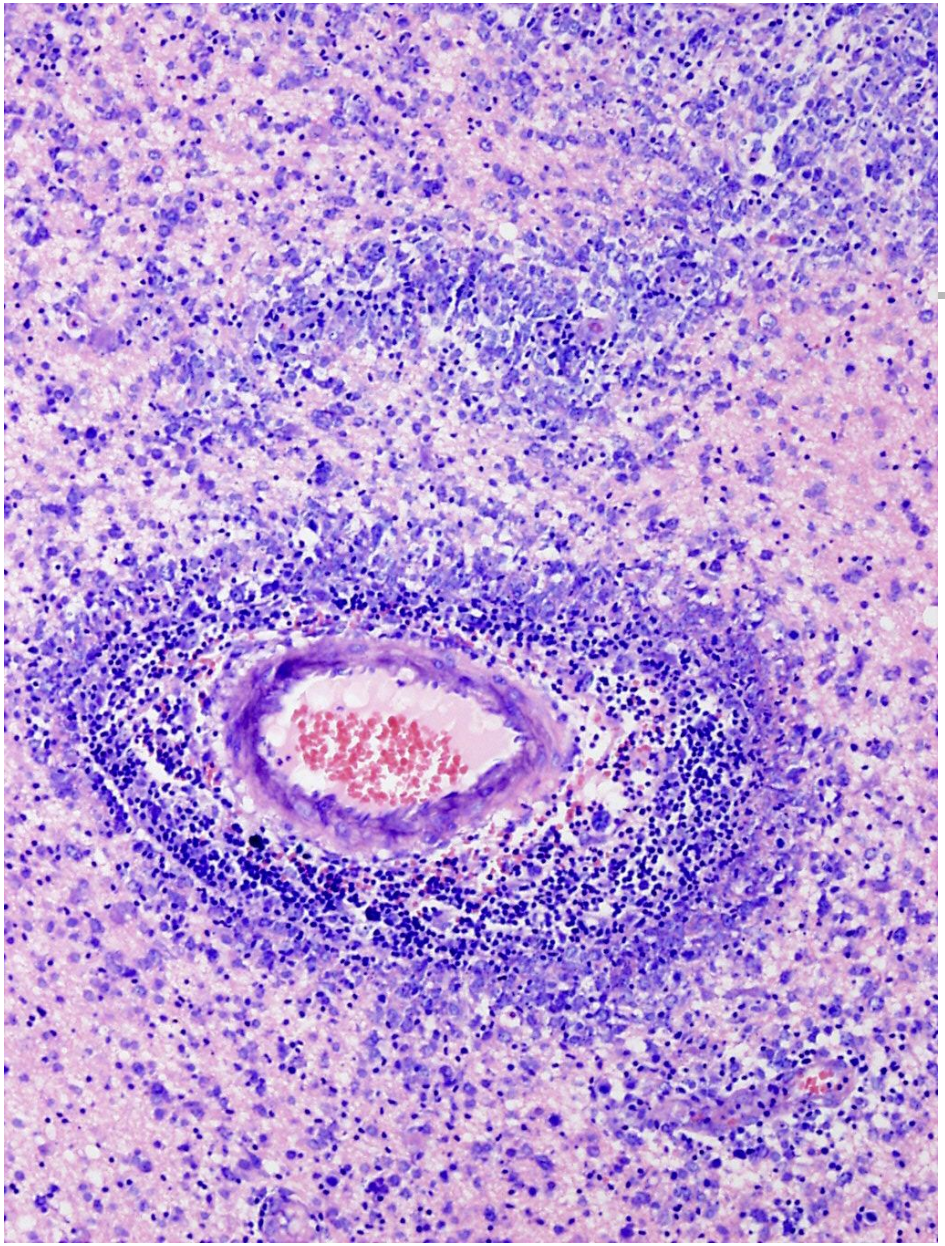

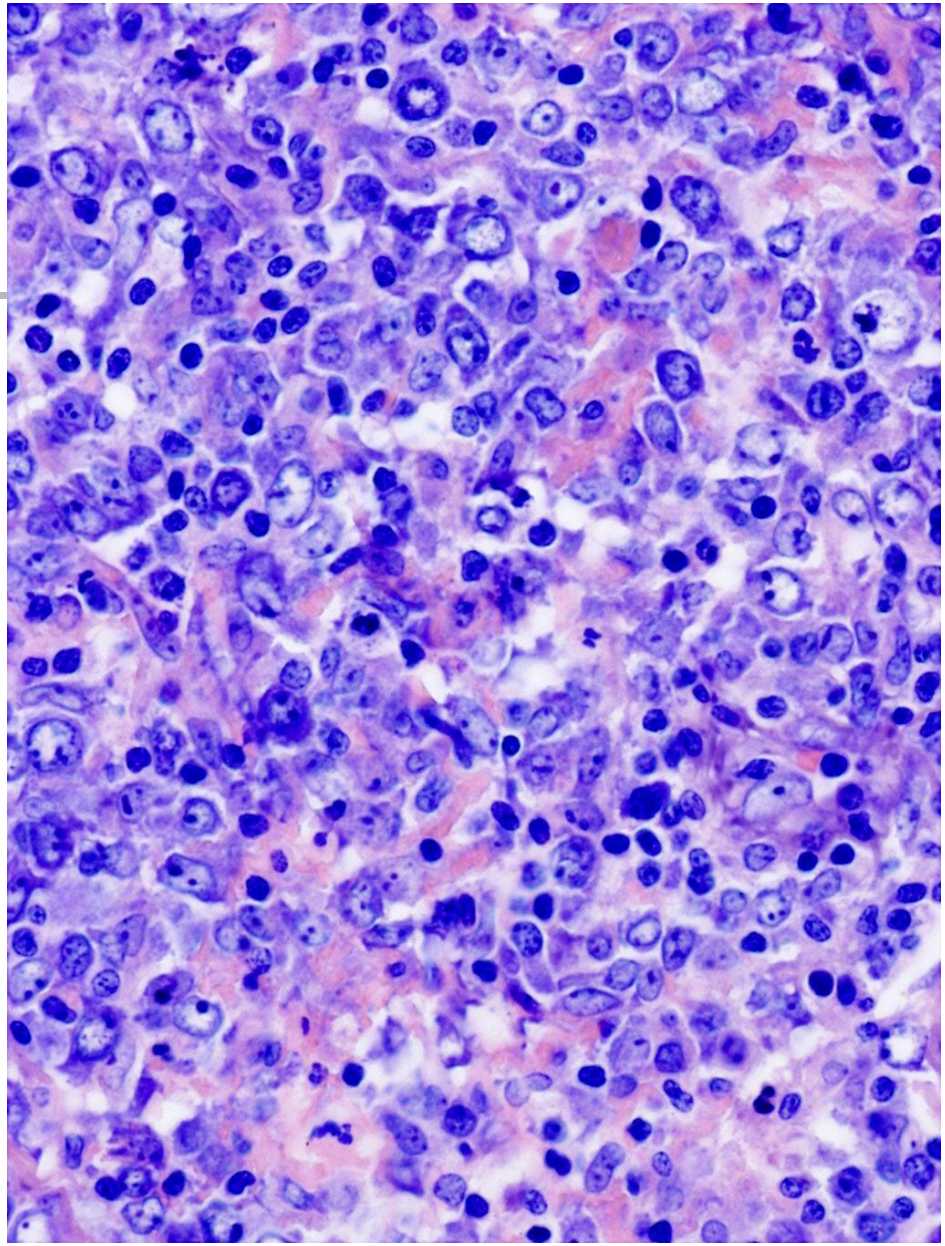

CD5

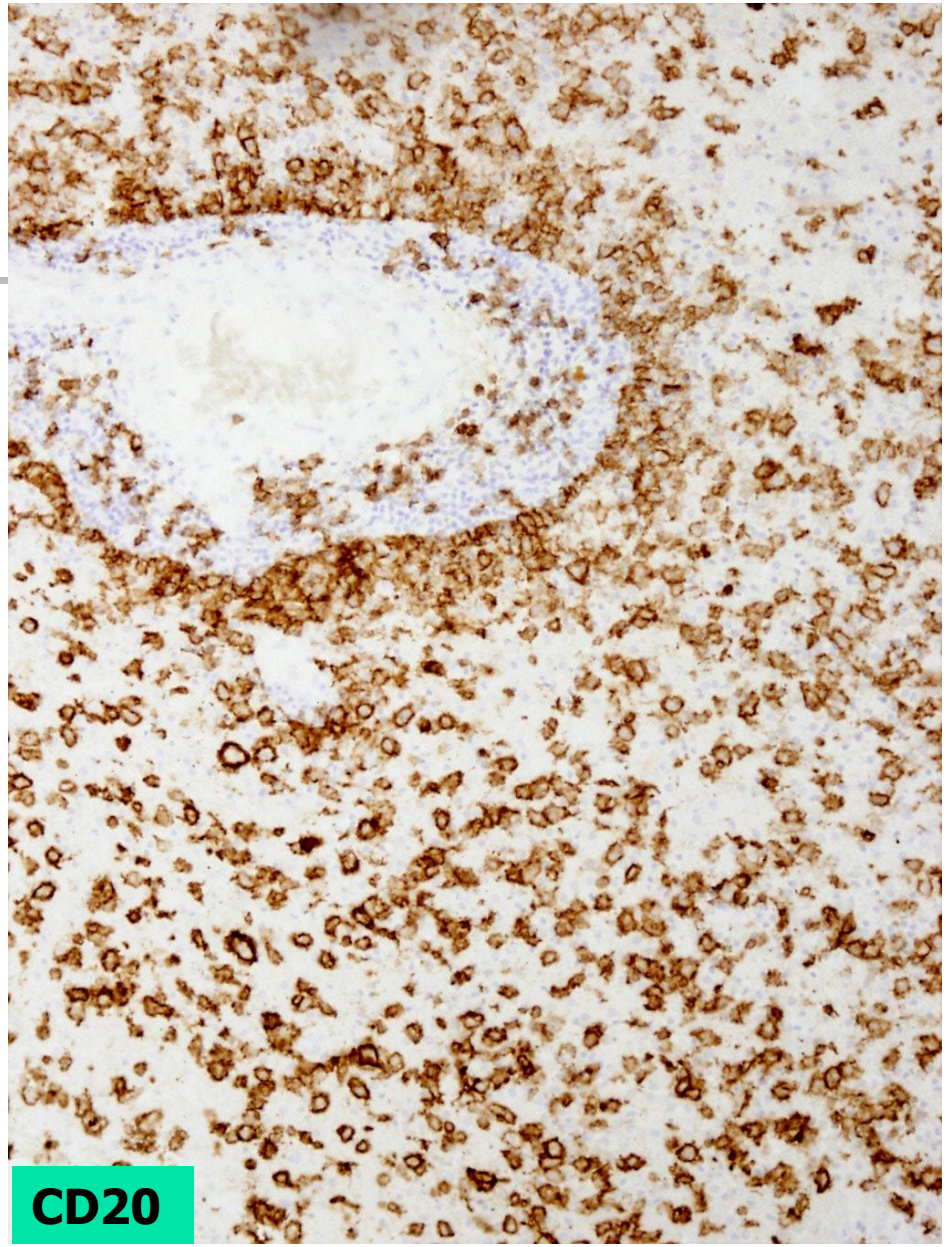
CD20

Imunoprofil:

- Pozitivita:
  CD20, bcl2, MUM1

- Negativita:
  GFAP, CD5, CD10, bcl6 (menej ako 20%)

Genetika:

Bez prestavby BCL2, BCL6 a MYC génov

Z á v e r :

Blastický B-NHL zo spektra difúzneho veľkobunkového B-lymfómu (DLBCL), morfologicky centroblastový variant, fenotypove non-GCB typ, v.s. primárny DLBCL CNS (PCNSL).

Prípad č.4

- žena, 65 rokov
- mozog okrem lalokov a komôr
- konzultácia Cytopathos, BA

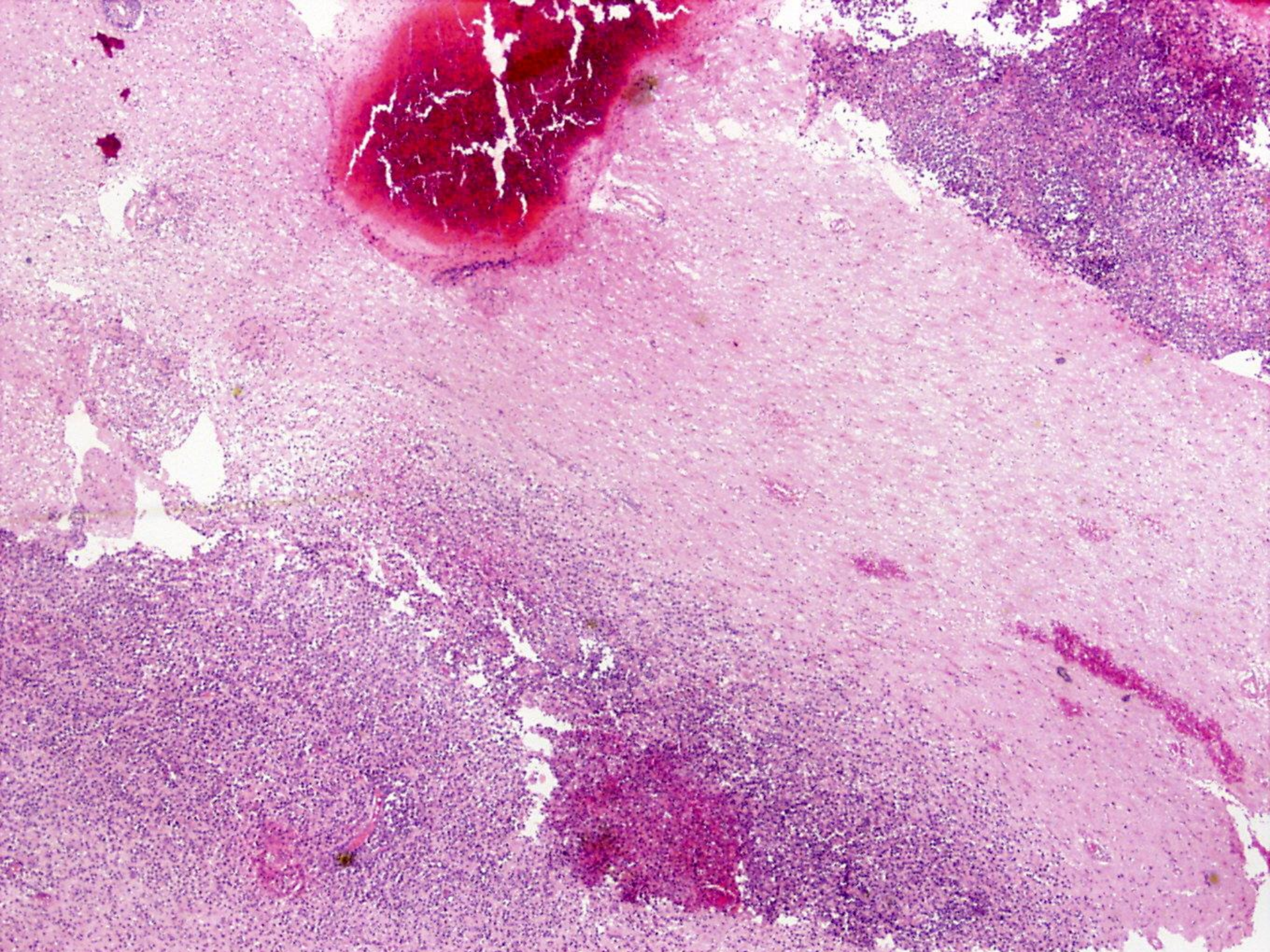

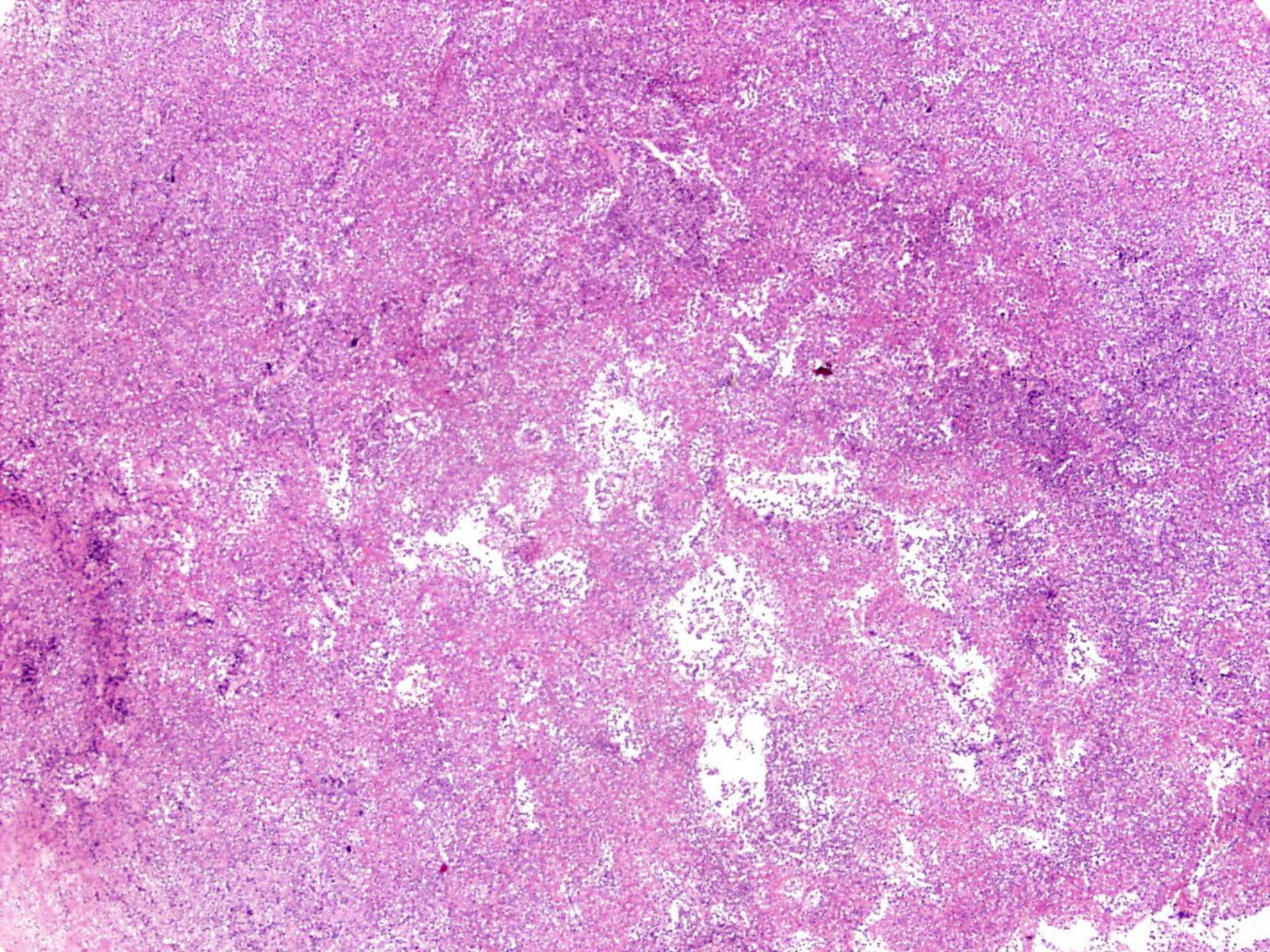

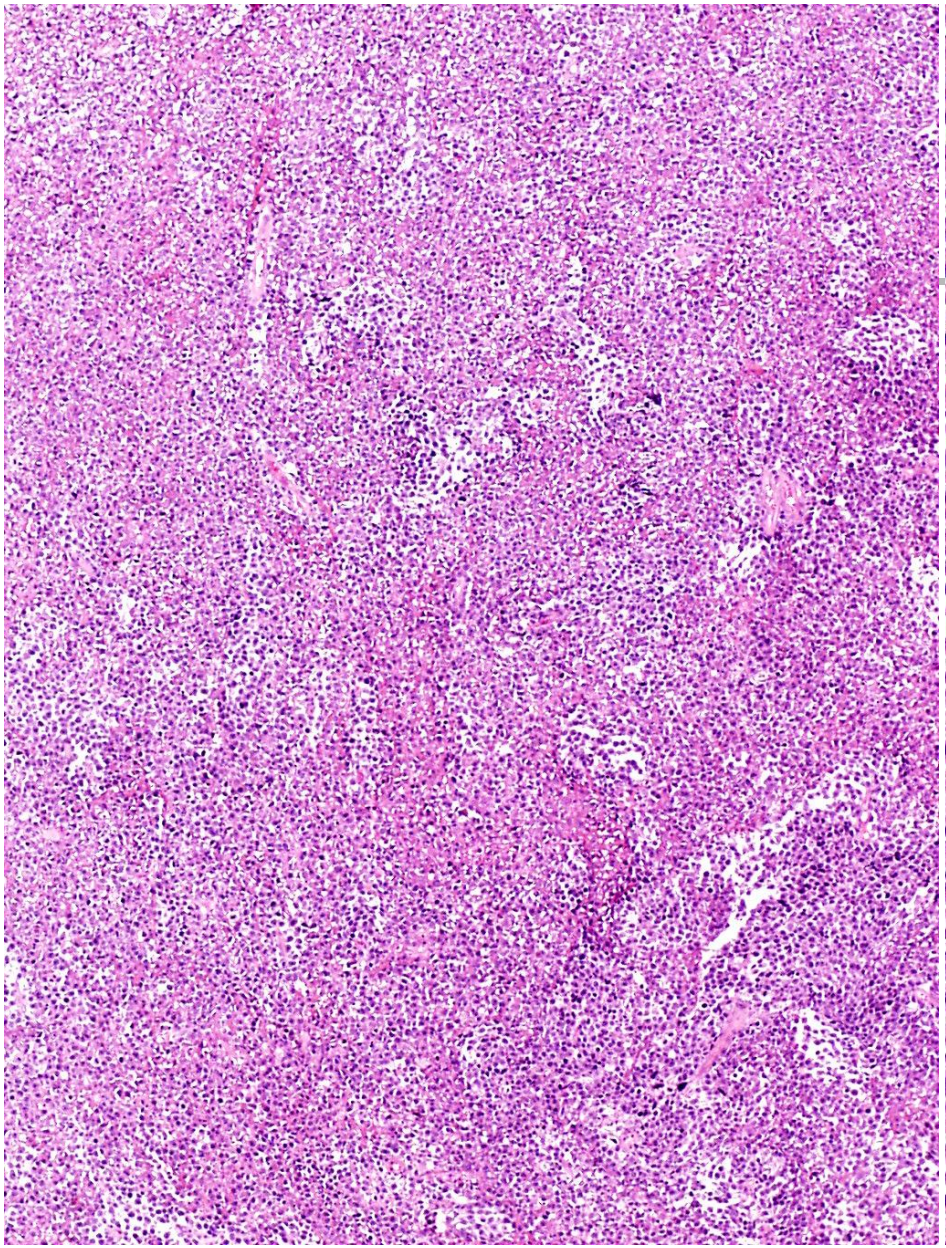

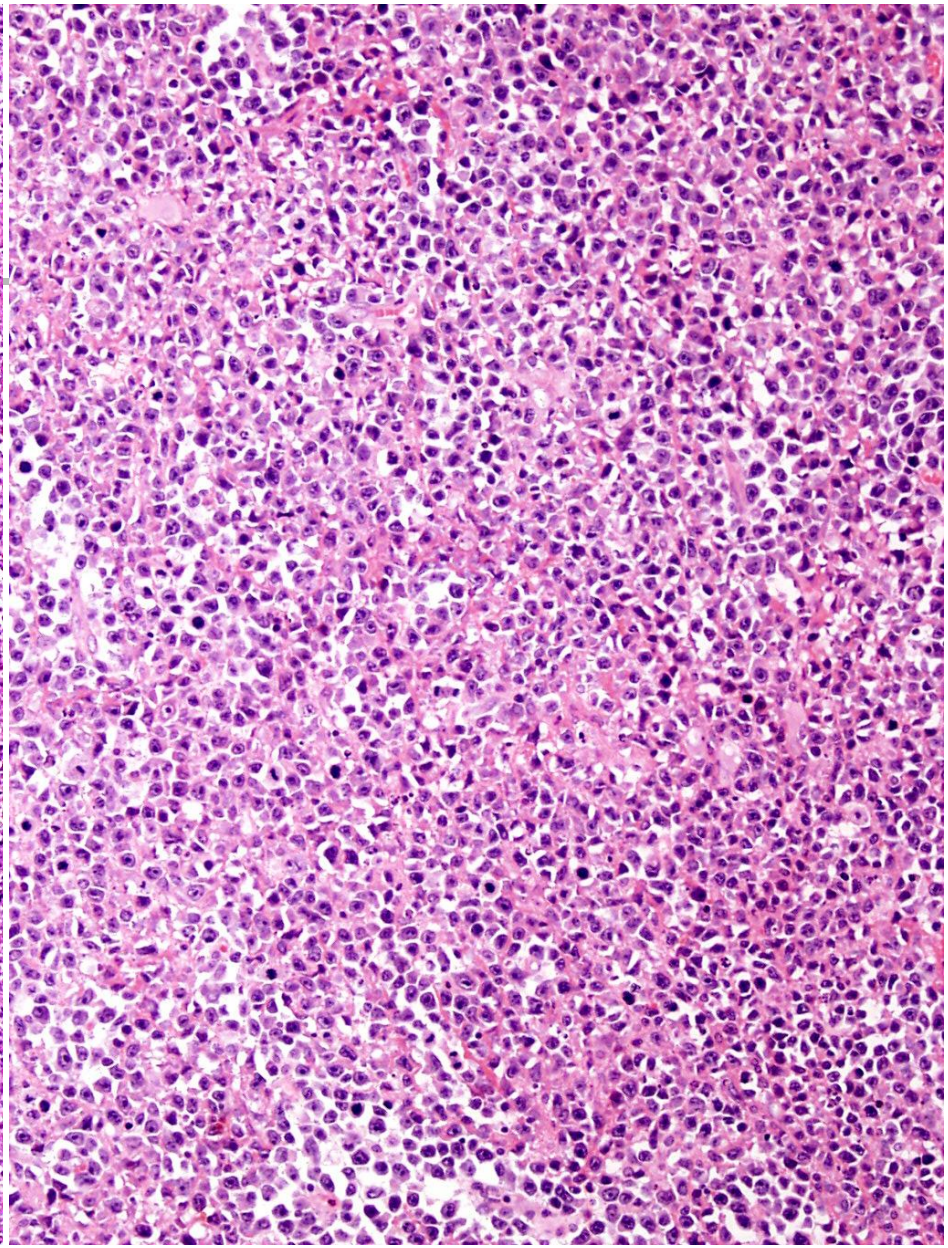

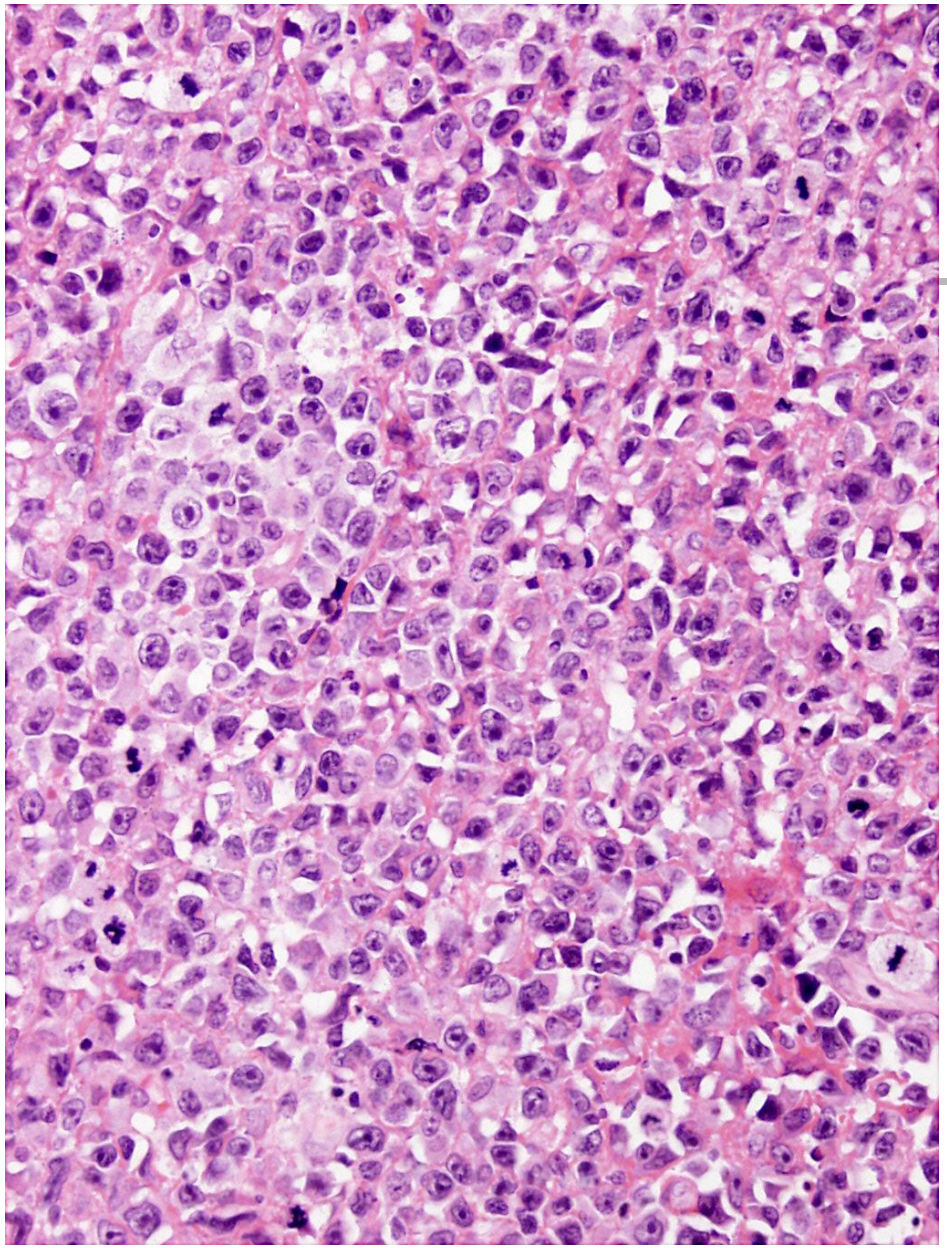

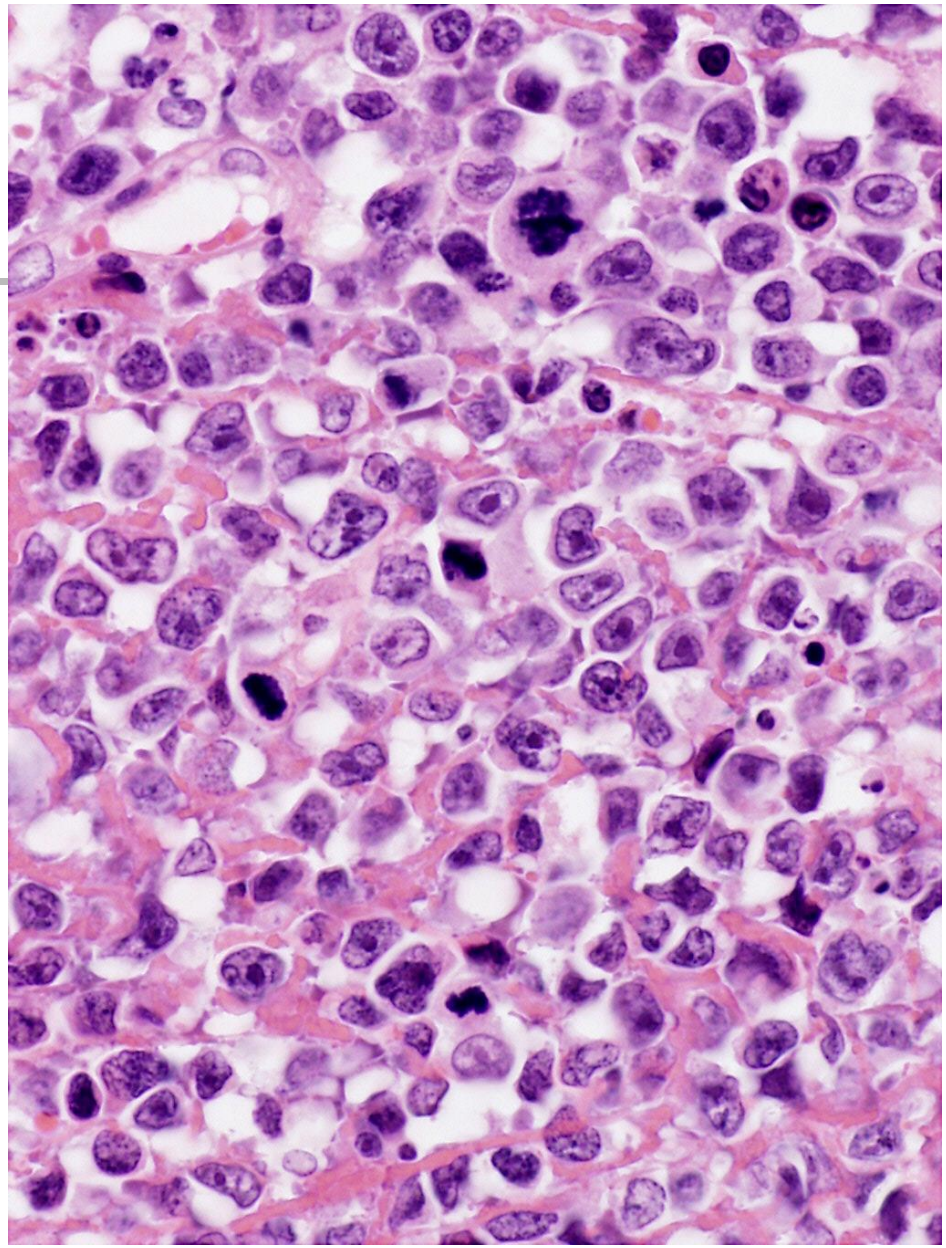

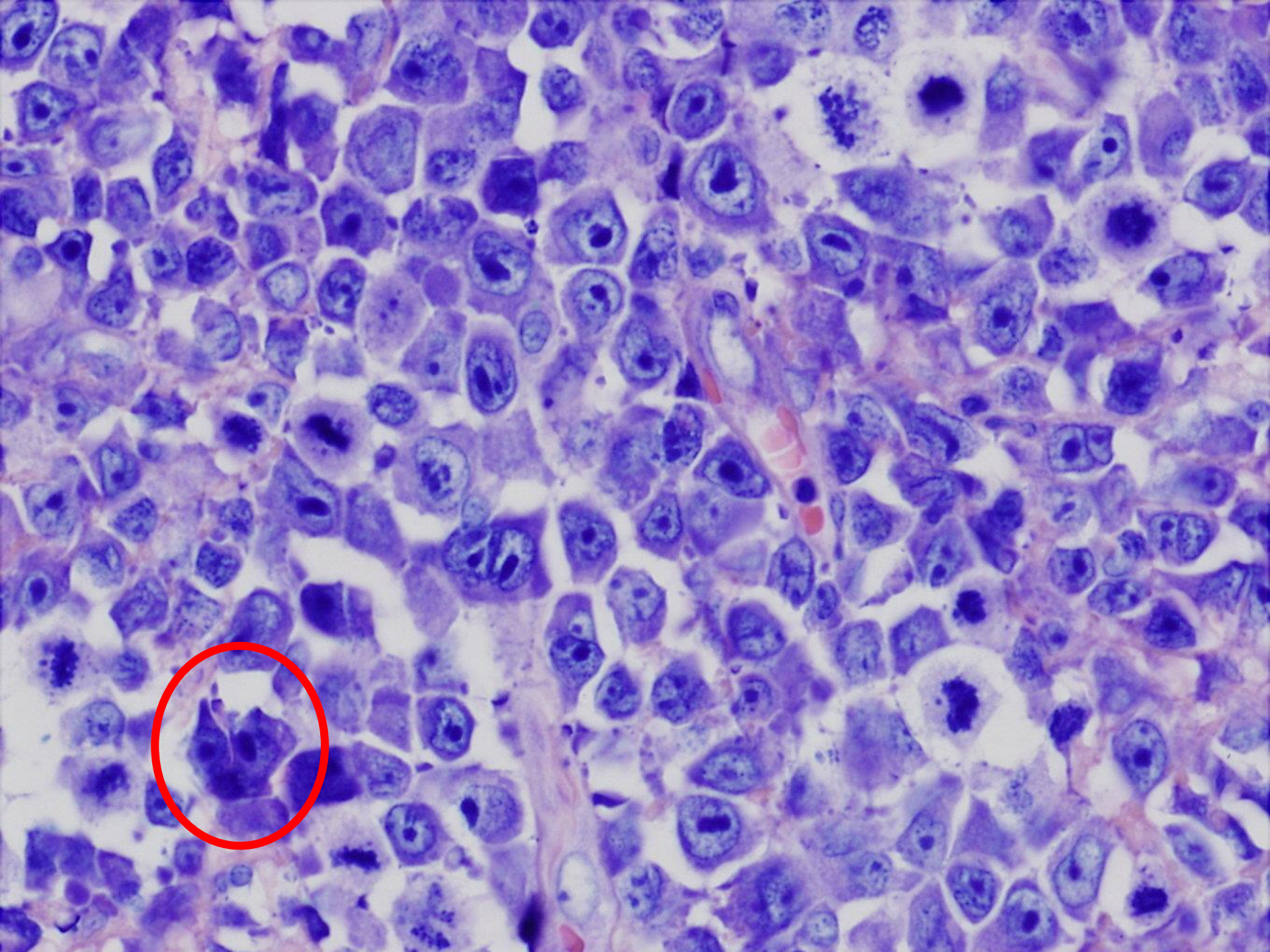

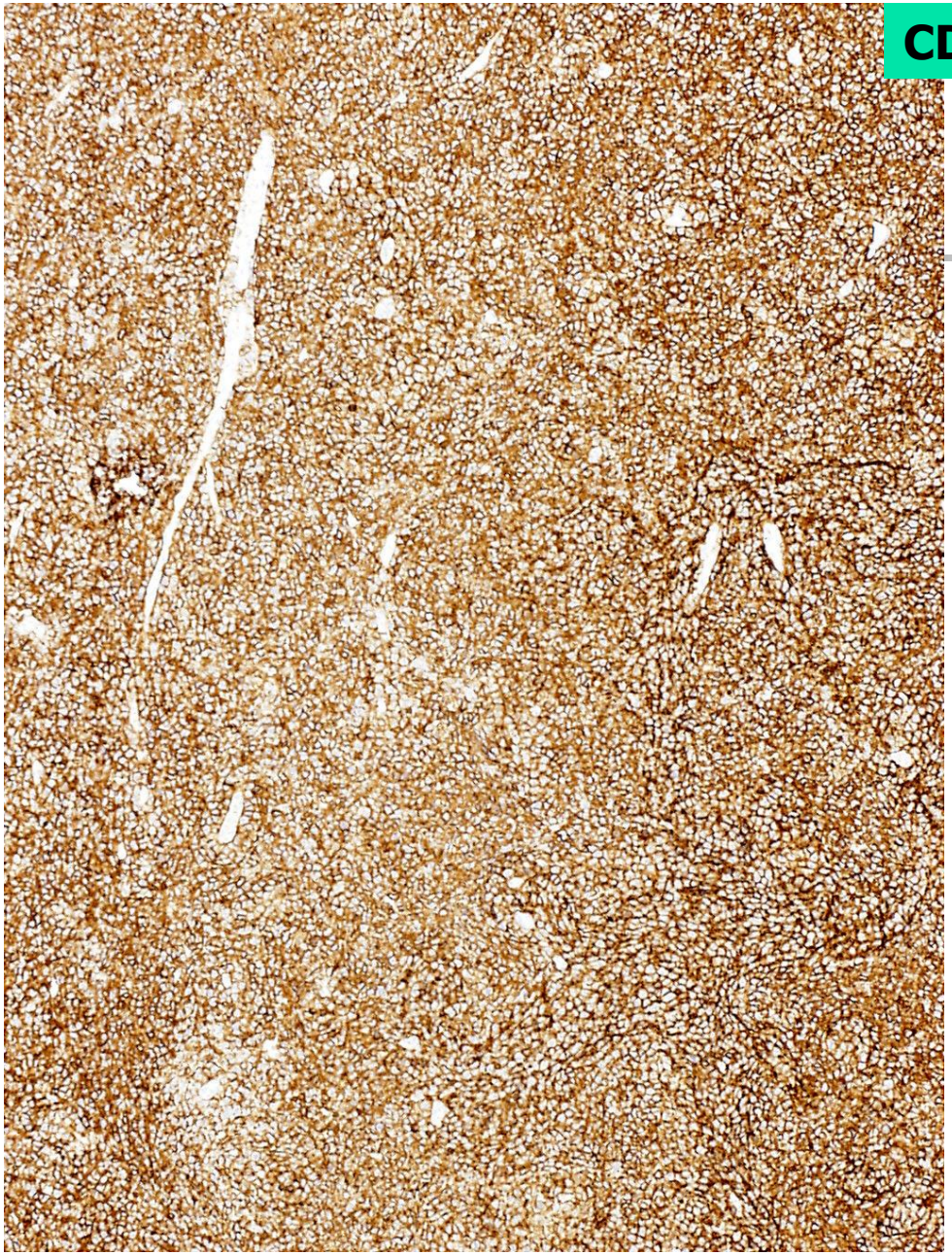

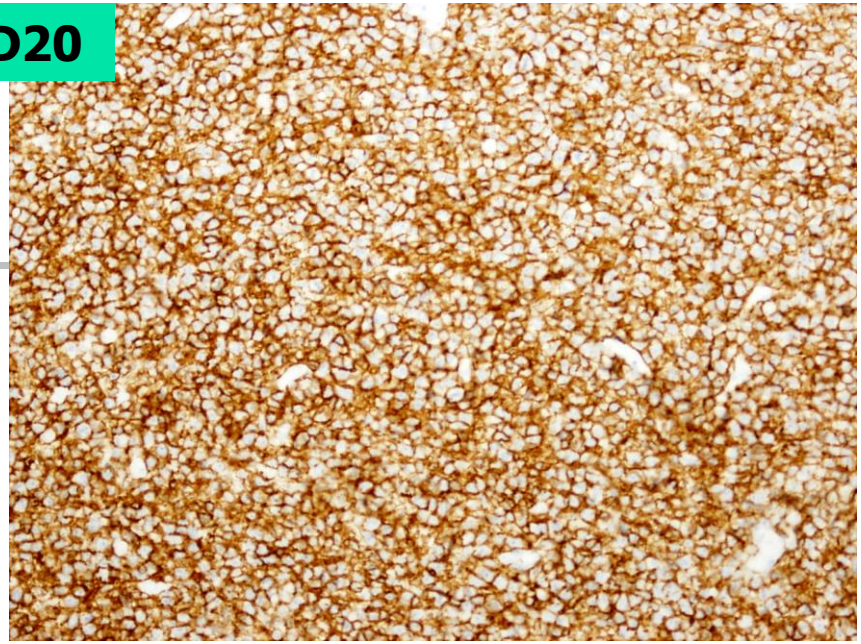
CD20

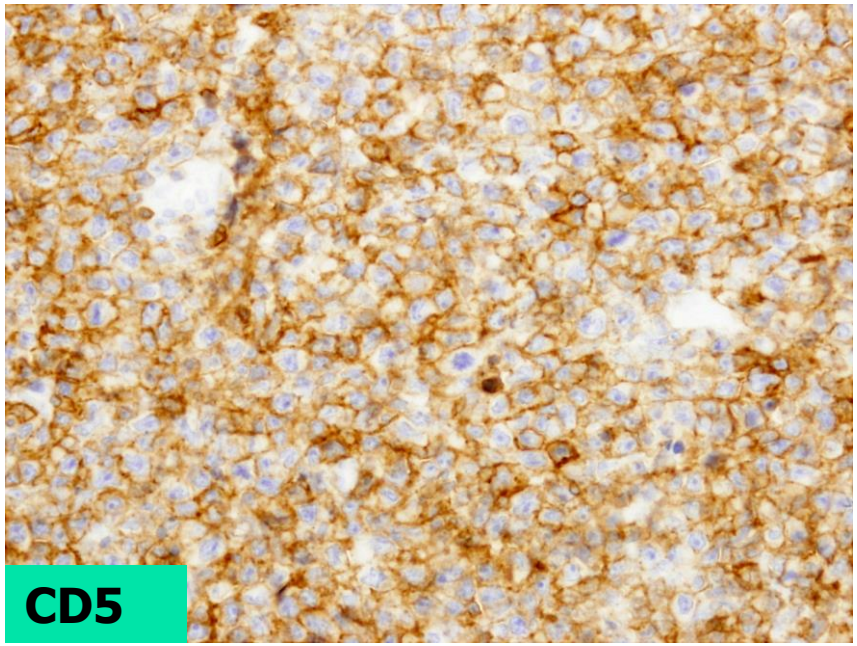
CD5

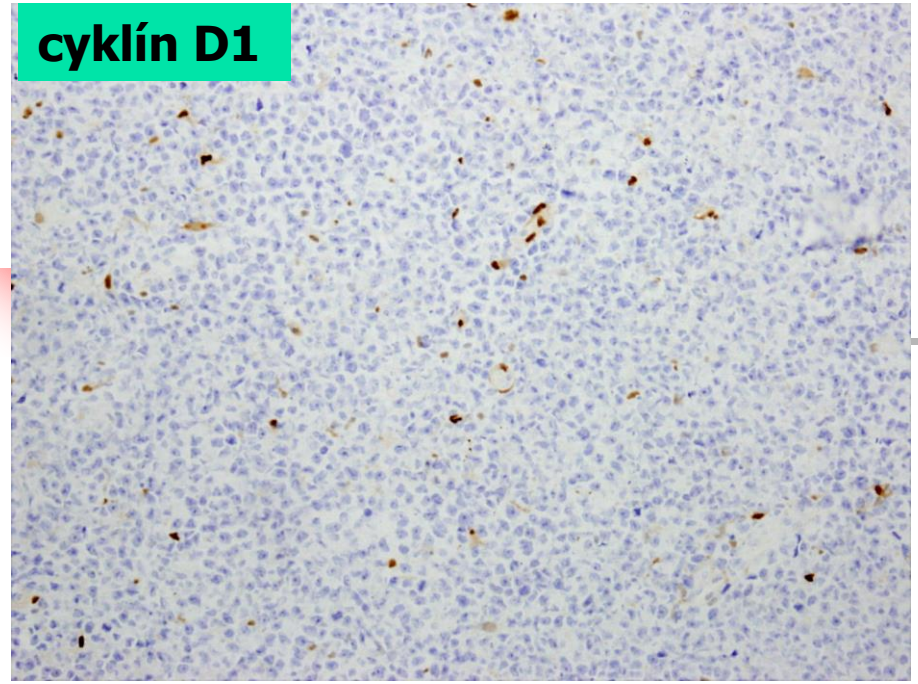
cyklín D1

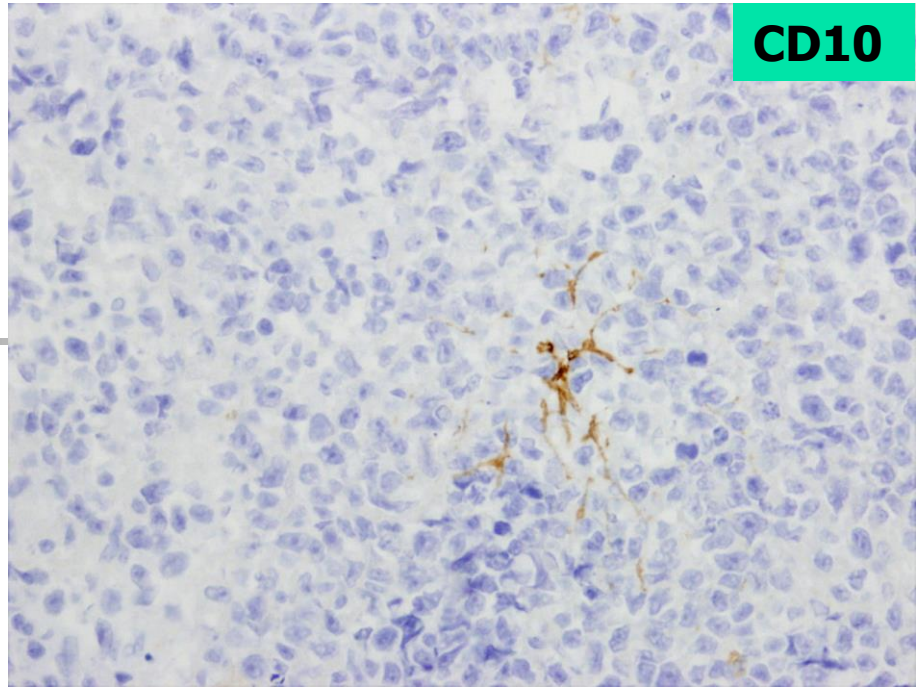
CD10

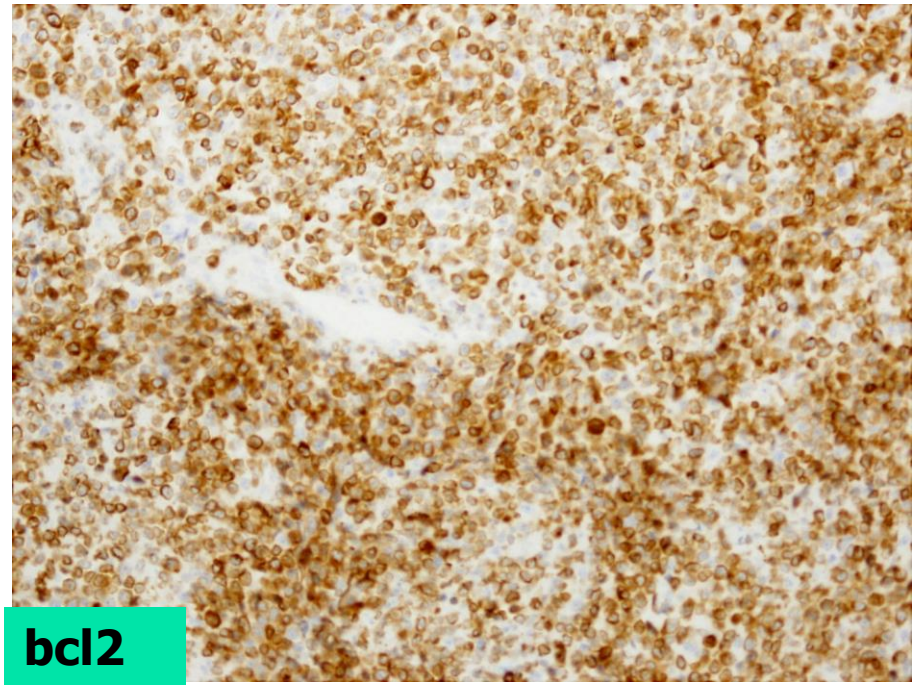
bcl2

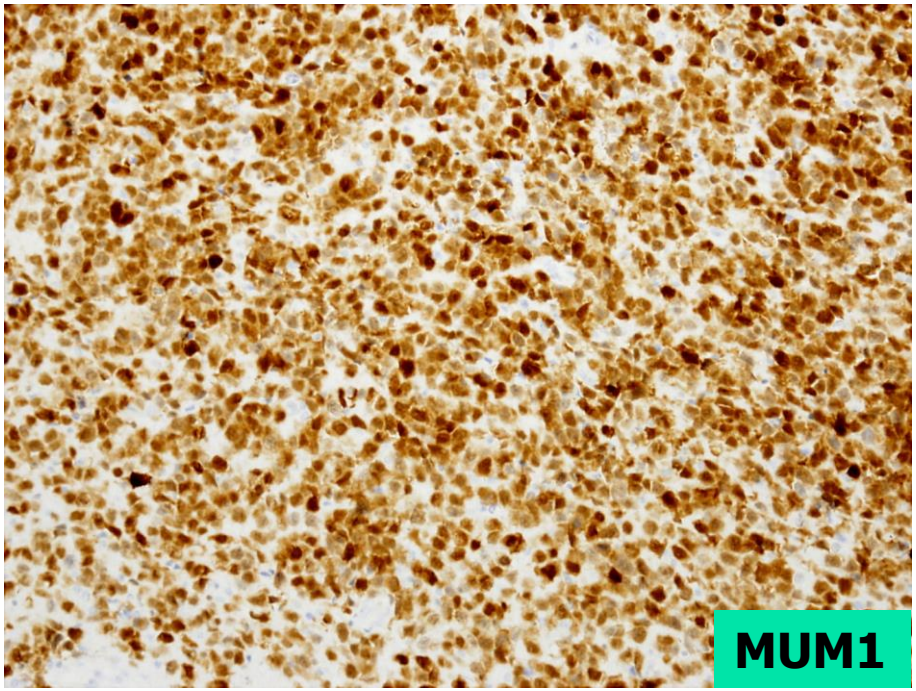
MUM1

Imunoprofil:

- Pozitivita:

  CD20, CD5, bcl2, MUM1, (CD45)

- Negativita:

  CD10, bcl6, cyklín D1

Záver:

Infiltrácia tkaniva mozgu B-NHL zo spektra DLBCL, CD5 pozitívny imunoblastový variant, fenotypove non-GCB typ (PCNSL).

Prípad č.5

- muž, 68 rokov
- expanzia T-P l.dx.
- konzultácia BB Biocyt

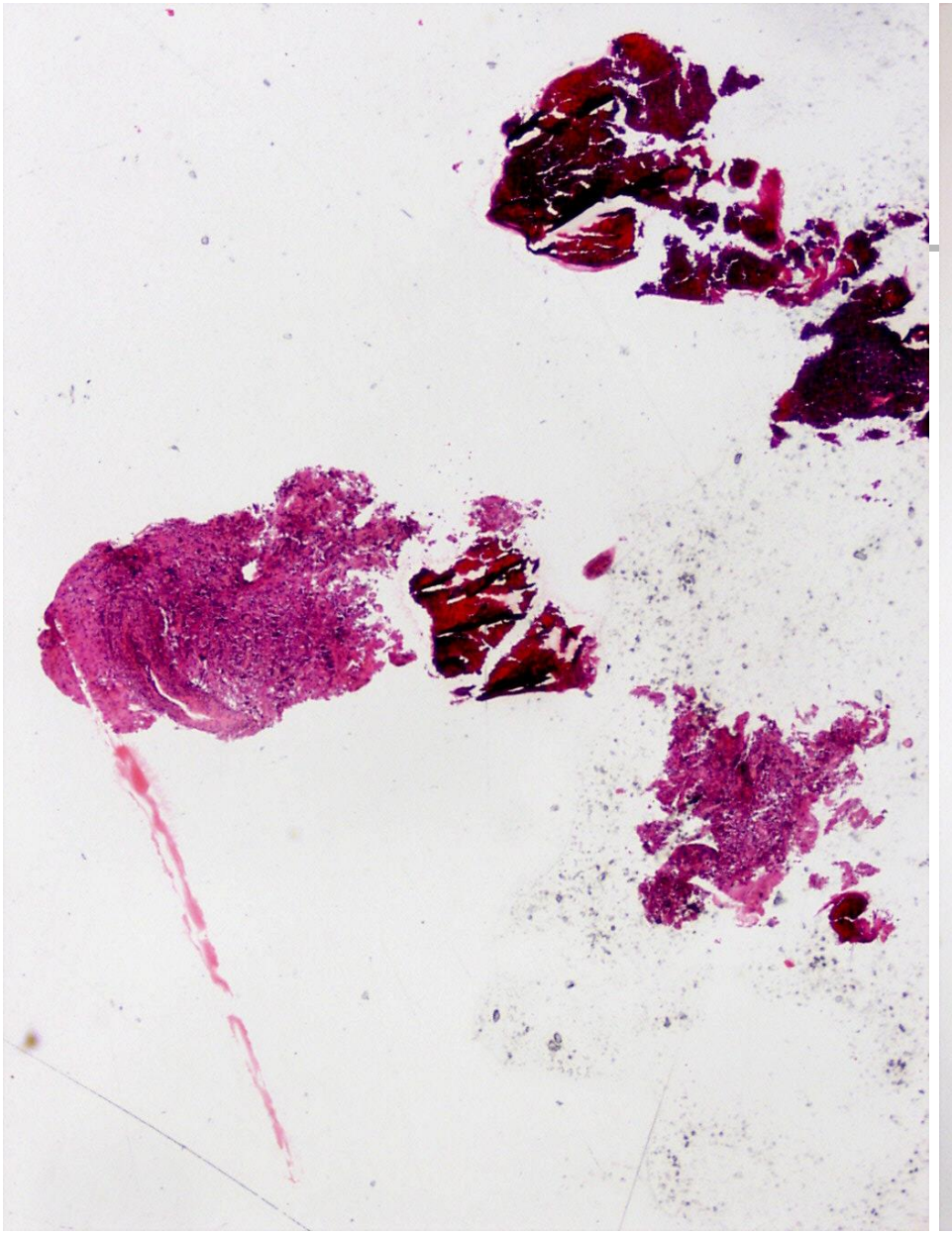

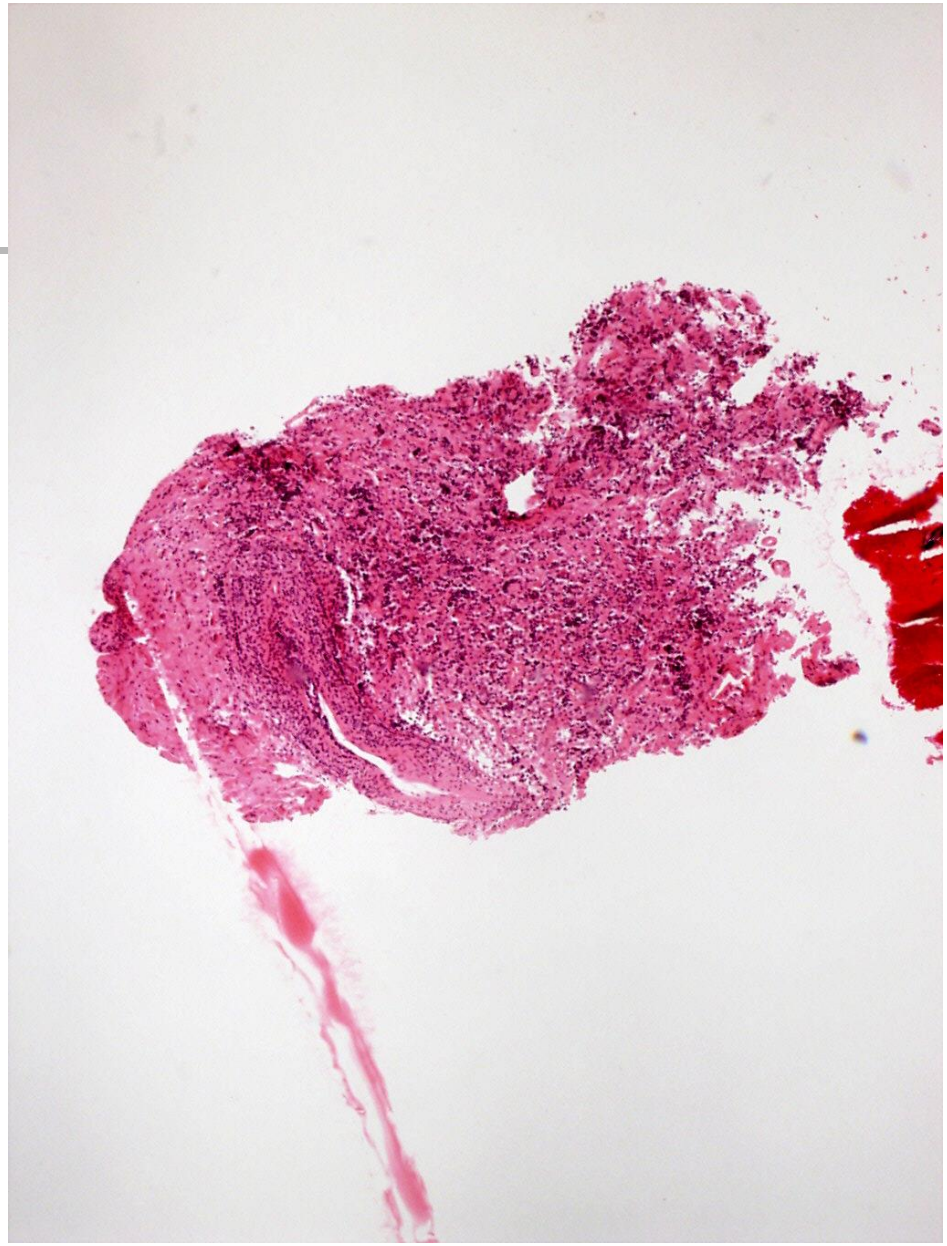

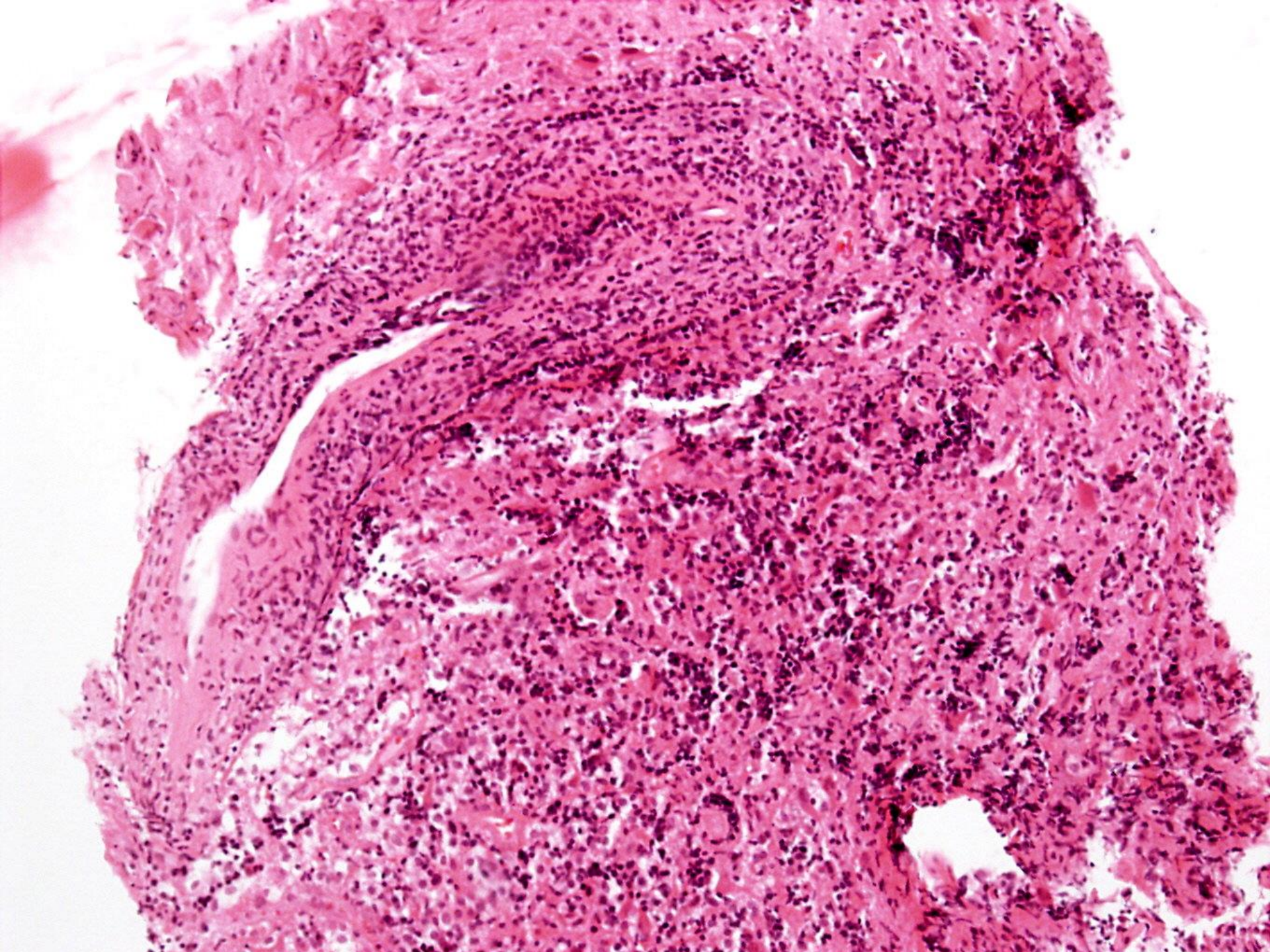

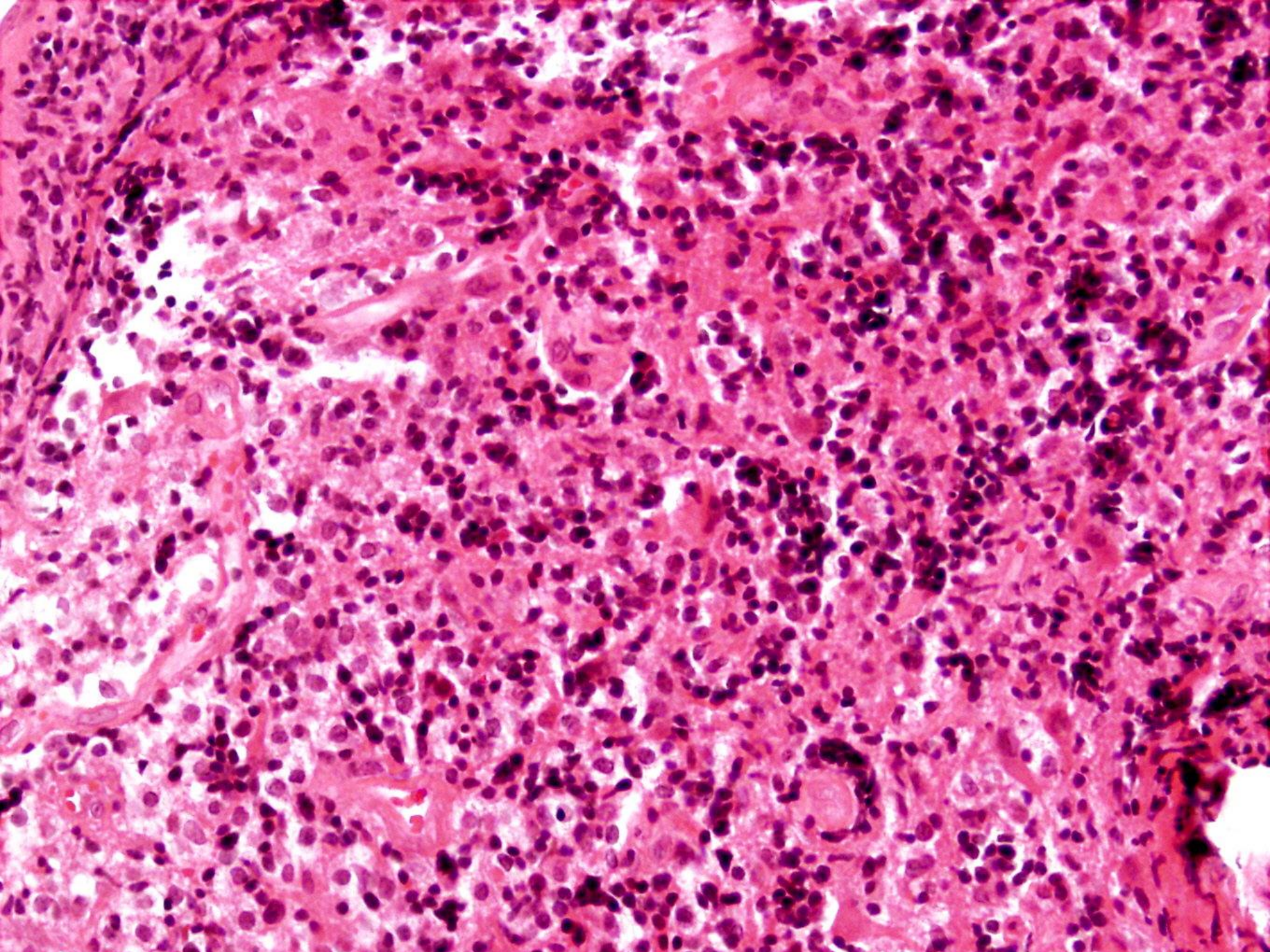

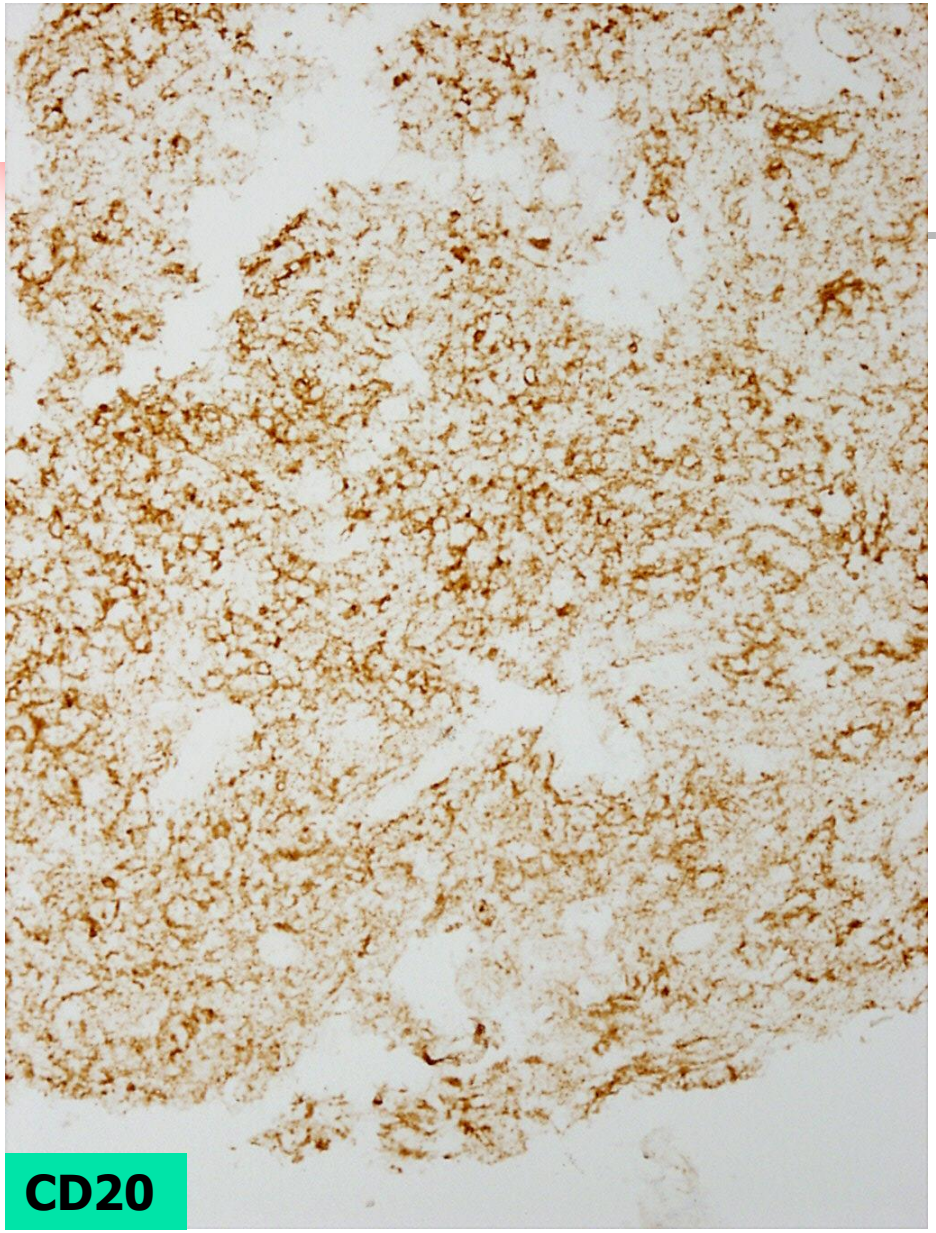
CD20

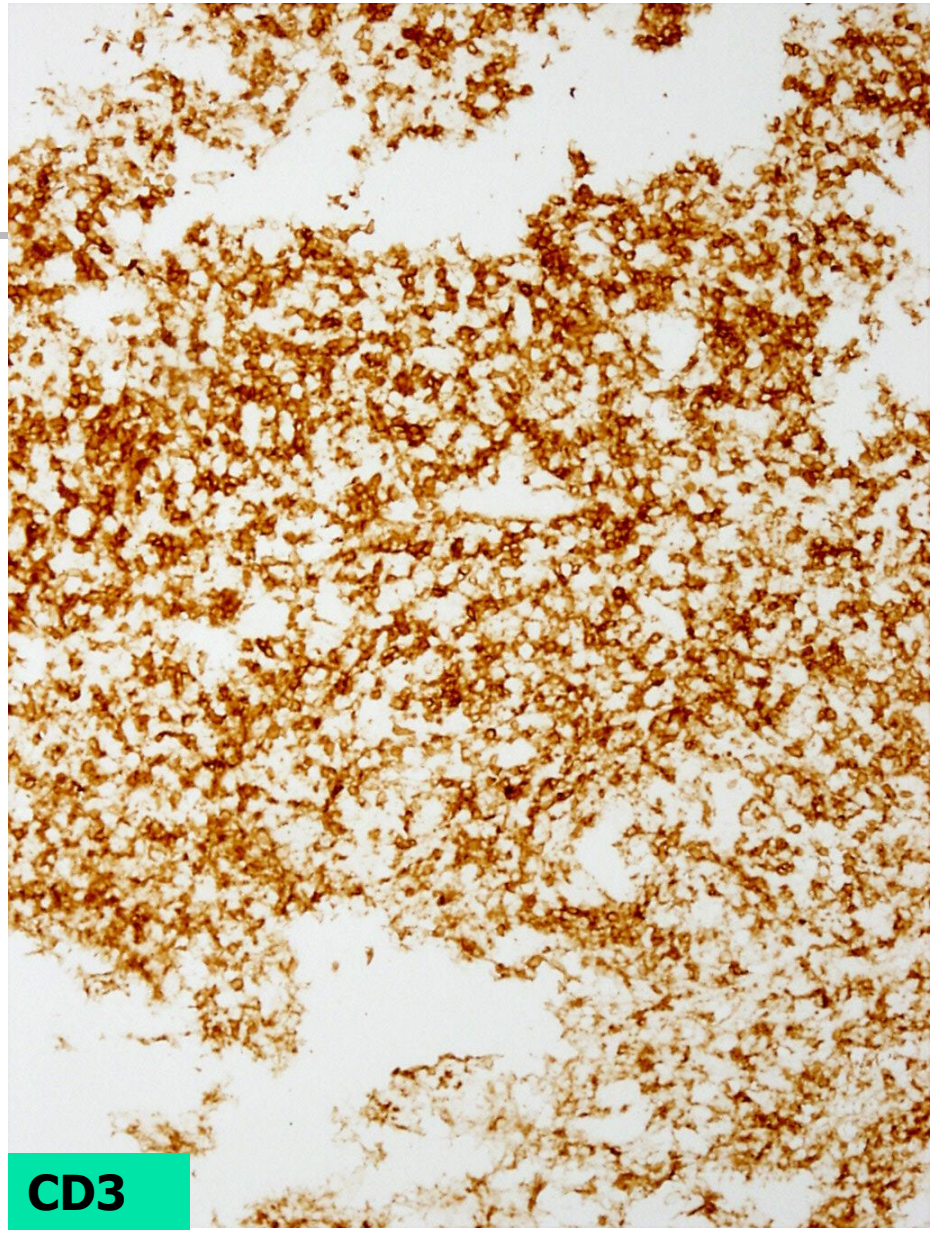
CD3

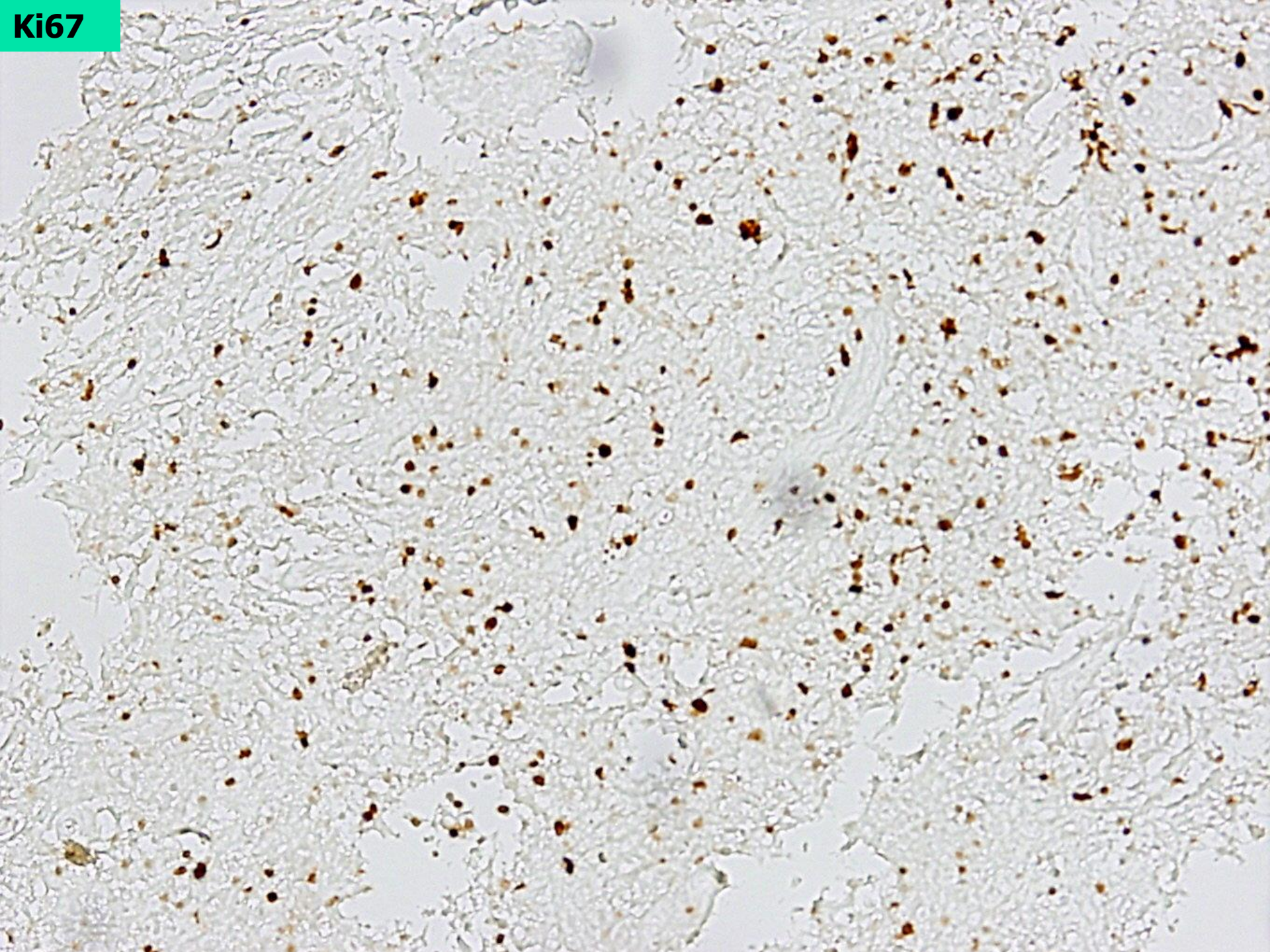
Ki67

Imunoprofil:

- Pozitivita:

  CD20 len malá časť populácie, dôkaz CD3 je pozitívny v prevažnej väčšine buniek
- Dôkaz CD30 nie je spoľahlivo hodnotiteľný, proliferačná aktivita (index Ki-67) je menej ako 20%.

Záver:

Limitovaný materiál s obrazom atypickej, prevažne T-bunkovej, lymfoproliferácie bez možnosti bližšej typizácie v tomto materiáli (aj pre absenciu akýchkoľvek klinických údajov).

Rebiopsia

- „stagingová“ biopsia KD negatívna
- Tu mozgu
- odstup cca 1 mesiac- liečba ??

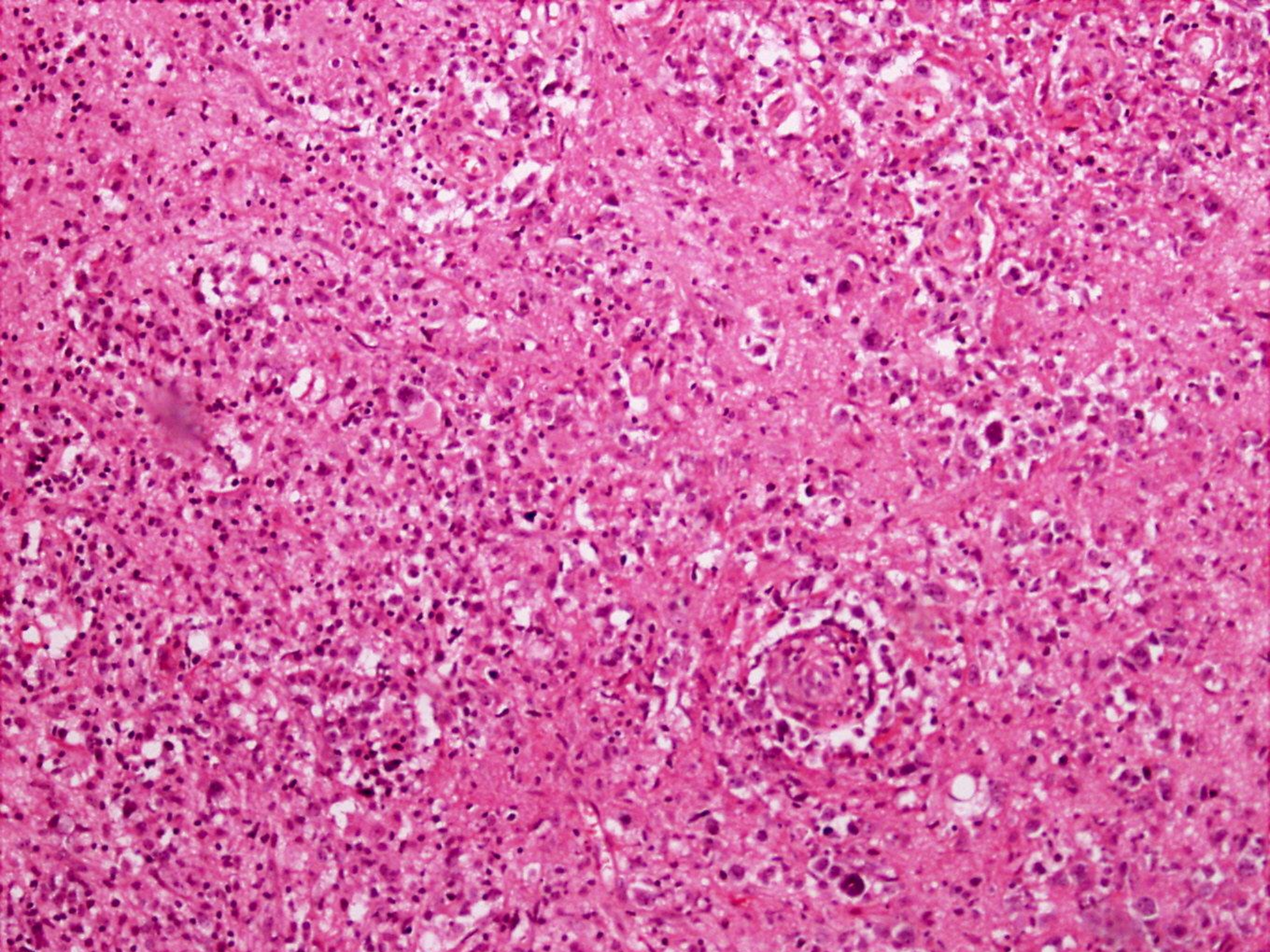

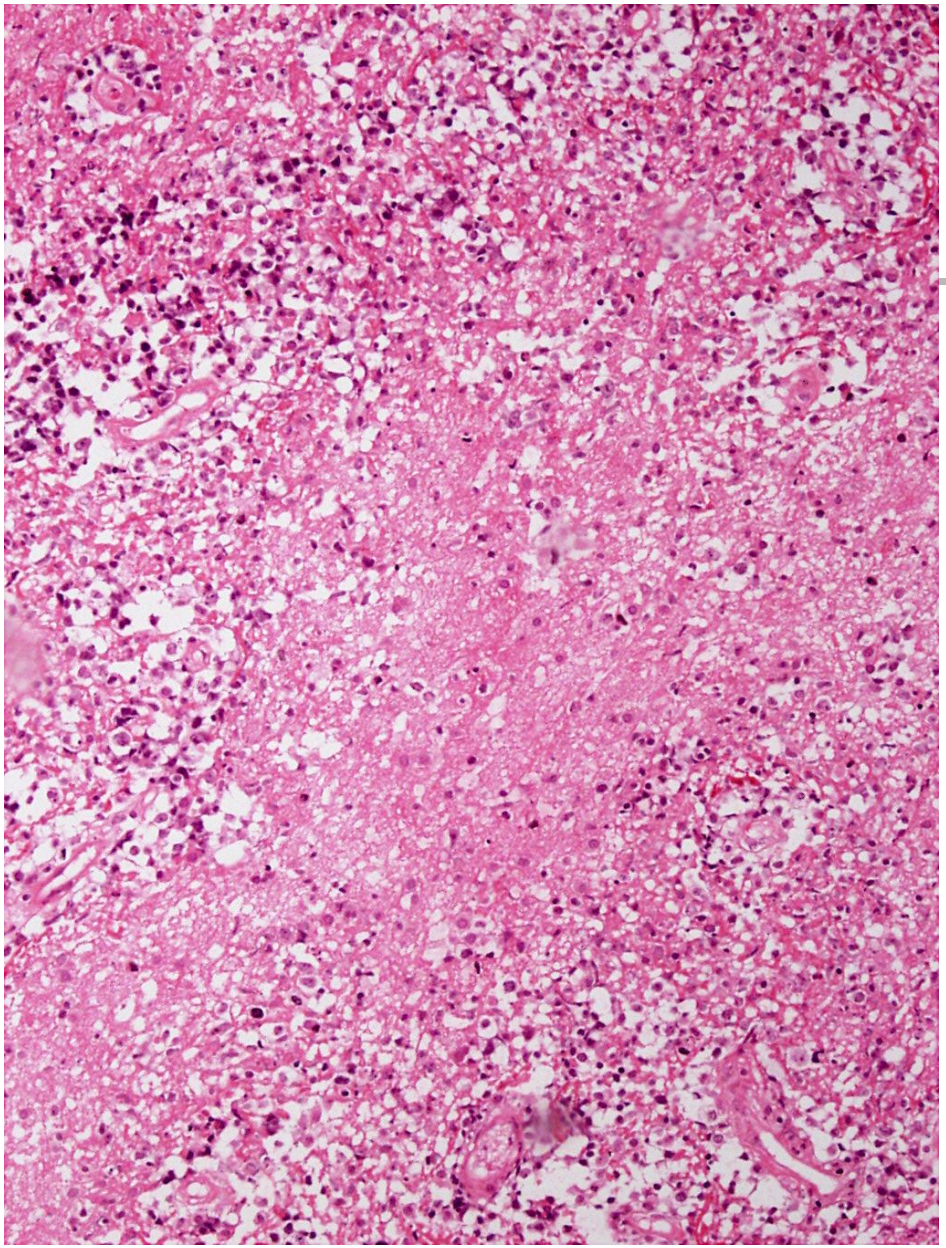

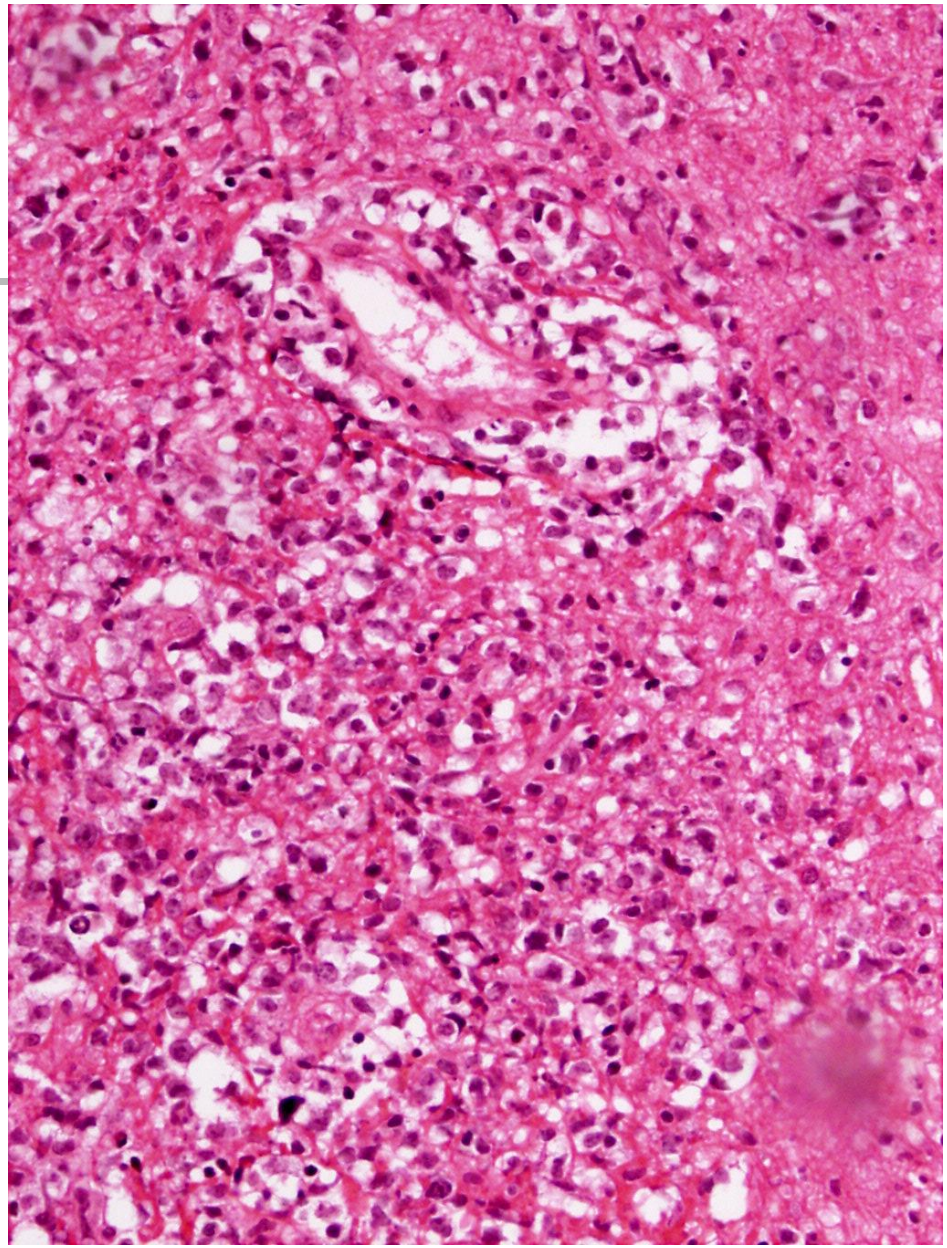

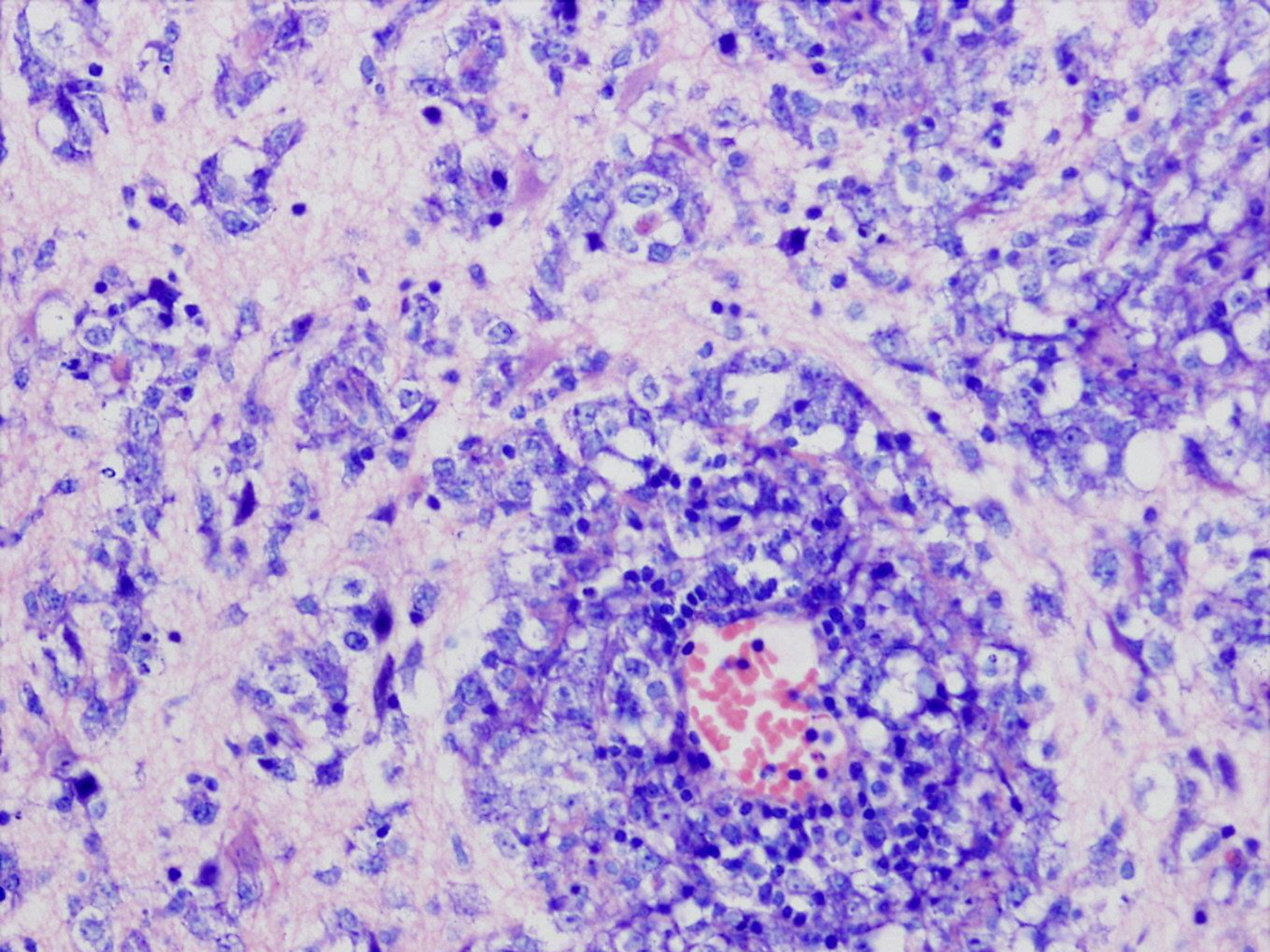

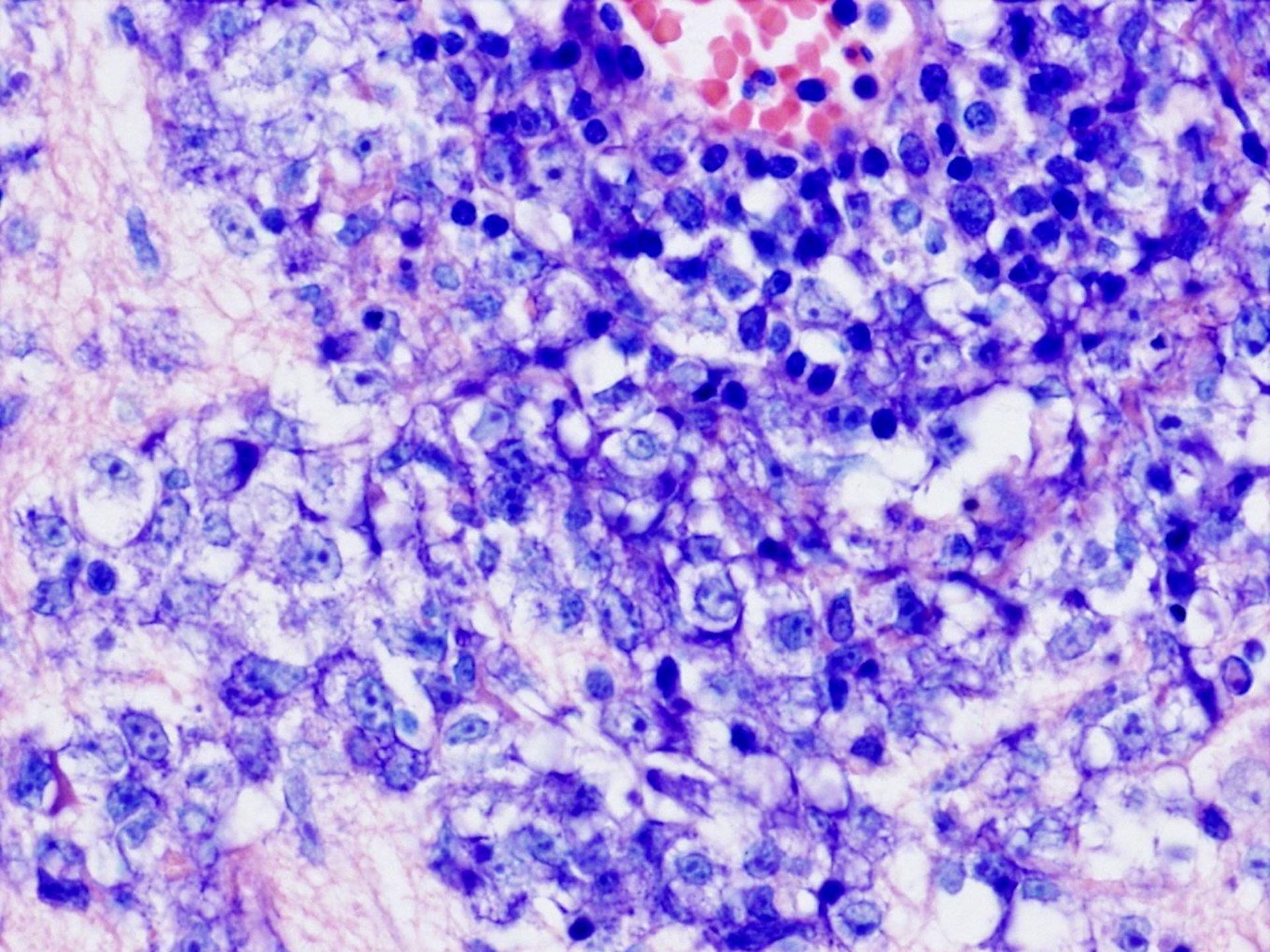

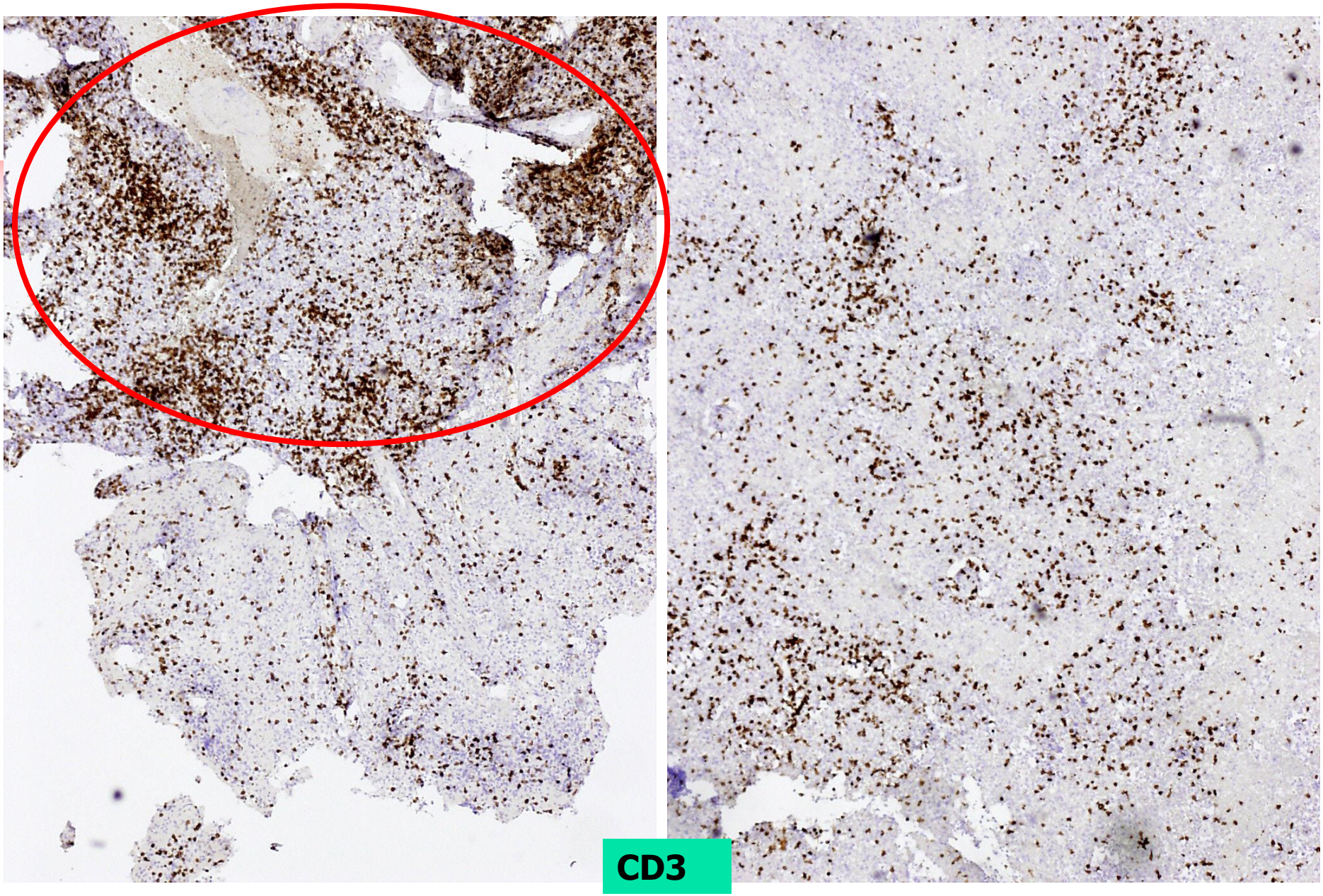
CD3

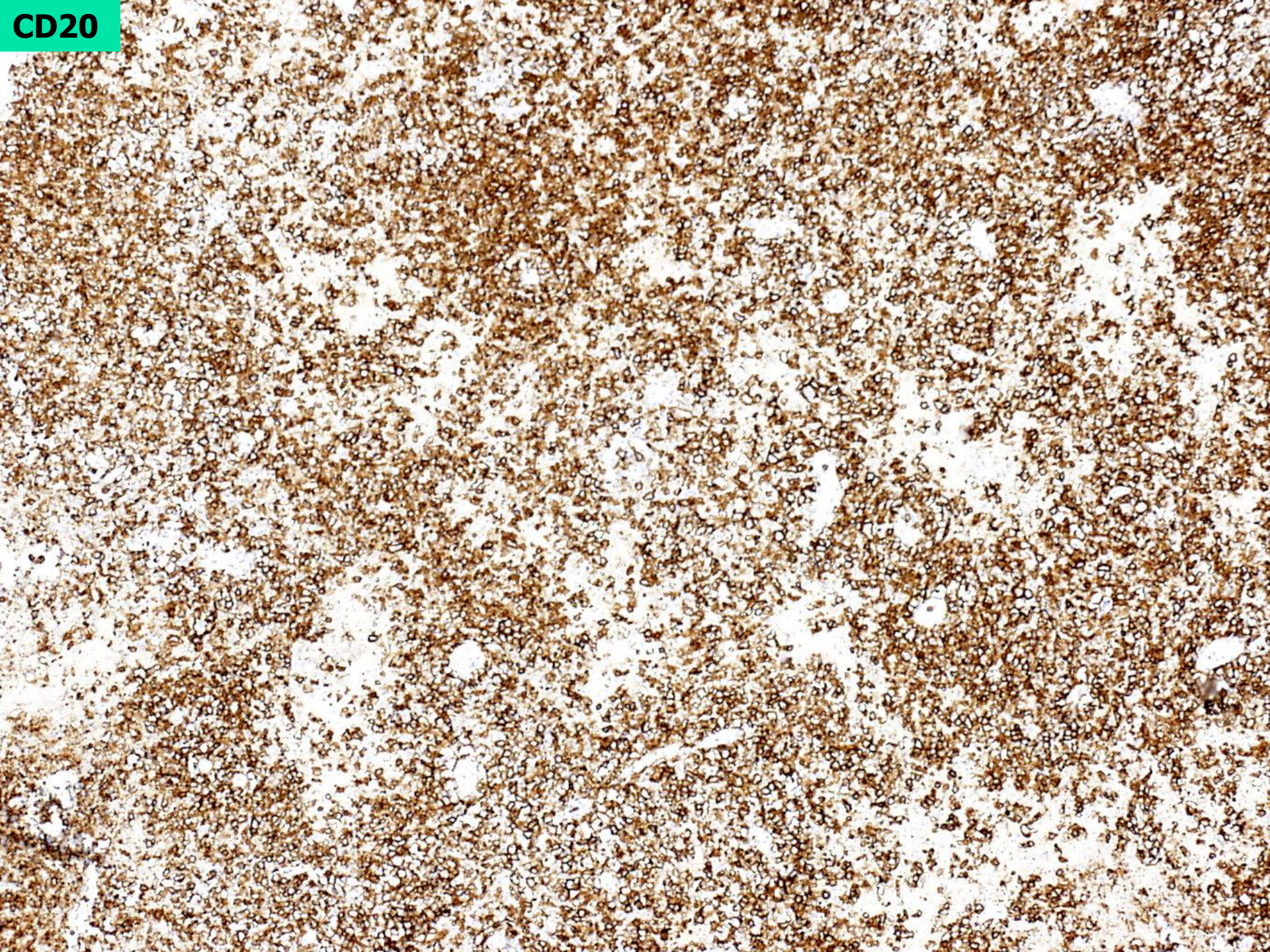
CD20

Imunoprofil:

- Pozitivita:

  CD45, CD20, bcl2, MUM1

- Negativita:

  CK8/18, CD3, CD10, bcl6, c-Ig

Z á v e r :

Blastický B-NHL typu DLBCL, morfologicky bližšie nezaraditeľný (NOS), s non-GCB fenotypom (PCNSL)

Komentár

- perivaskulárne T-bunkové infiltráty ako pozitívny prognostický znak PCNSL
- CAVE - pasca v limitovaných vzorkách

CD5

Prípad č.6

- žena, 66 rokov
- Tu cerebri multifokálny l.dx.
- pacientka má na MR BGBT a PET nález viacpočetných drobných ložísk v mozgu charakteru HG Tu, bez onko anamnézy, v.s. MTS
- Dg: Sekundárny zhubný nádor mozgu a mozgových plien
- konzultácia Cytopathos, BA

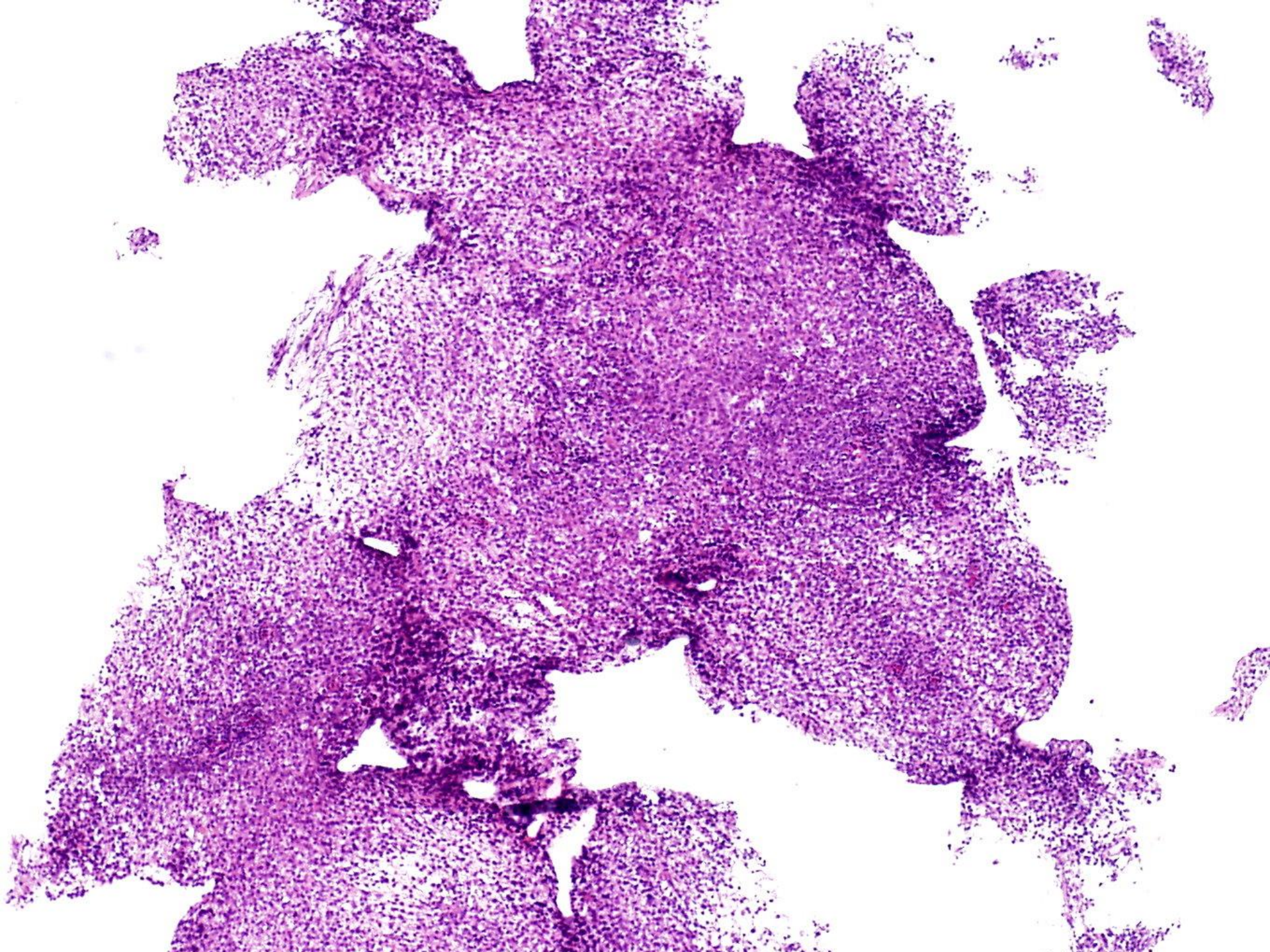

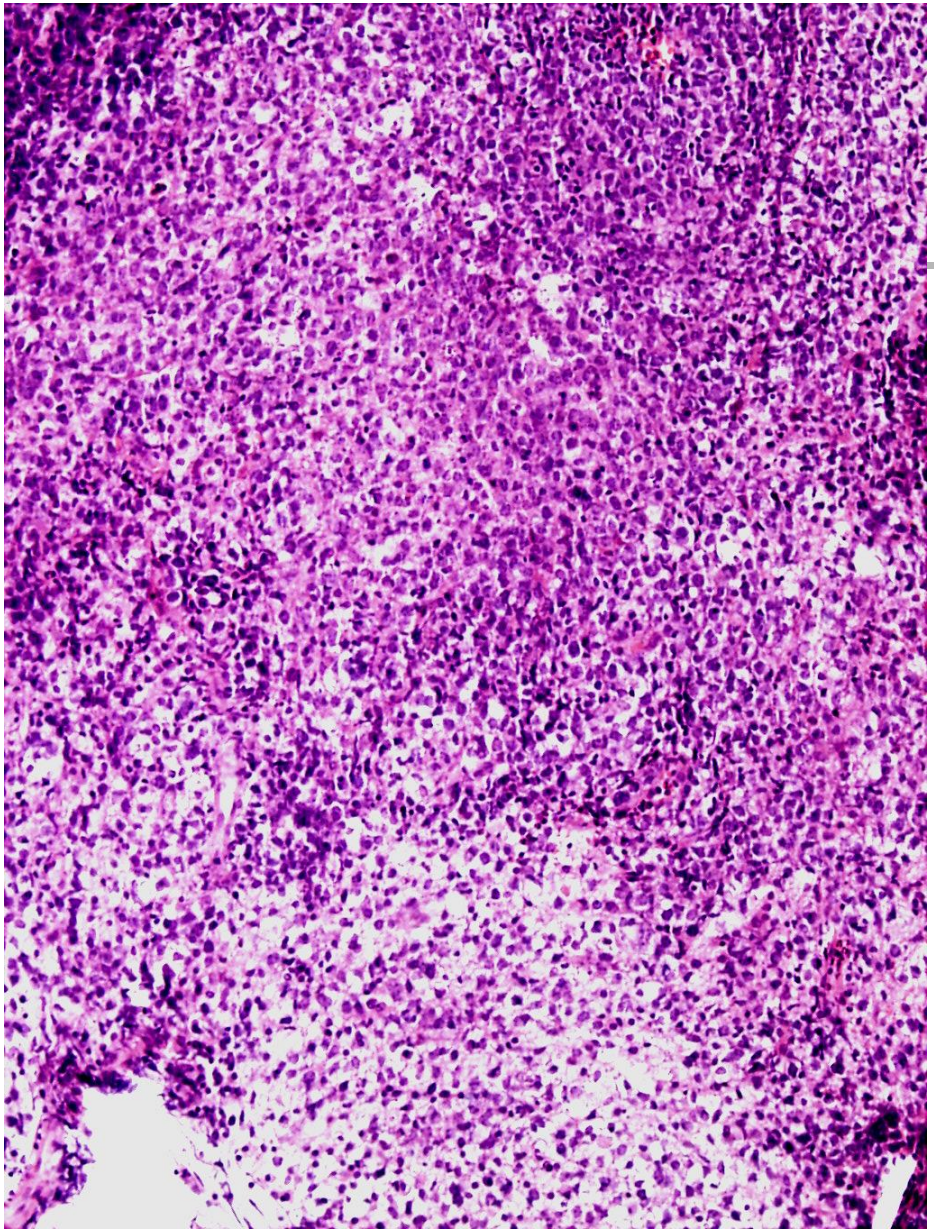

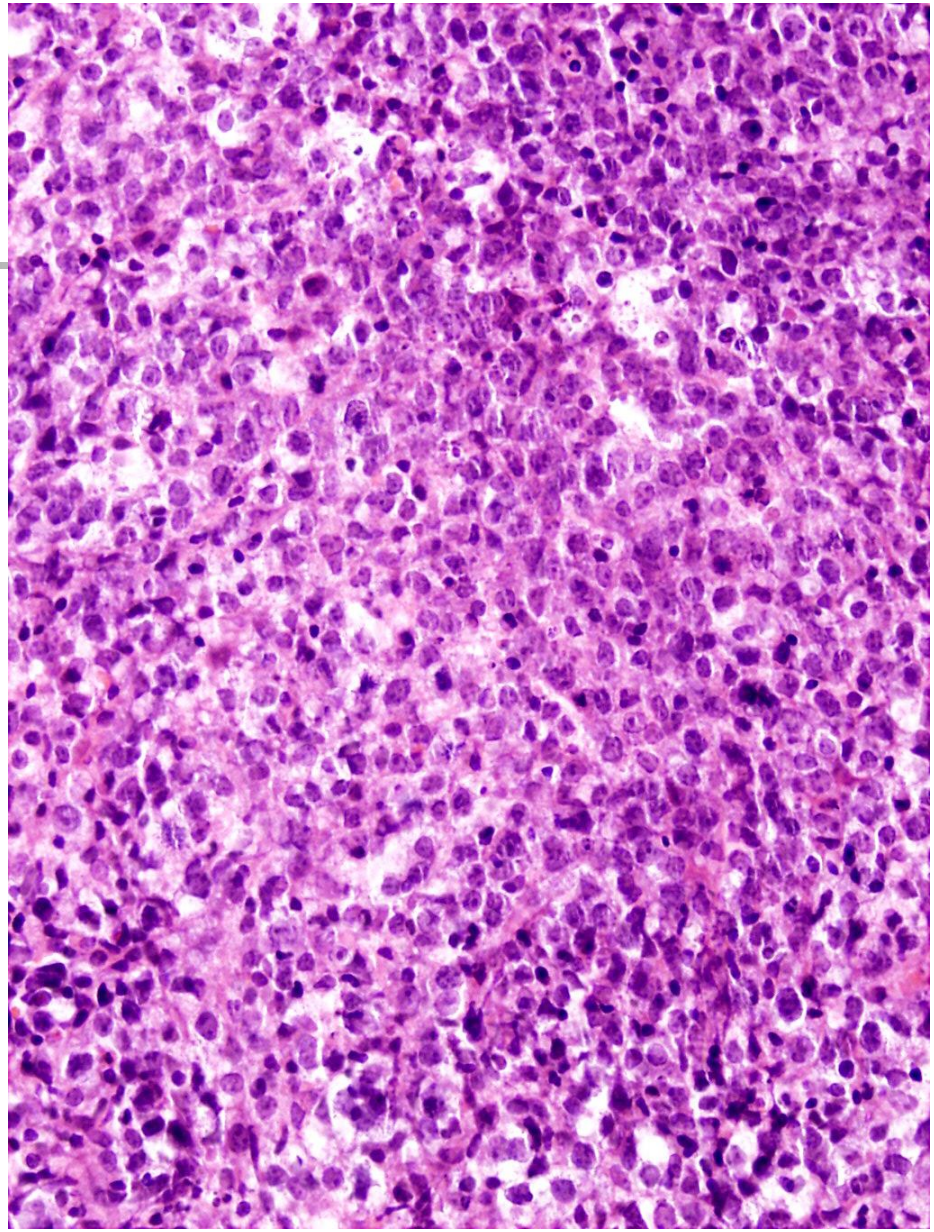

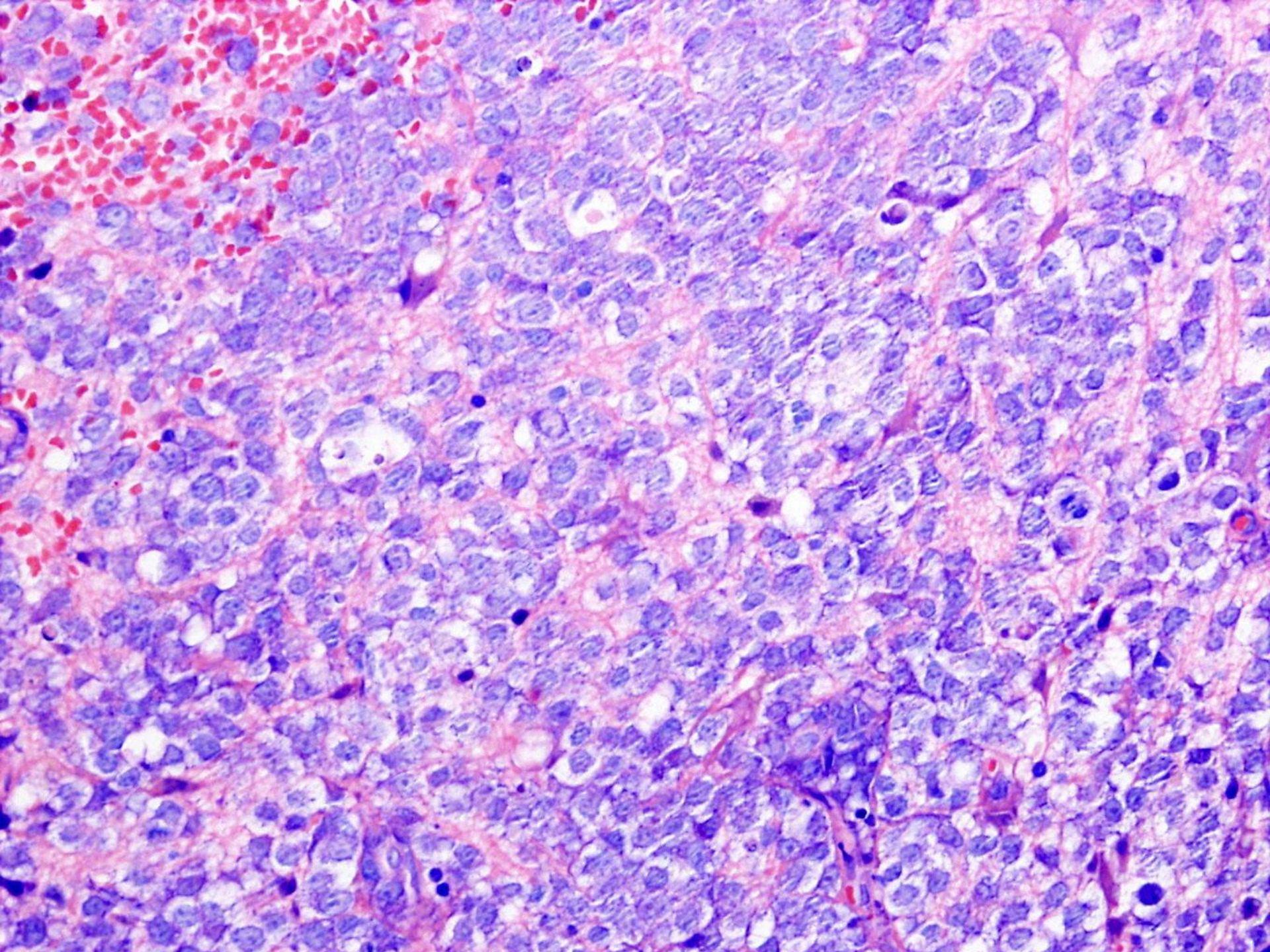

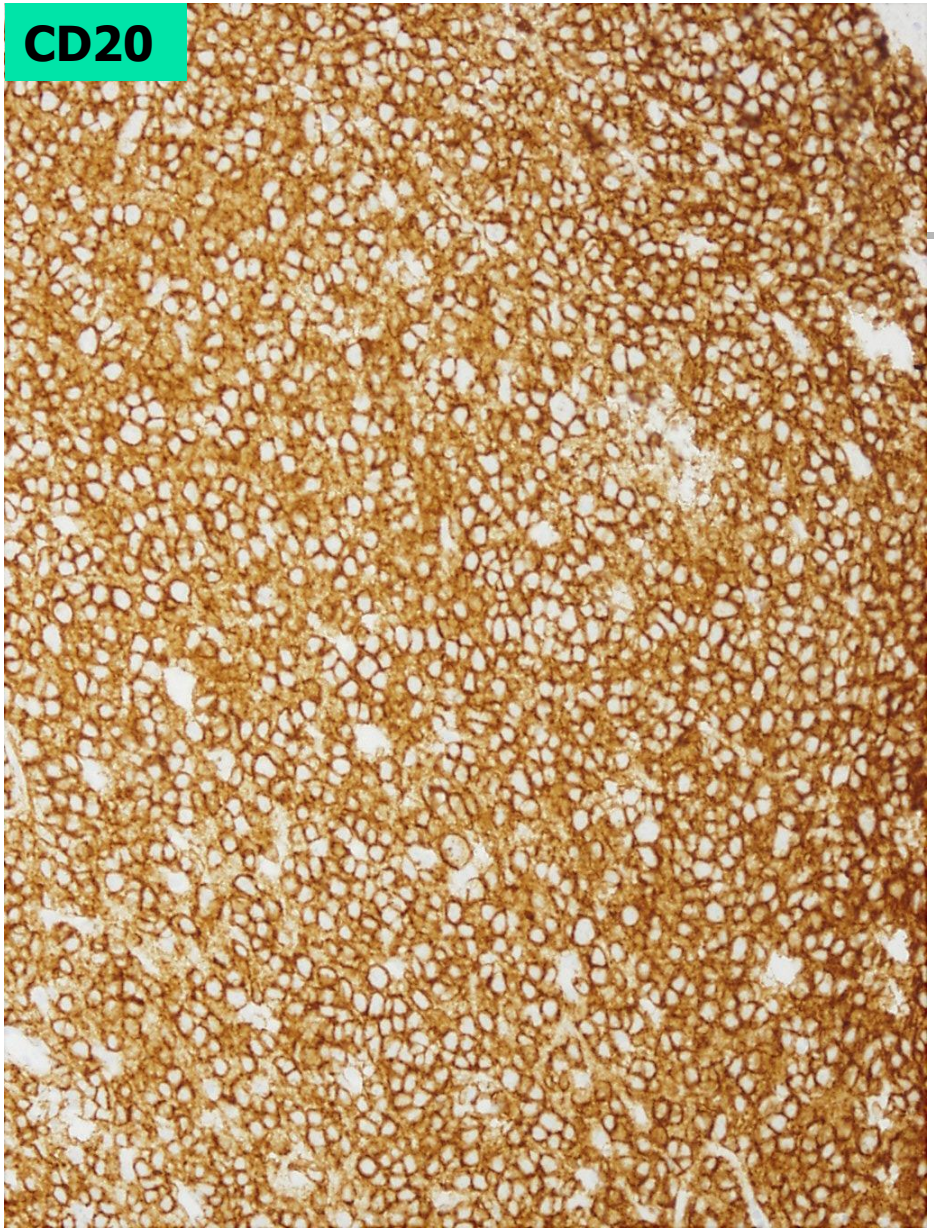
CD20

Ki67

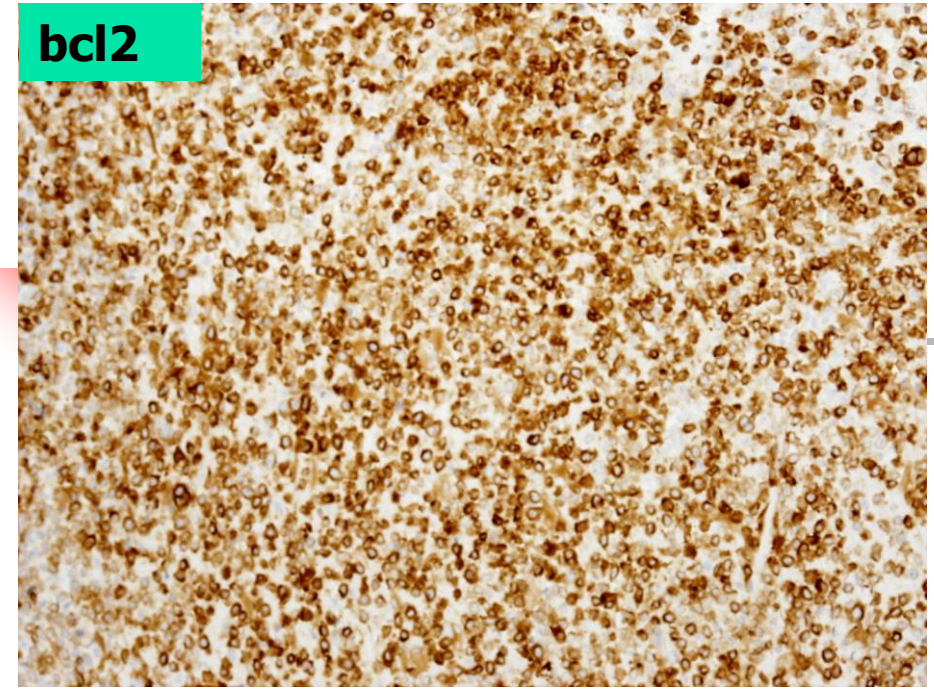
bcl2

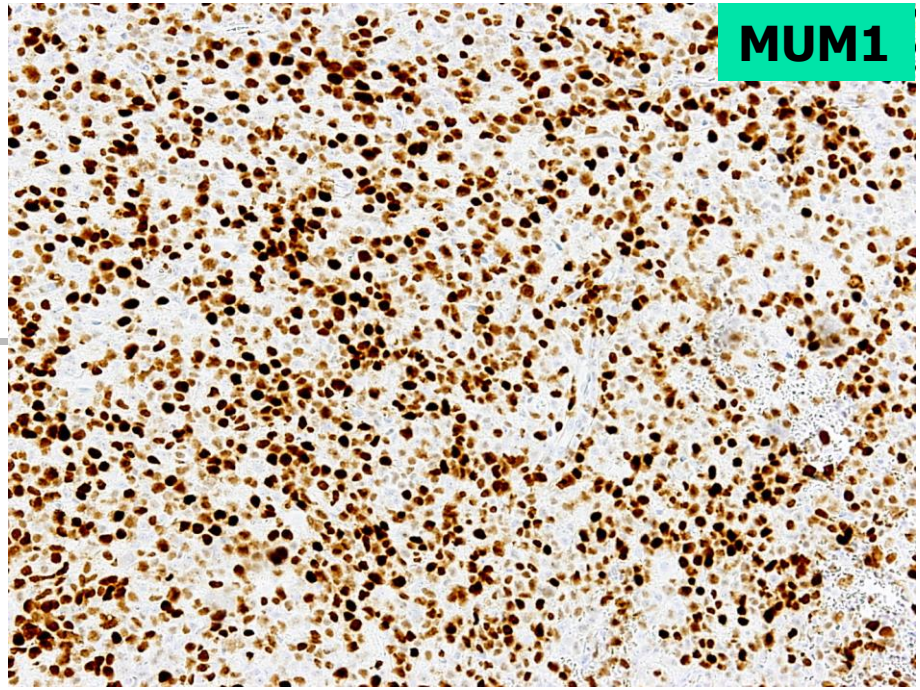
MUM1

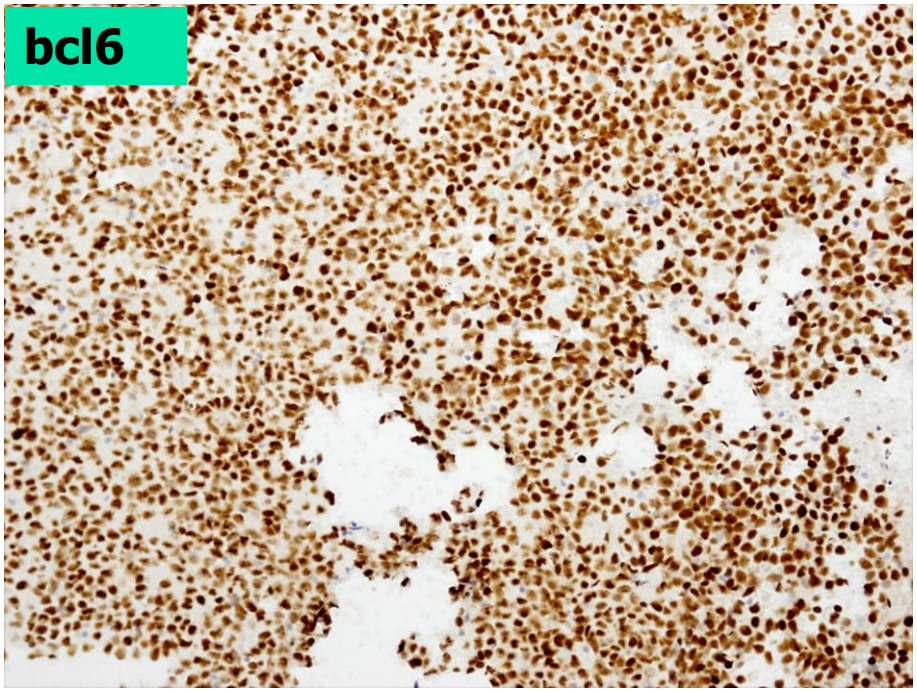
bcl6

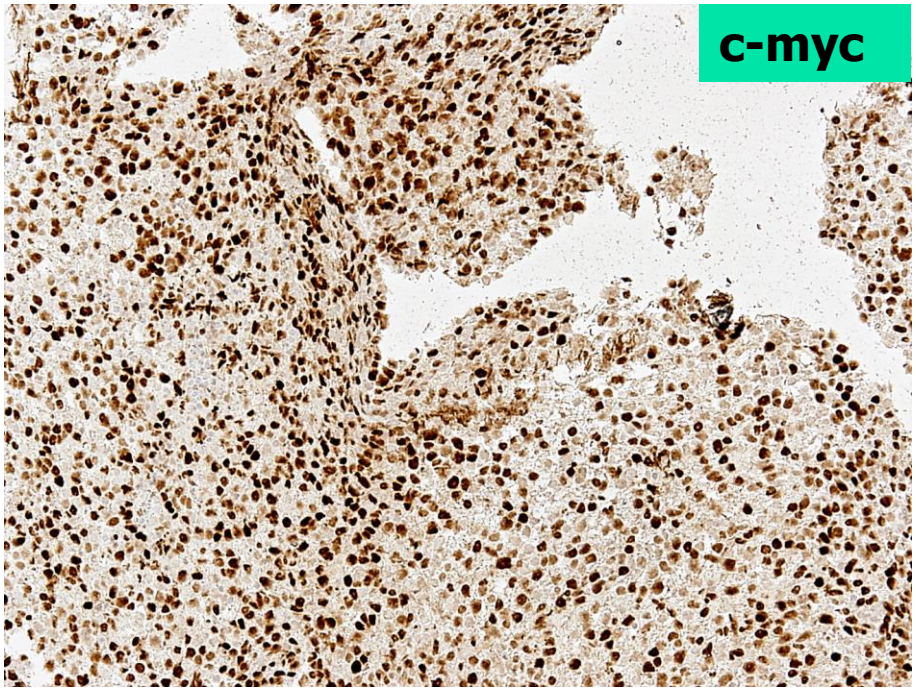
c-myc

Imunoprofil:

- Pozitivita:

  CD20, bcl2, bcl6 (cca 80-90% buniek), MUM1 (cca 60-70% buniek), c-myc (60% buniek), MIB 80-90%

- Negativita:

  CD5, CD10, CD30

Z á v e r :

Blastický, v.s. multifokálny B-NHL zo spektra DLBCL (NOS), centroblastový variant, non-GCB typ, ktorý favorizuje dg. primárneho DLBCL CNS (PCNSL) s fenotypom tzv. "tripple expressora" (bcl6+/bcl2+/c-myc+).

Prípad č.7

- muž, 37 rokov
- viacpočetný Tu proces v mozgu
- konzultácia BB Biocyt

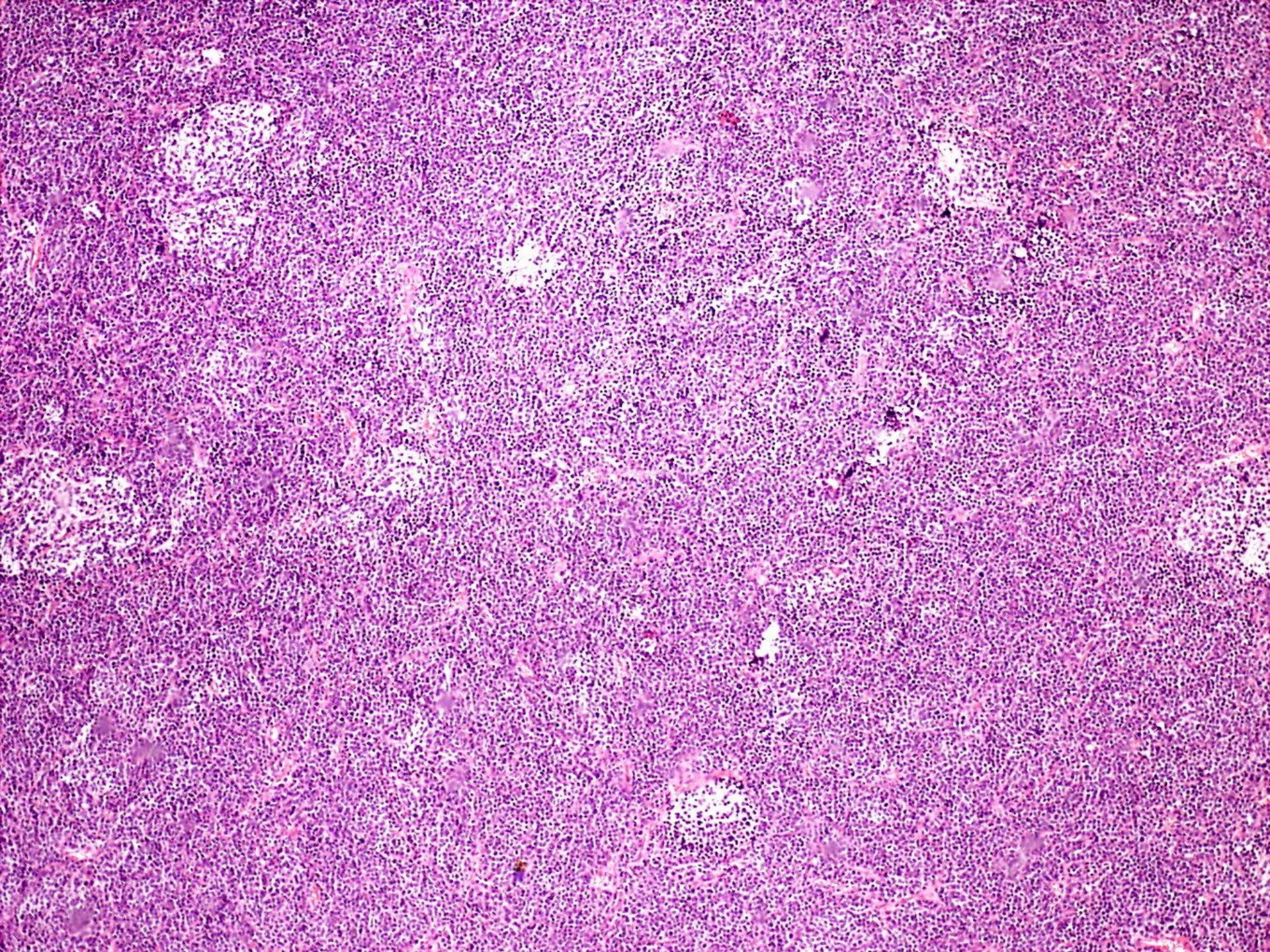

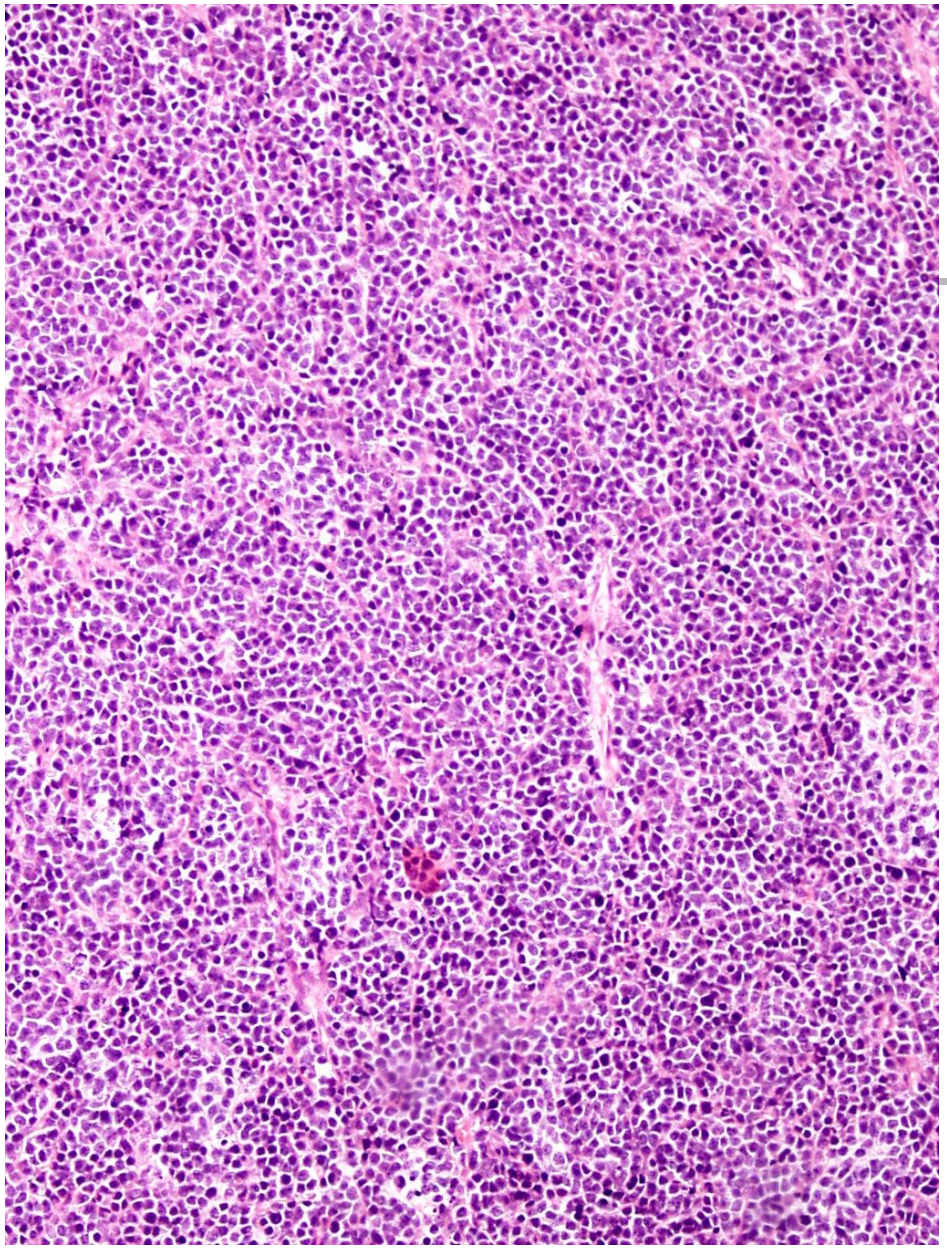

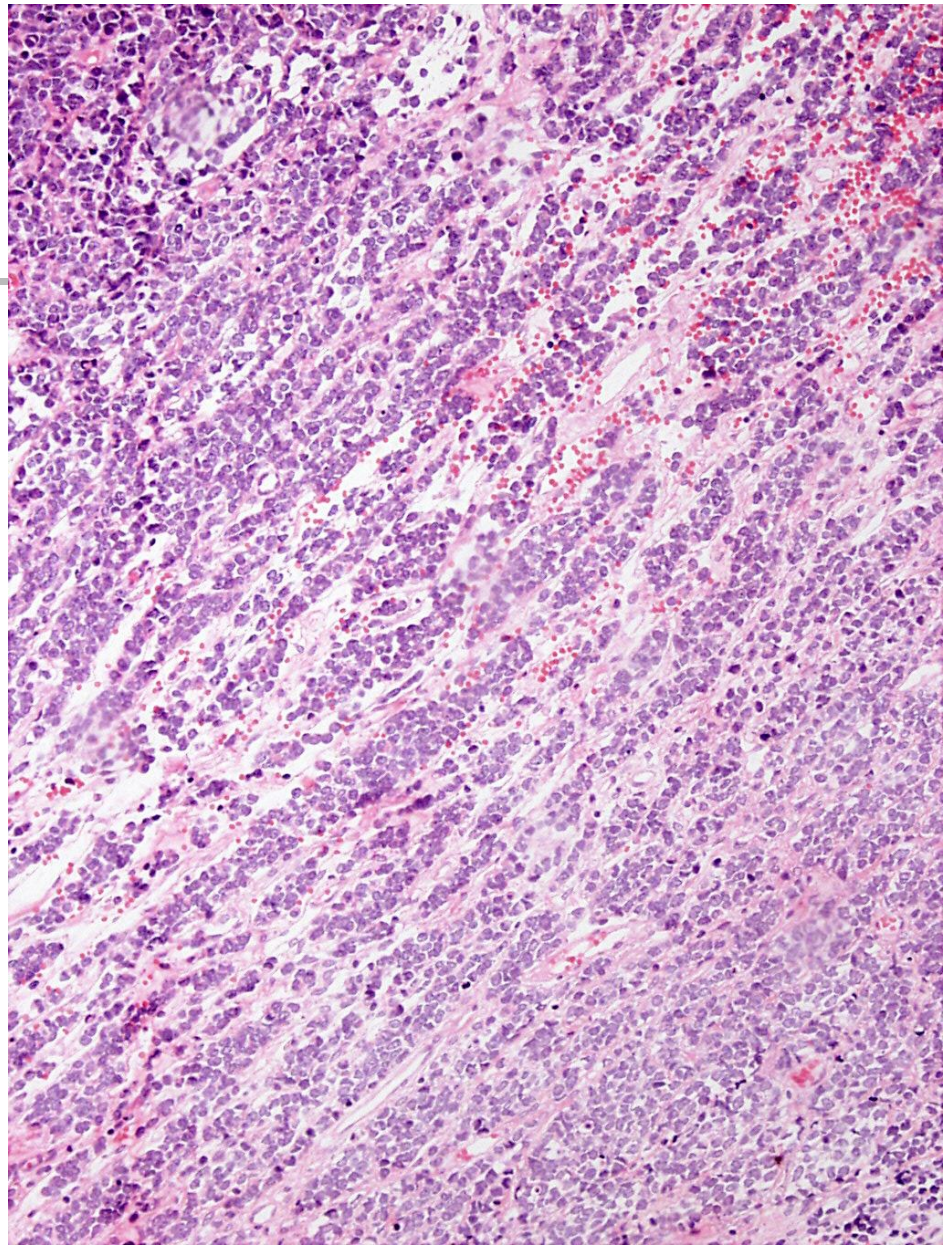

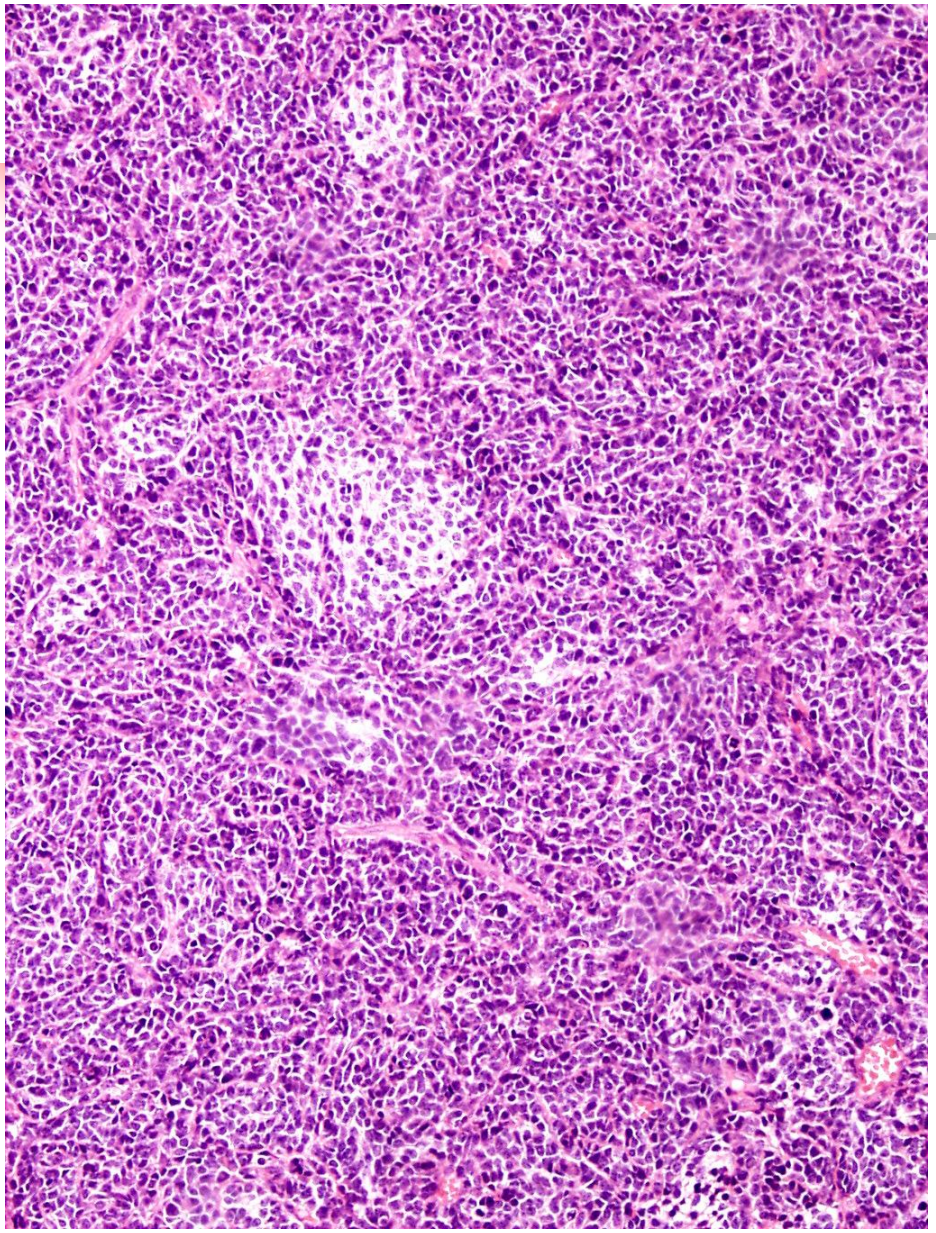

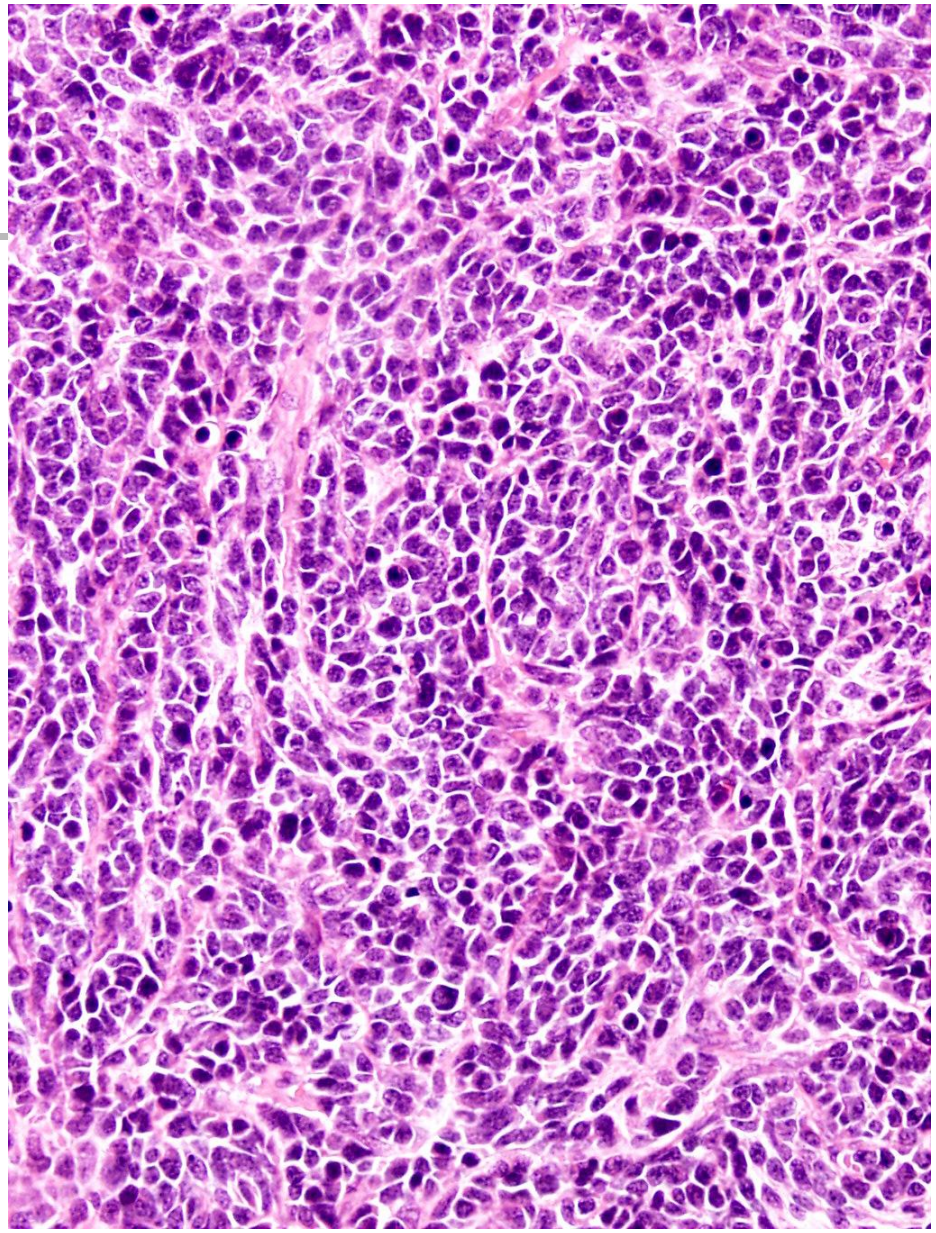

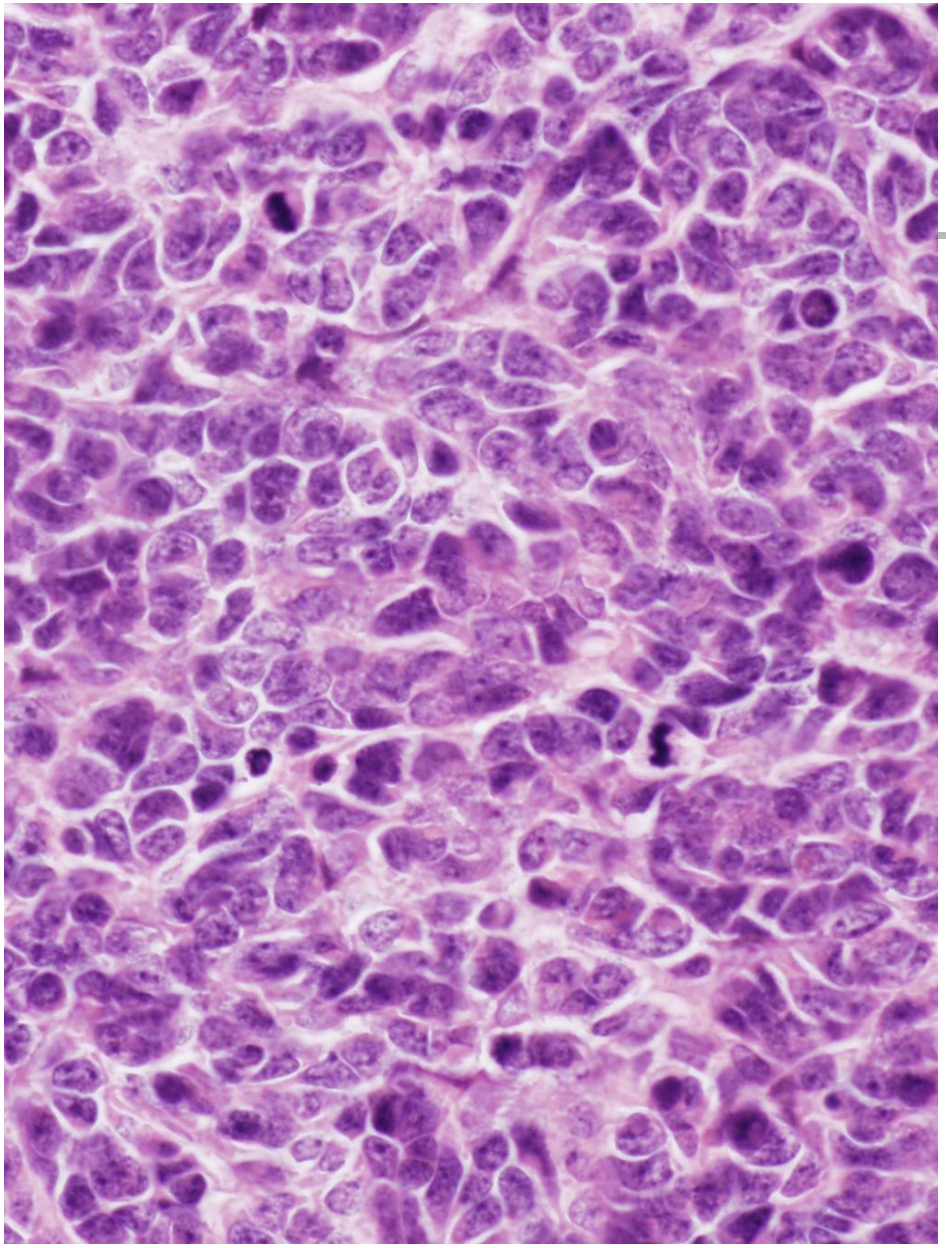

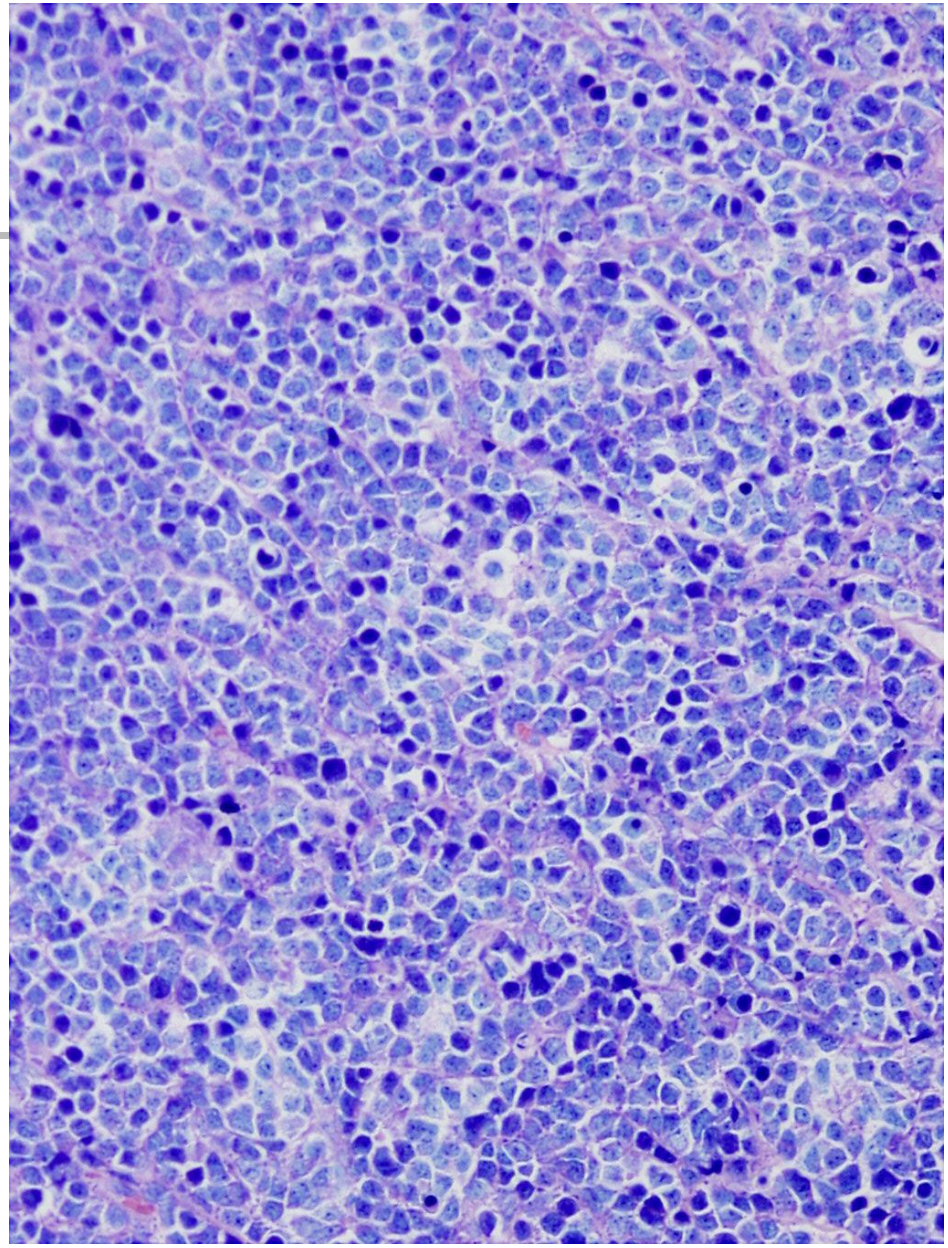

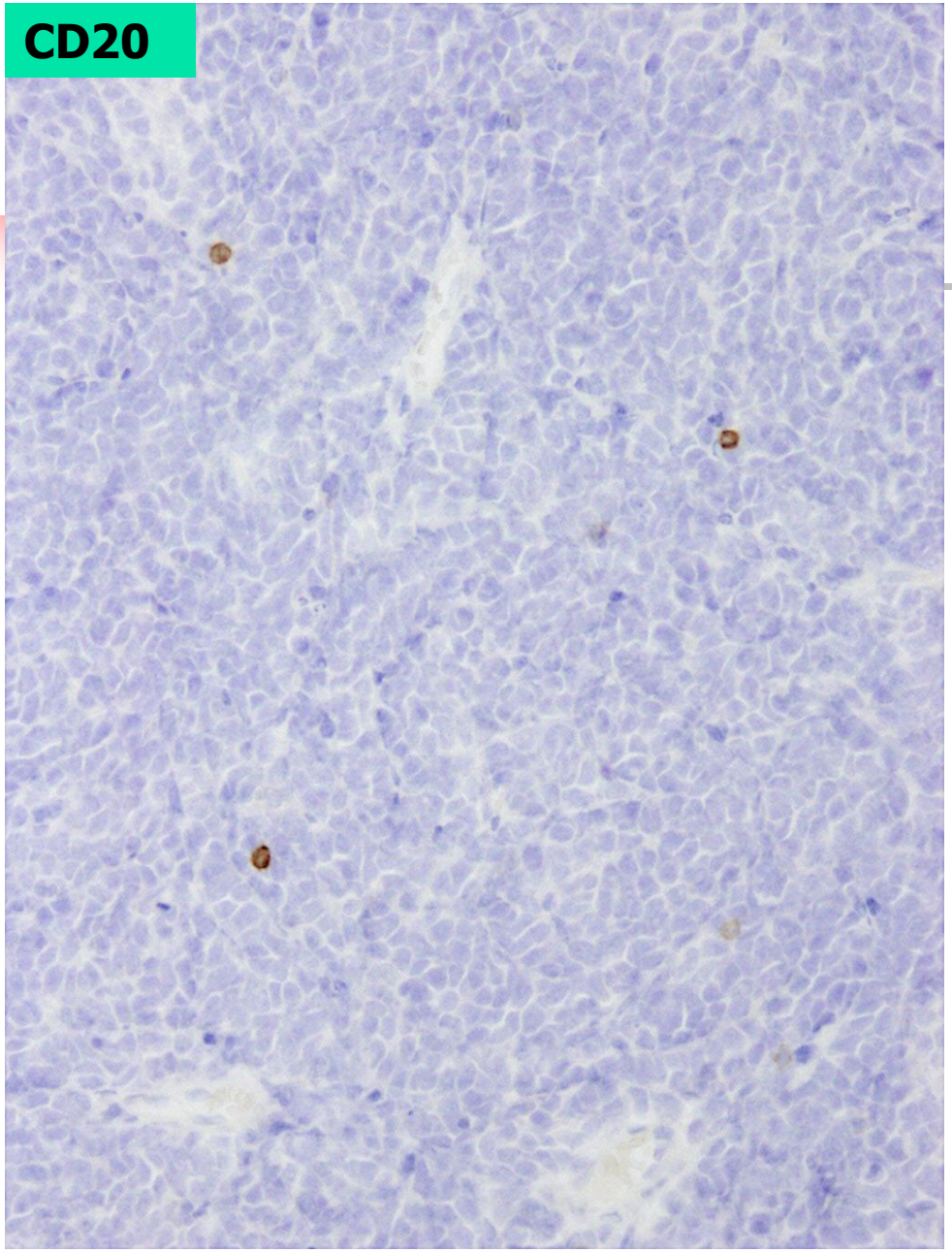
CD20

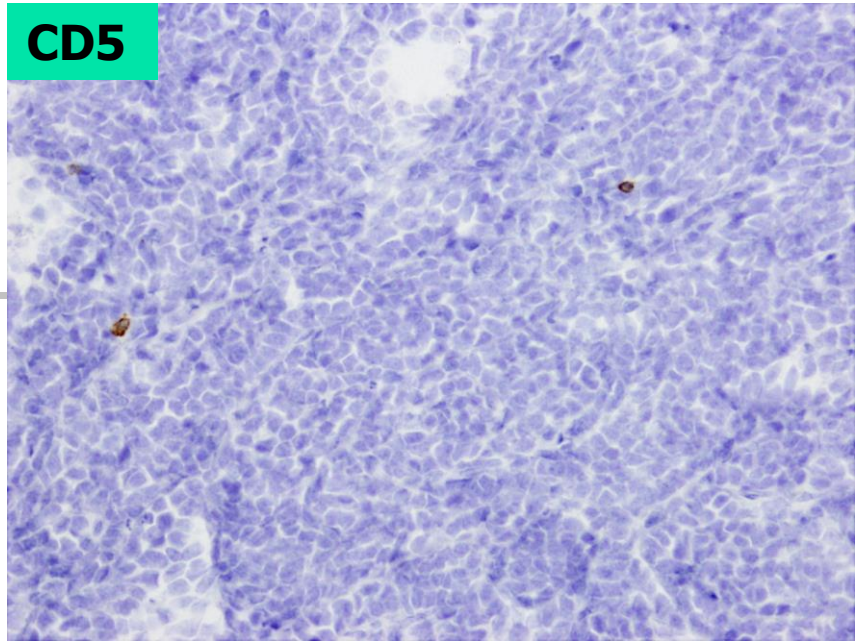
CD5

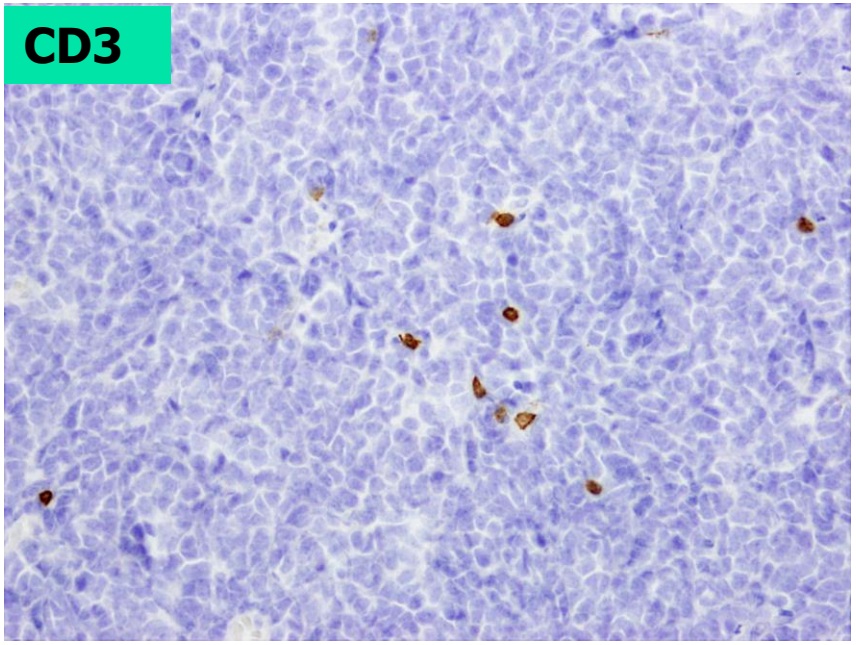
CD3

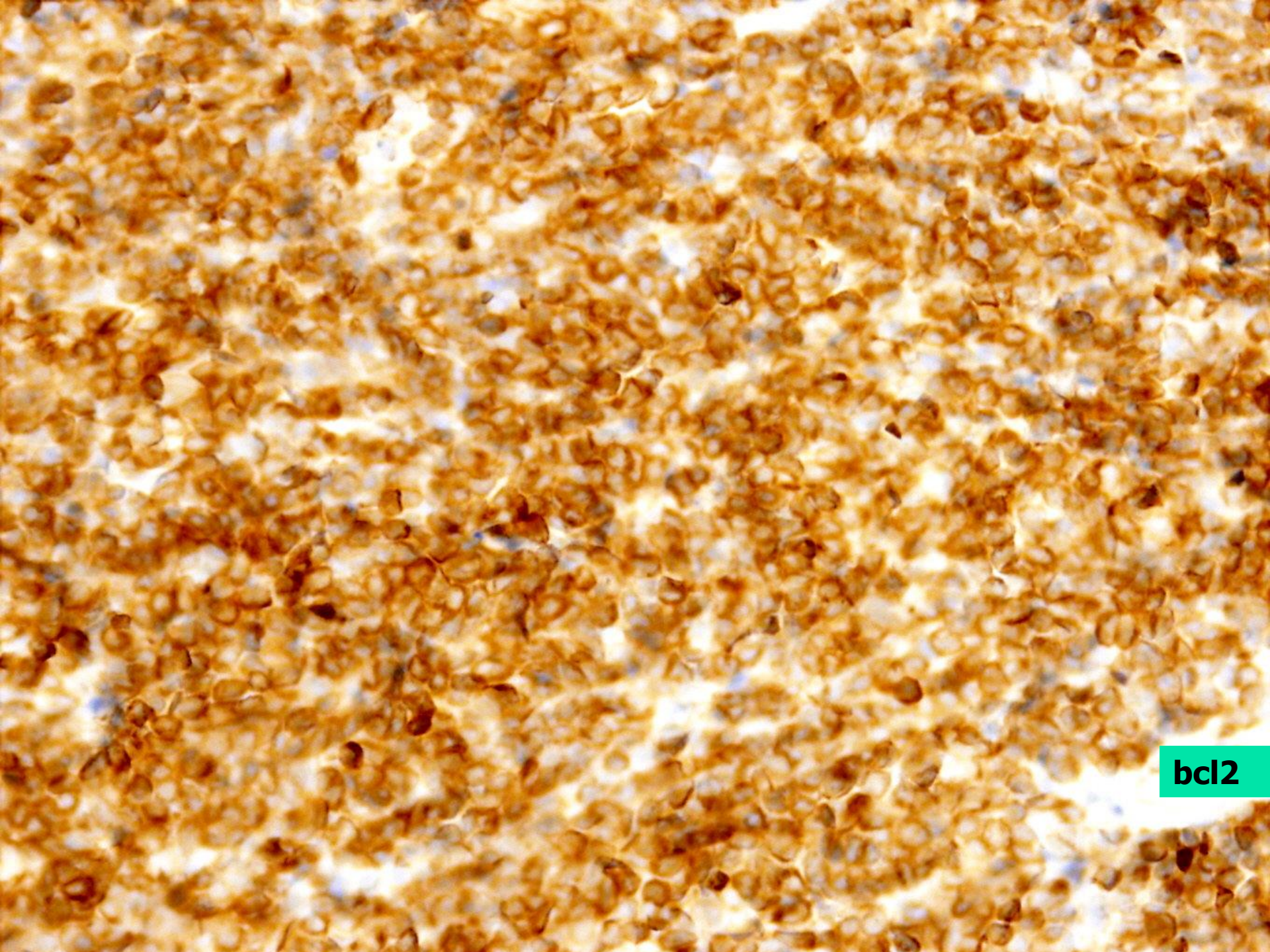
bcl2

Imunoprofil:

- Pozitivita:

  (CD45 ?!), bcl2,

- Negativita:

  CD20, CD79a, CD3, CD5, CD10, *(CK, EMA, NF, CD99, GFAP, chromogranín A)*

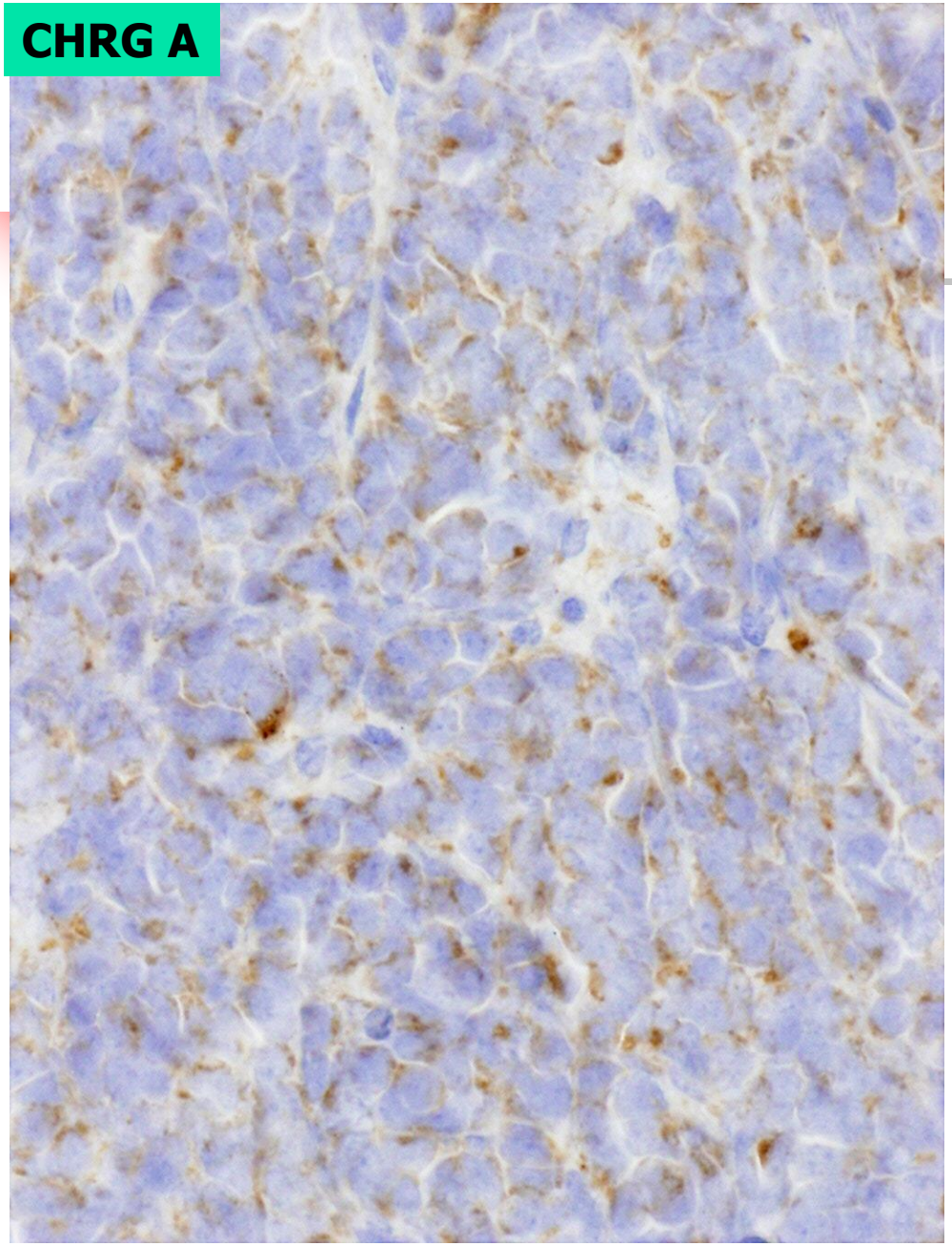
CHRG A

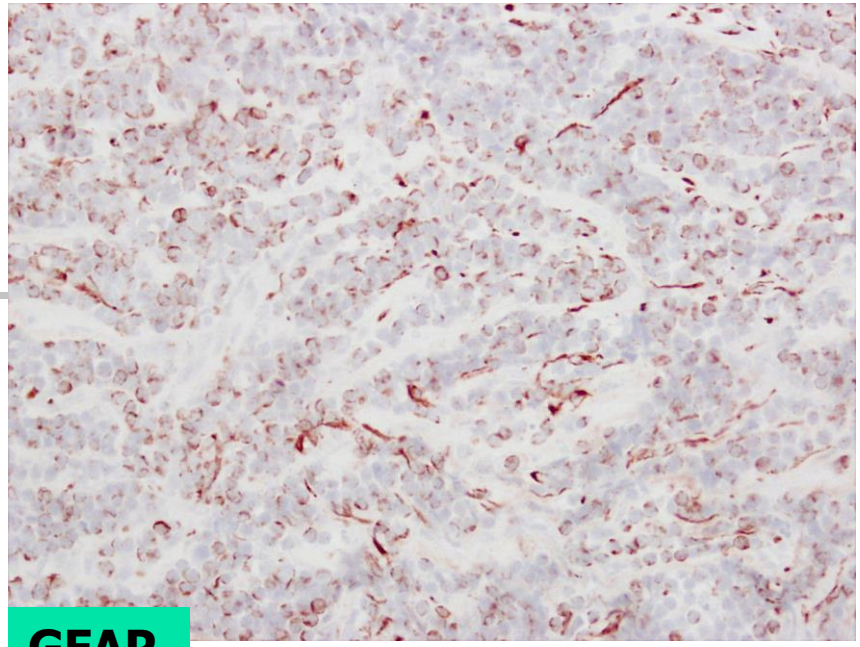

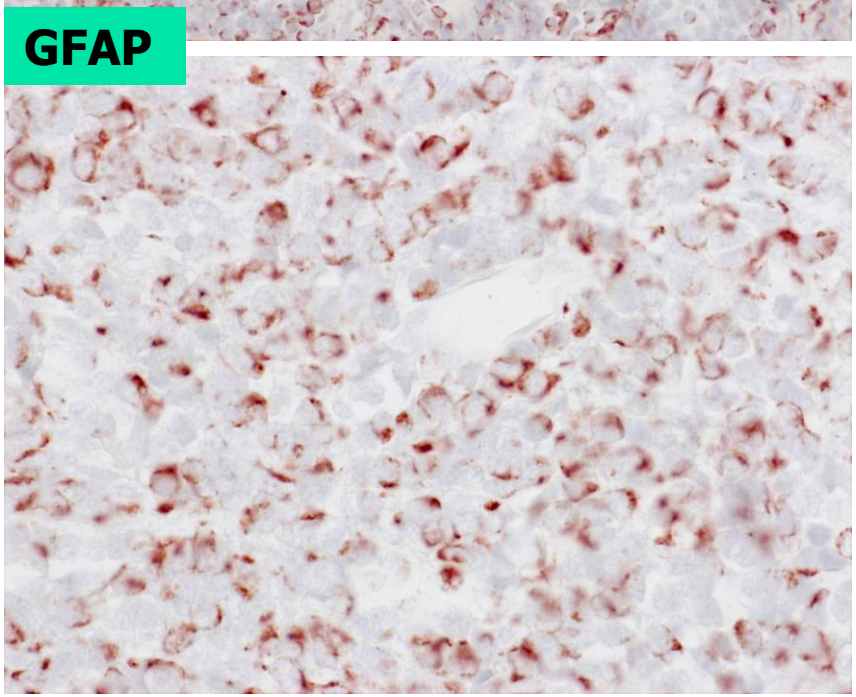
GFAP

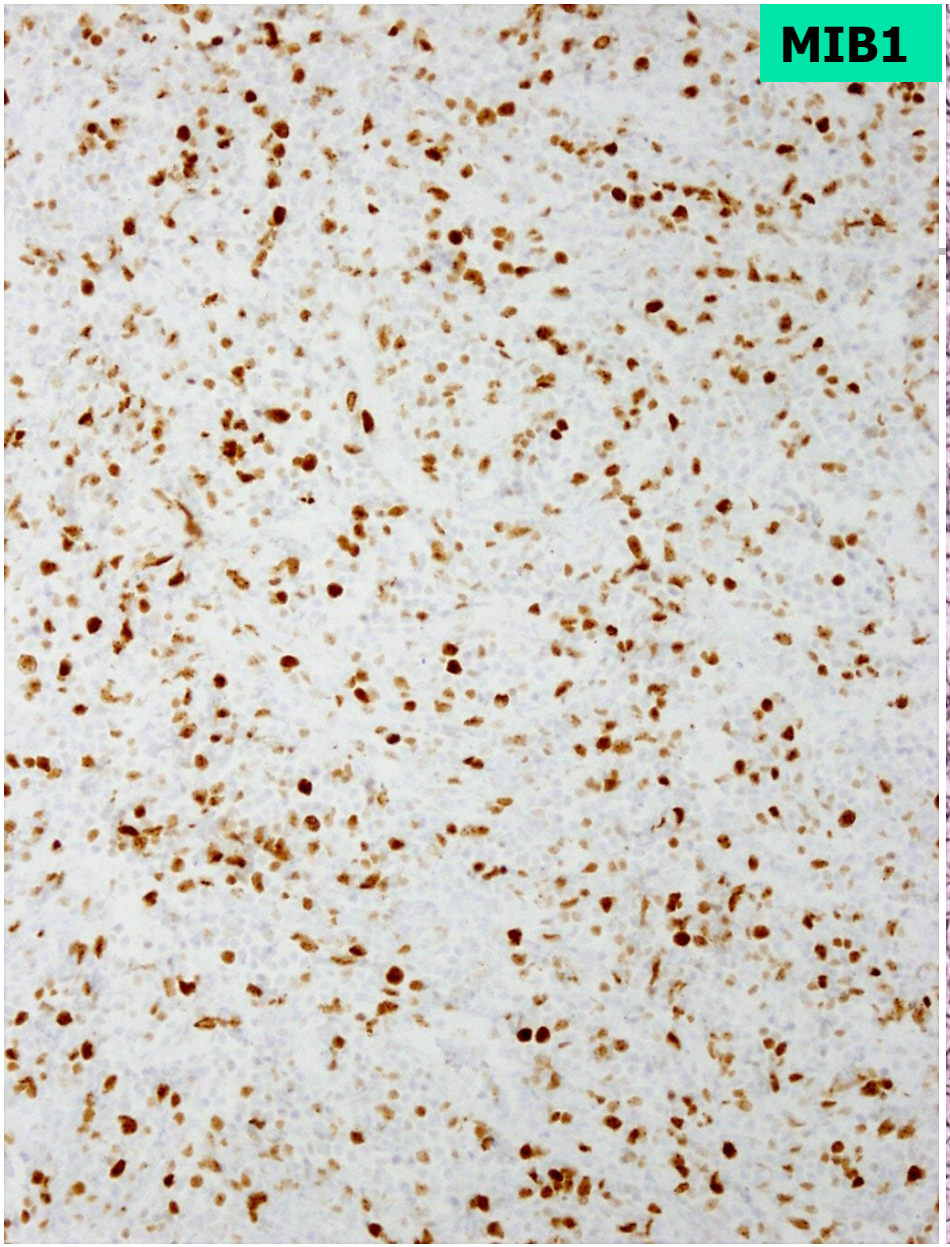
MIB1

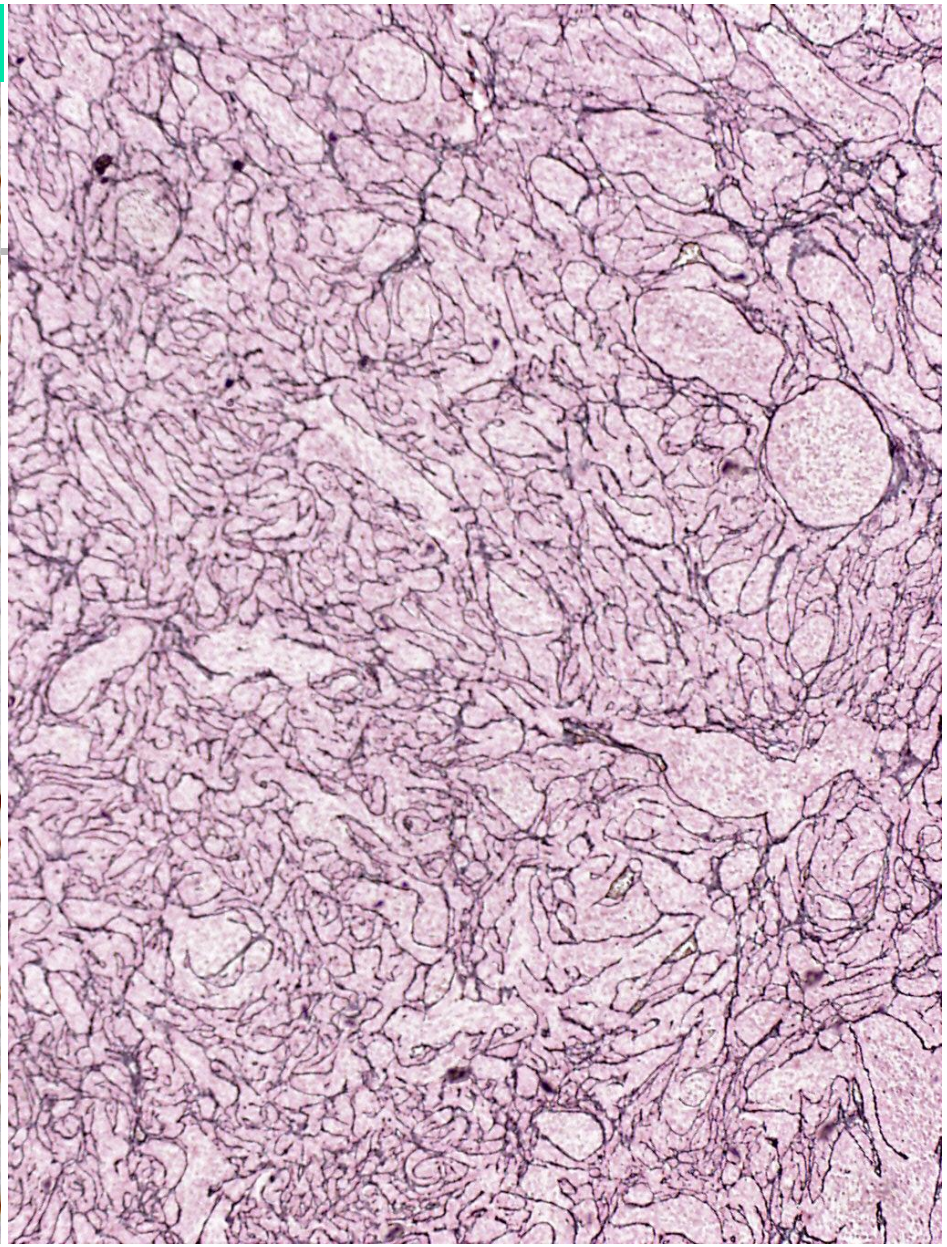

Imunoprofil:

- Pozitivita:

  (CD45 ?!), bcl2, NSE, chromogranín A, synaptofyzín, GFAP fokálne, MIB1 30-40%

- Negativita:

  CD20, CD79a, CD3, CD5, CD10, *(CK, EMA, NF, CD99, GFAP, chromogranín A)*

Záver:

Nejde o Vami zvažovaný lymfóm, ale o nádor z malých modrých buniek zo spektra meduloblastómu (G4), a to jeho nodulárny alebo dezmoplastický variant.

Prípad č.8

- žena, 53 rokov
- pacientka s anamnézou bolesti hlavy a zmenou osobnosti absolvovala MR mozgu s nálezom tumor F vpravo, v.s. gliom resp. meningeóm
- operovaná - realizovaná radikálna exstirpácia, jednalo sa o intraaxiálny Tu
- konzultácia Cytopathos, BA

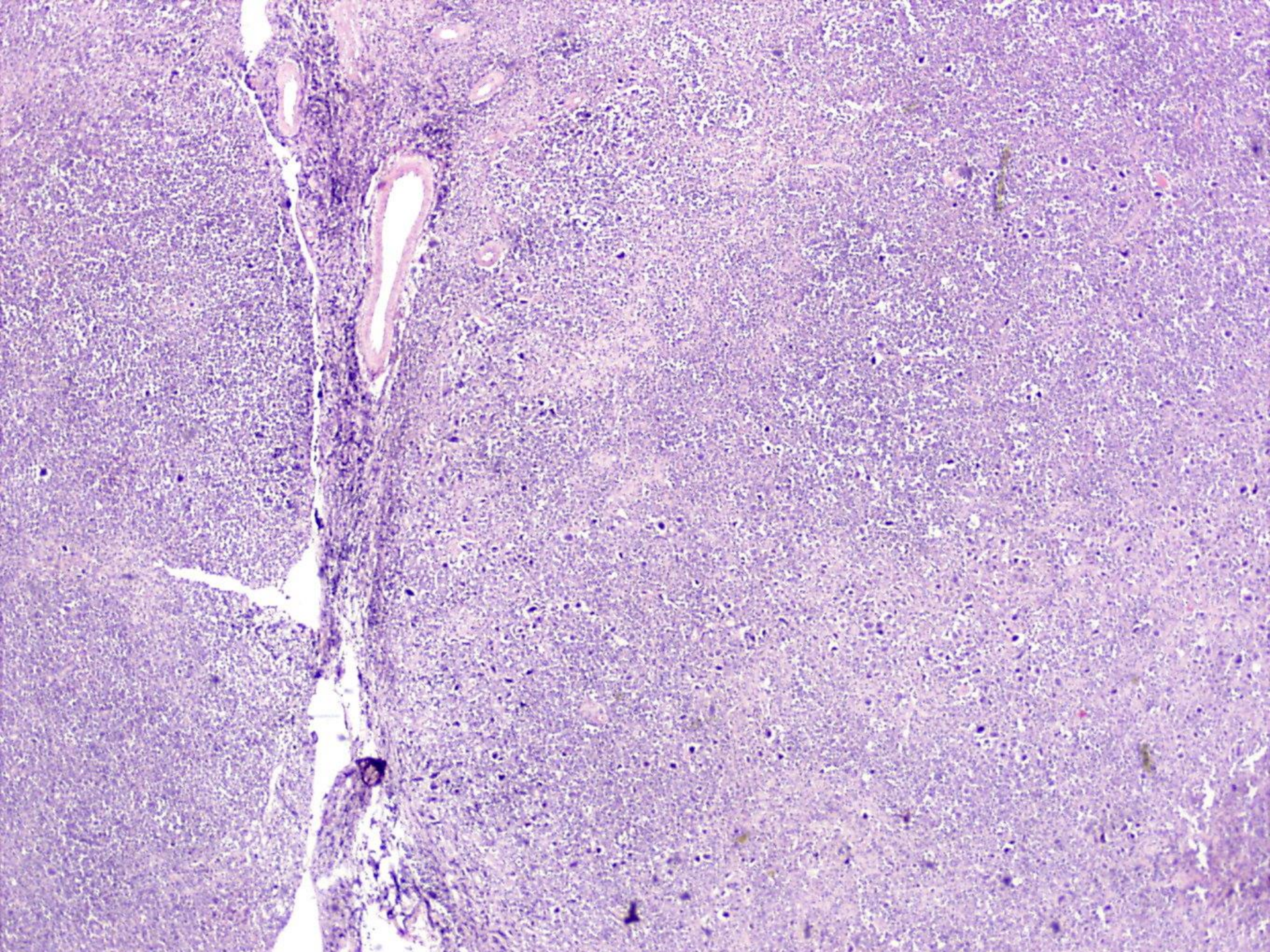

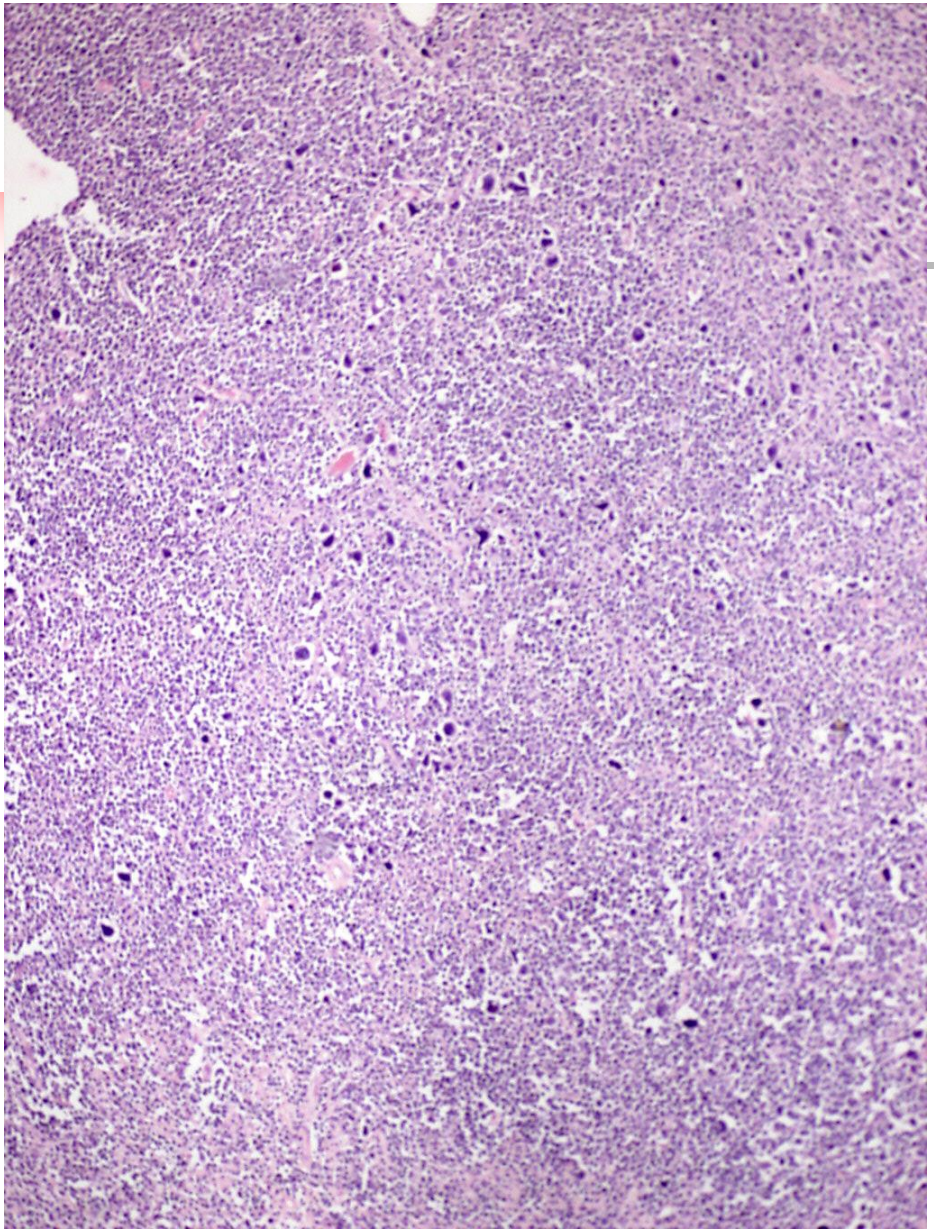

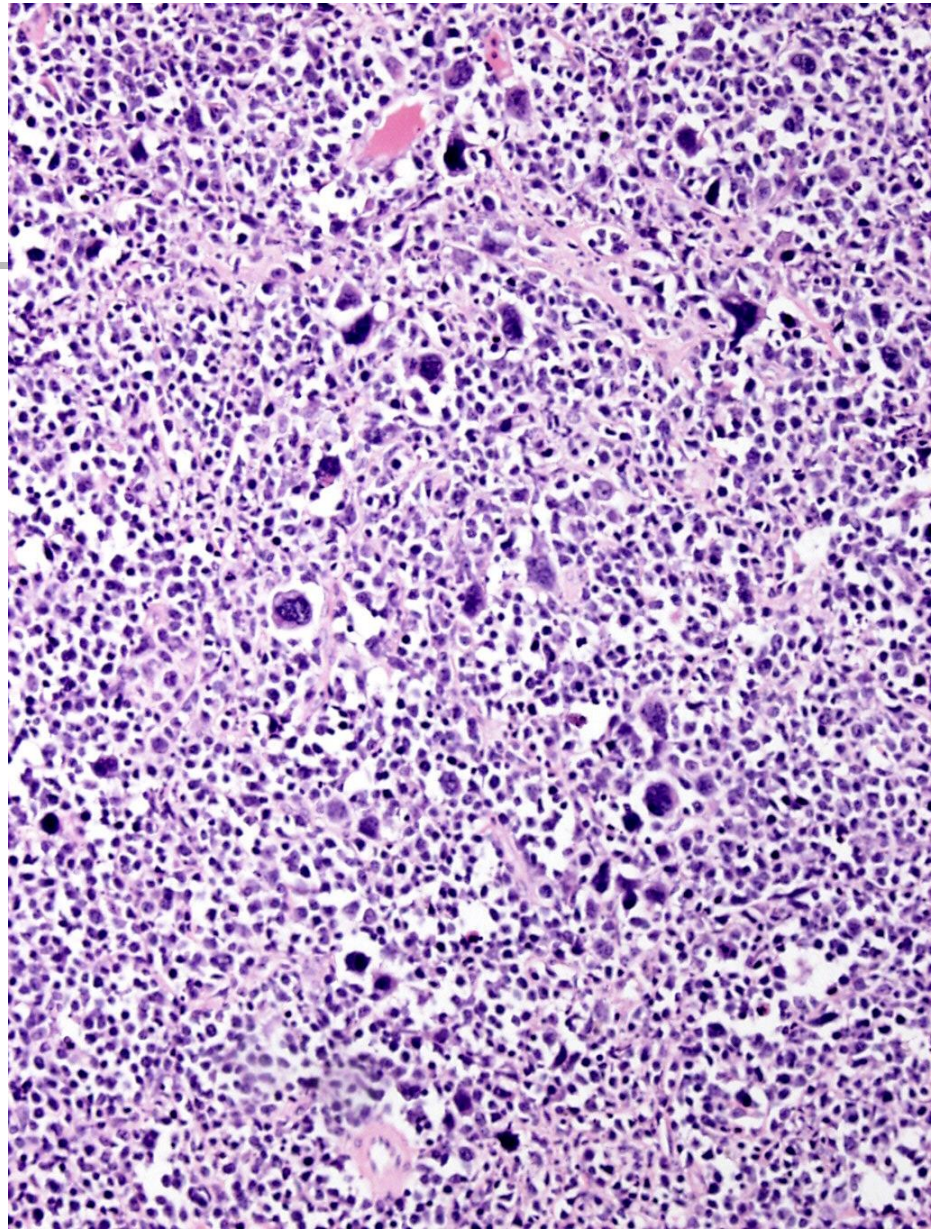

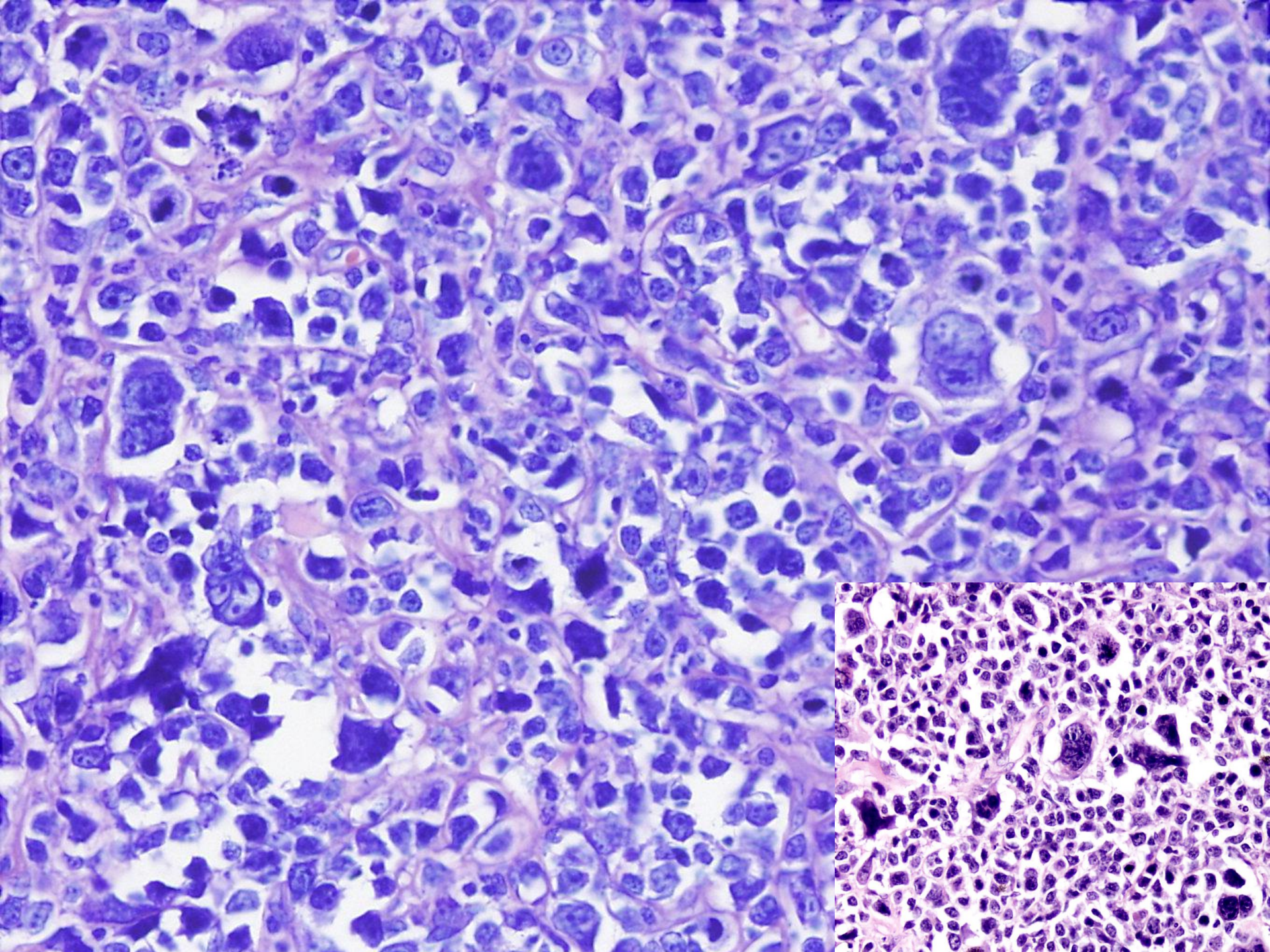

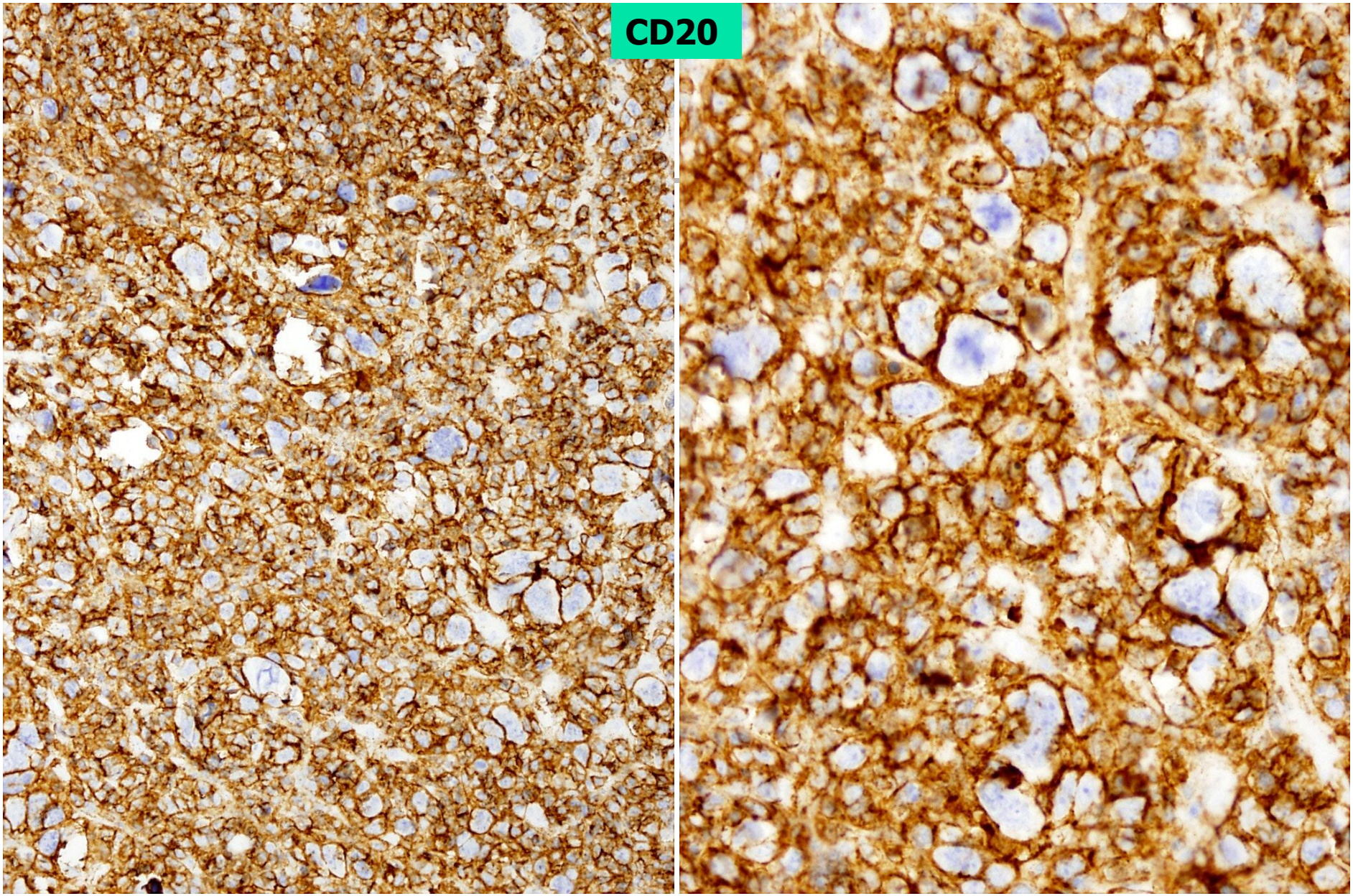
CD20

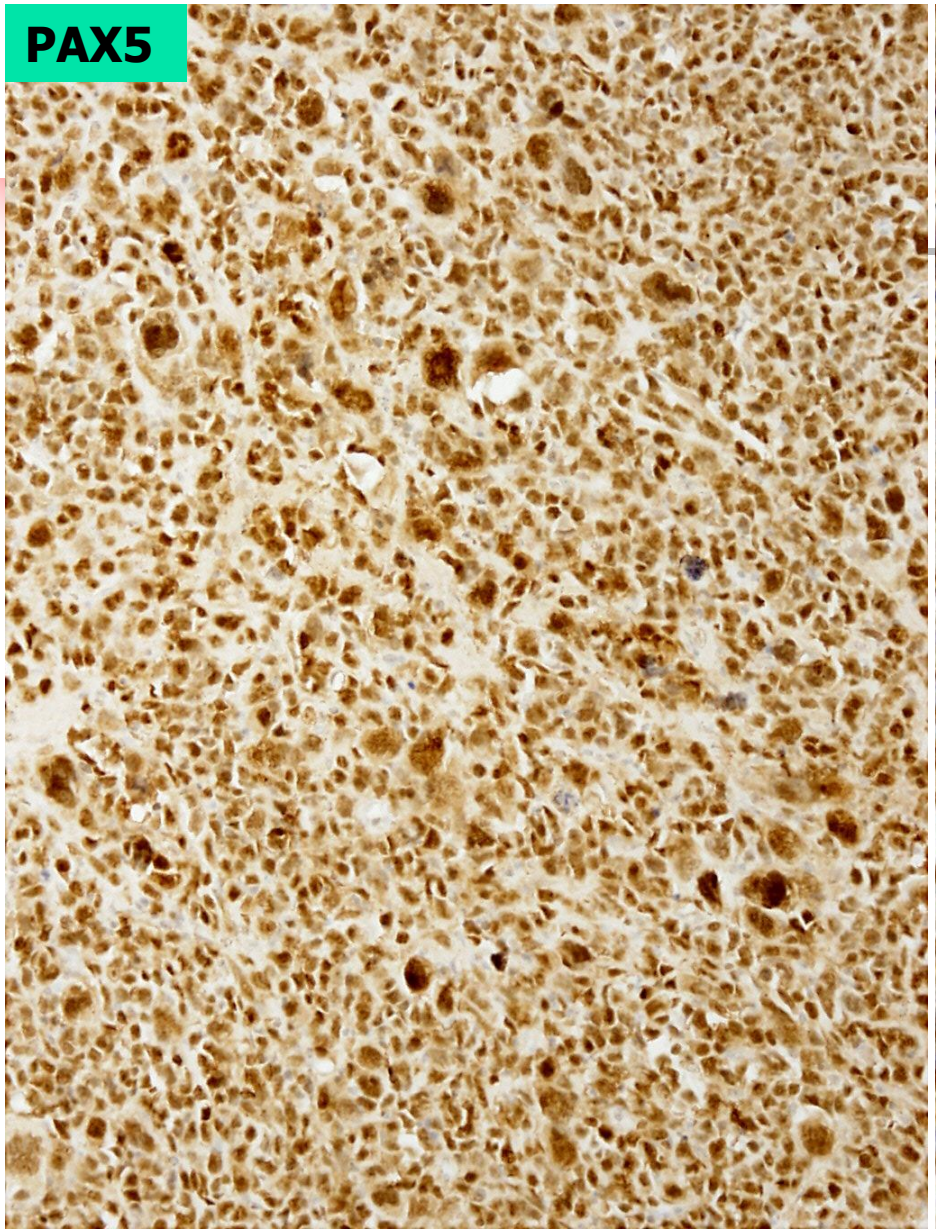
PAX5

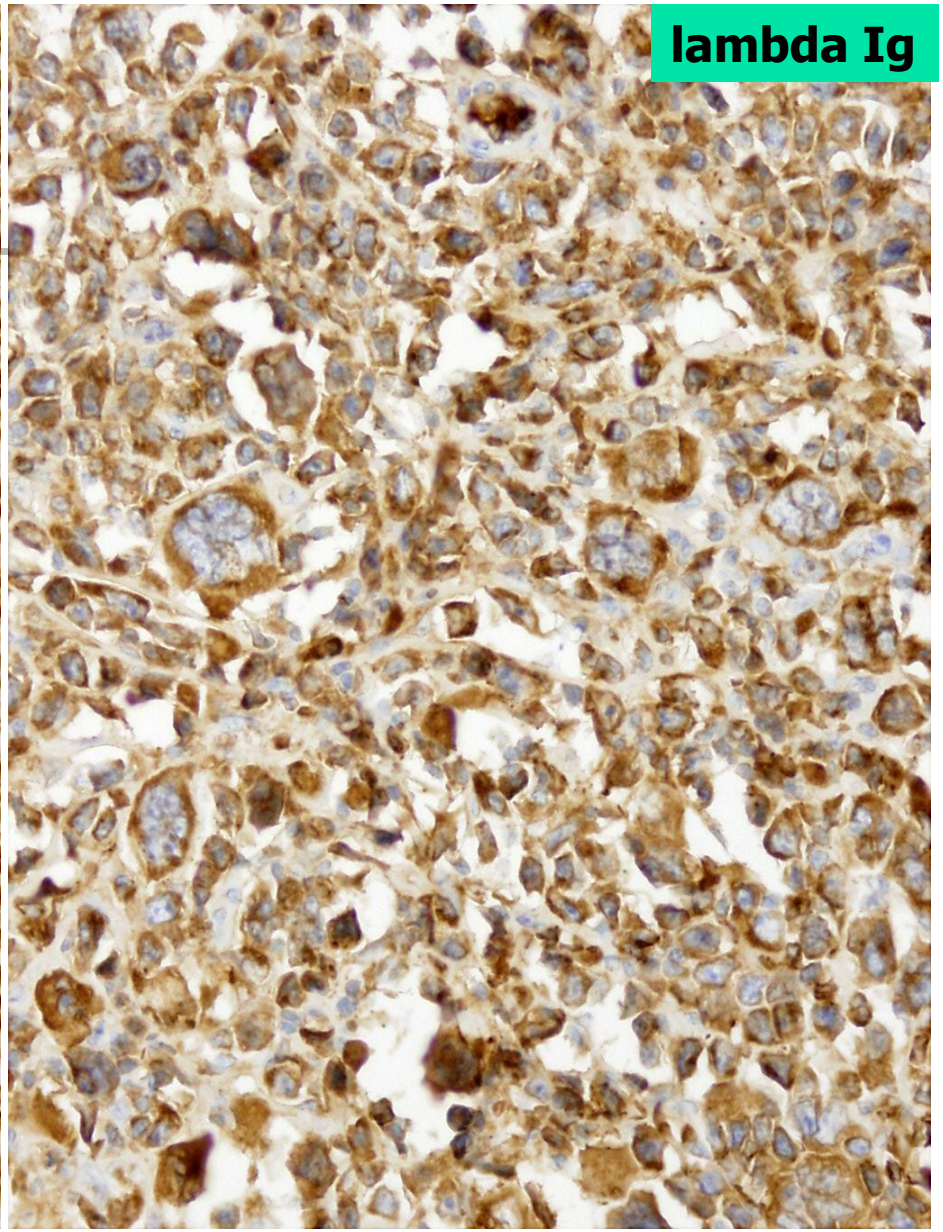
lambda Ig

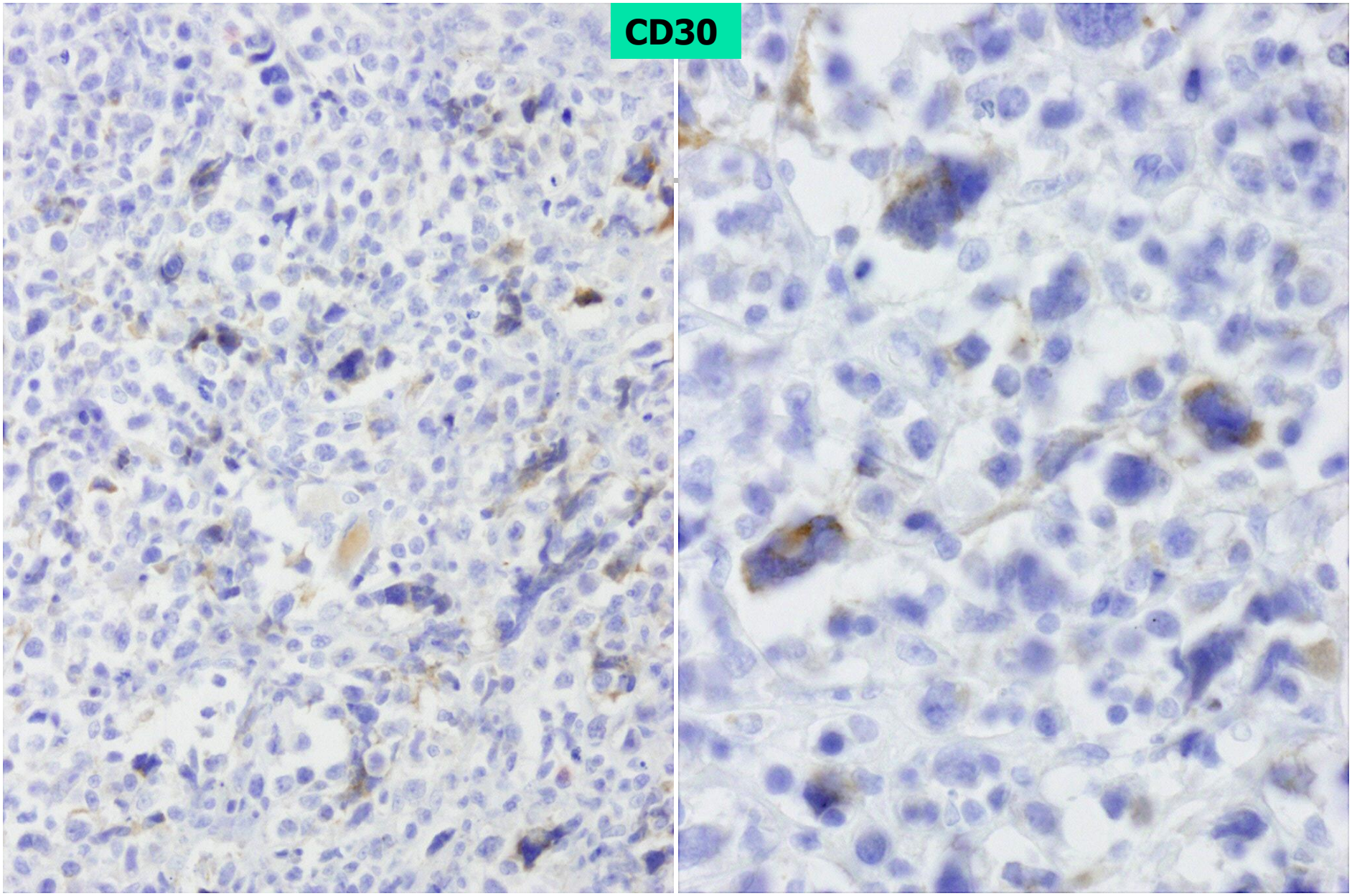
CD30

Imunoprofil:

- Pozitivita:

  CD20, PAX5, bcl2, bcl6, CD30 pozitivita paranukleárneho typu v ojedinelých SR-like obrovských viacjadrových bunkách, monotypický Ig typu lambda, MIB1 80%

- Negativita: CD3, CD10, CD30

Záver:

Blastický B-NHL zo spektra DLBCL (v.s. primárny extranodálny DLBCL CNS), morfologicky anaplastický, prevažne CD30 negatívny variant s non-GCB fenotypom.

Prípad č.9

- muž, 38 rokov
- pacient s anamnézou bolesti hlavy, zvracania, neistej chôdze, MR preukázalo solitárne ložisko cerebella
- konzultácia Cytopathos, BA

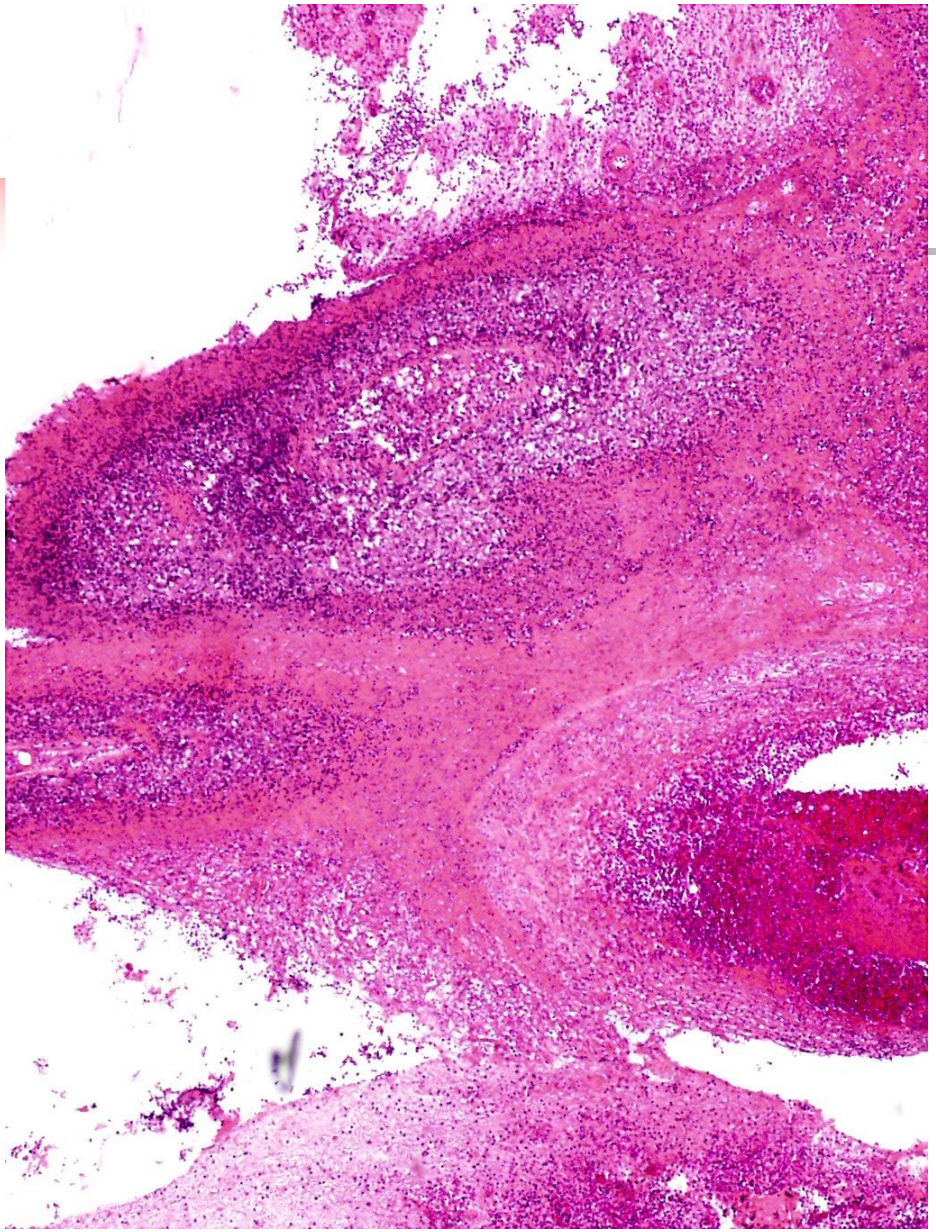

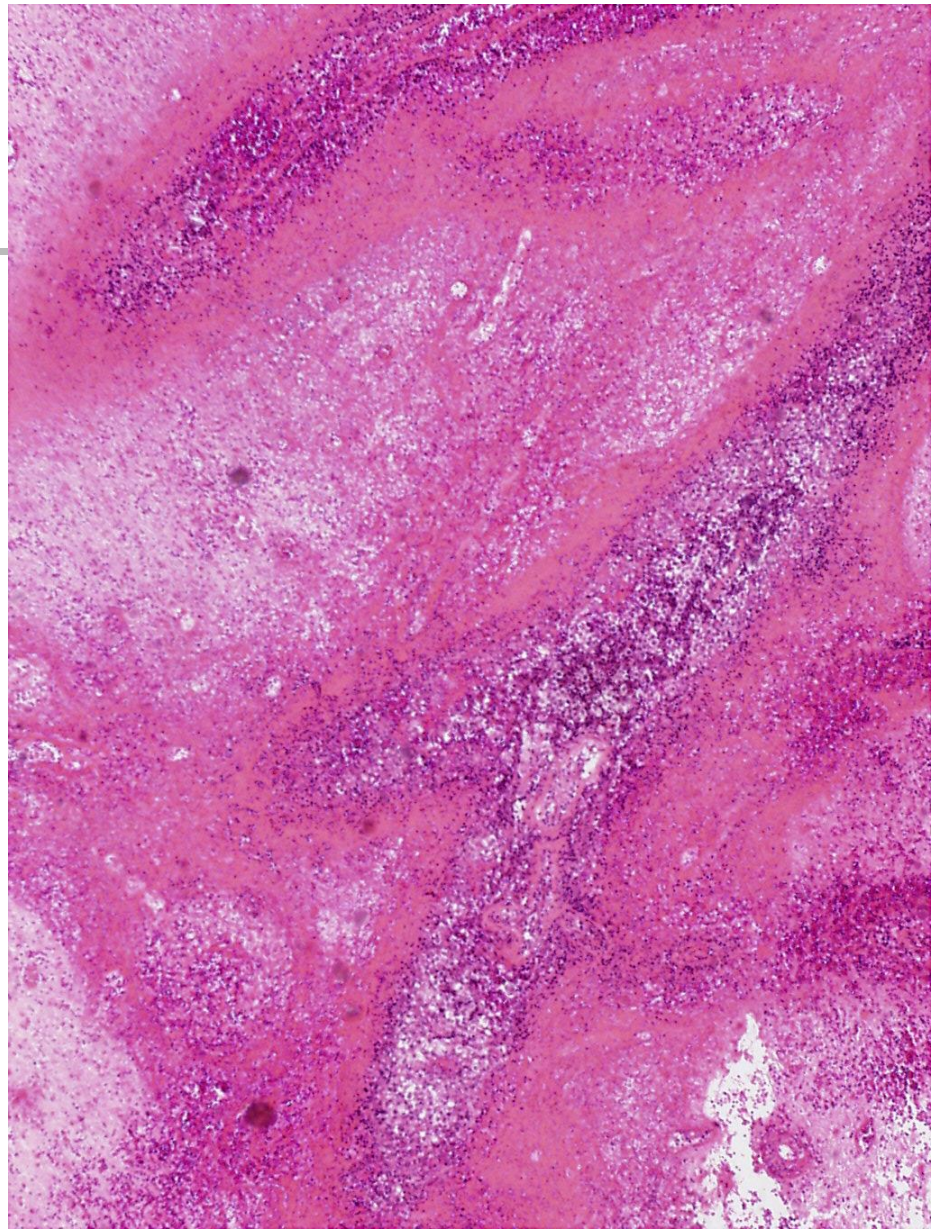

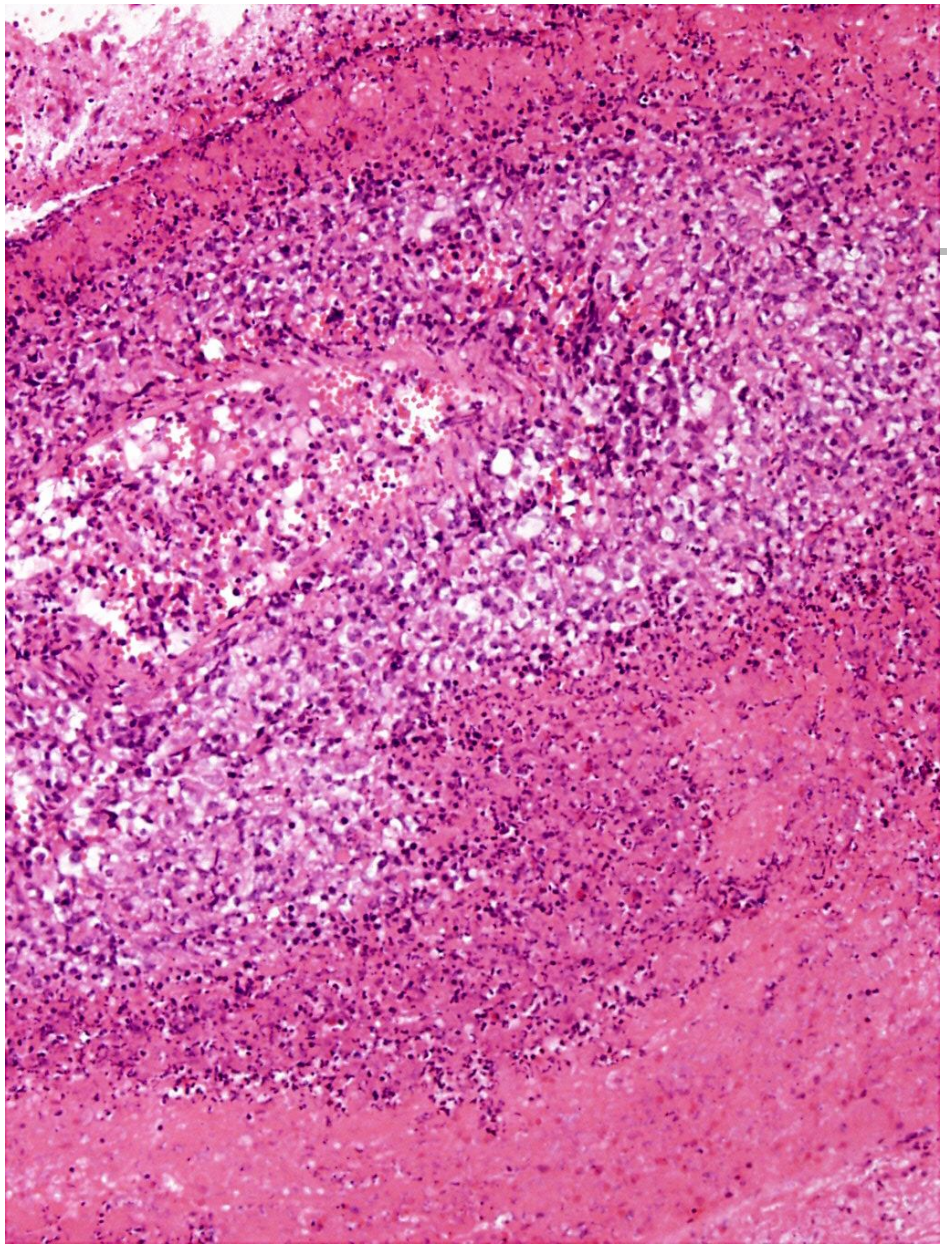

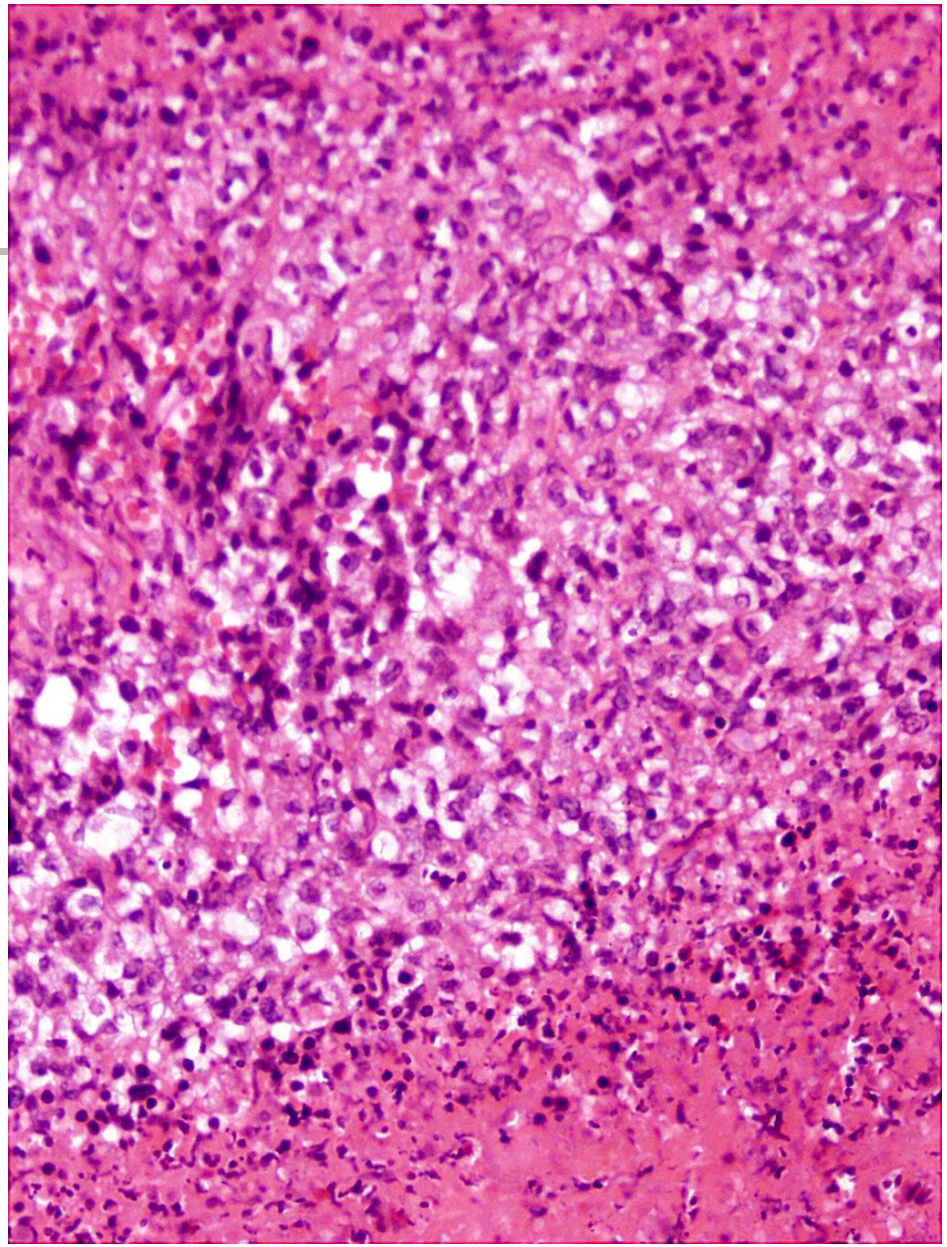

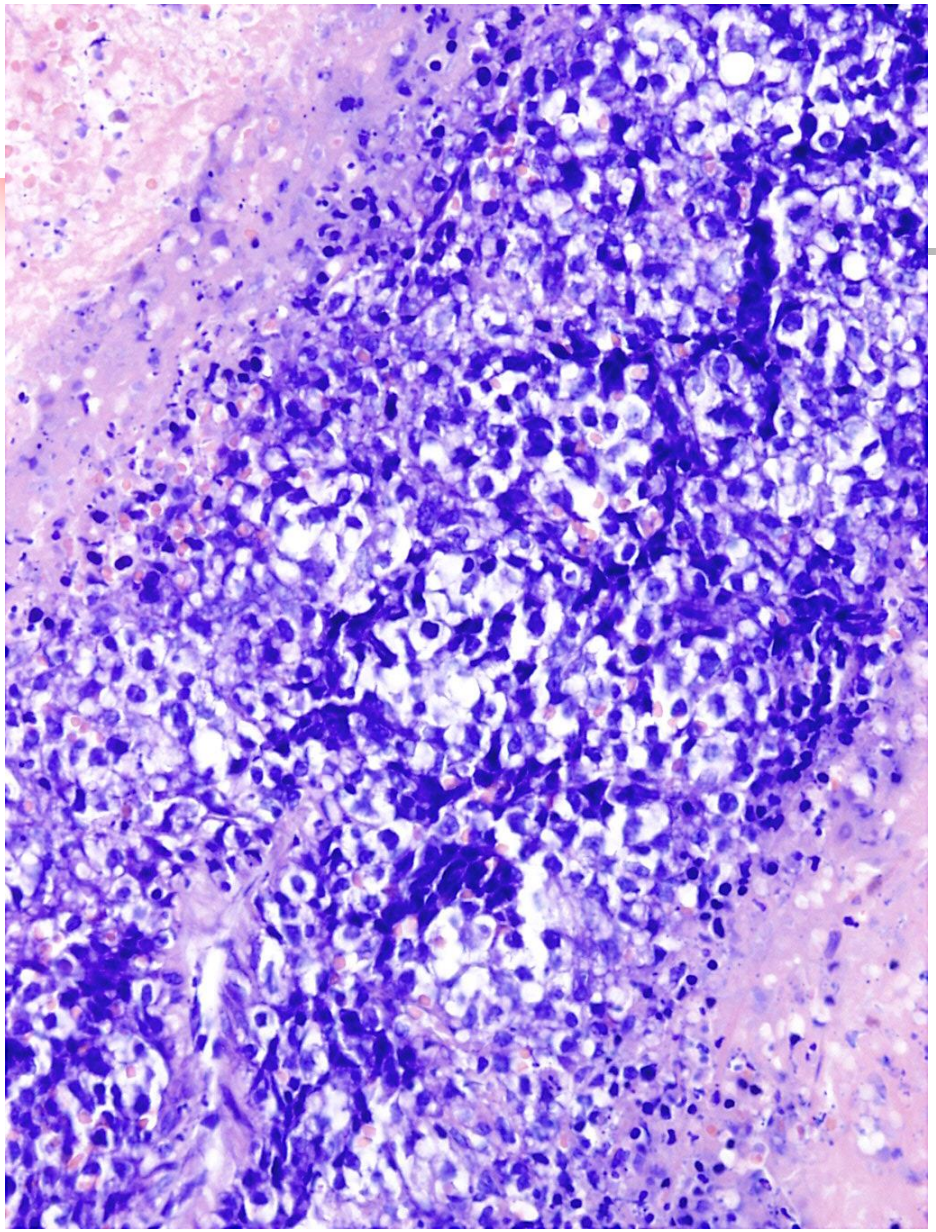

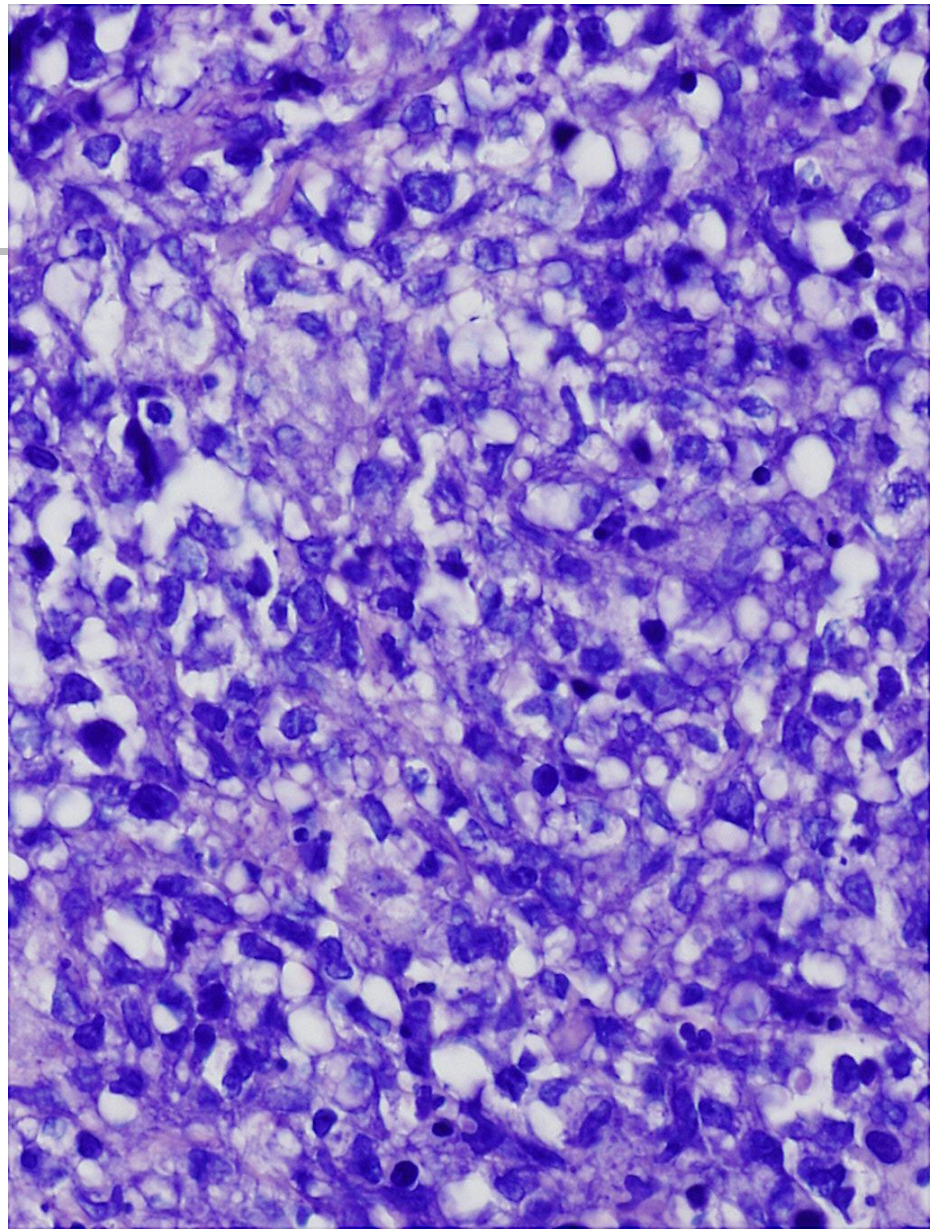

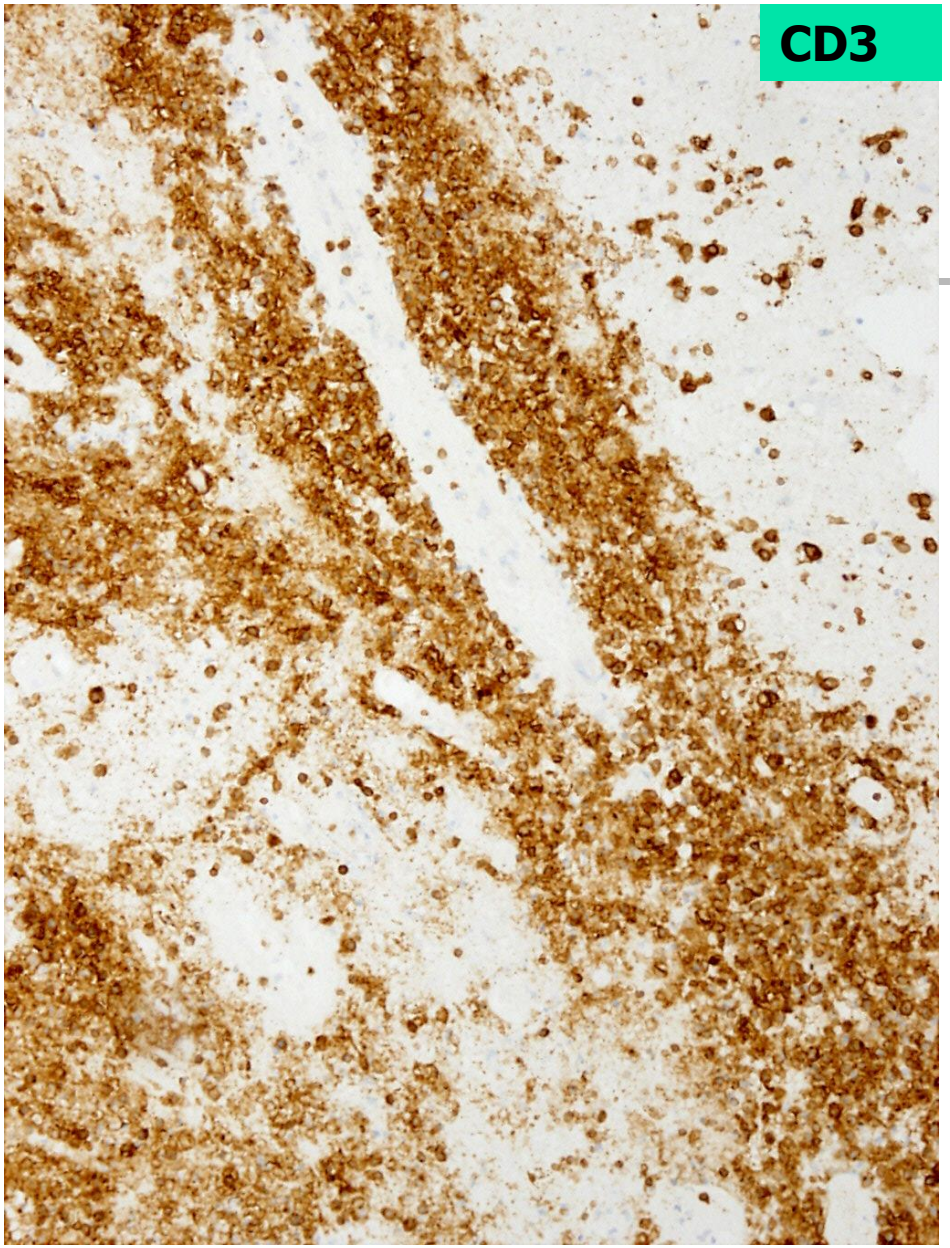
CD3

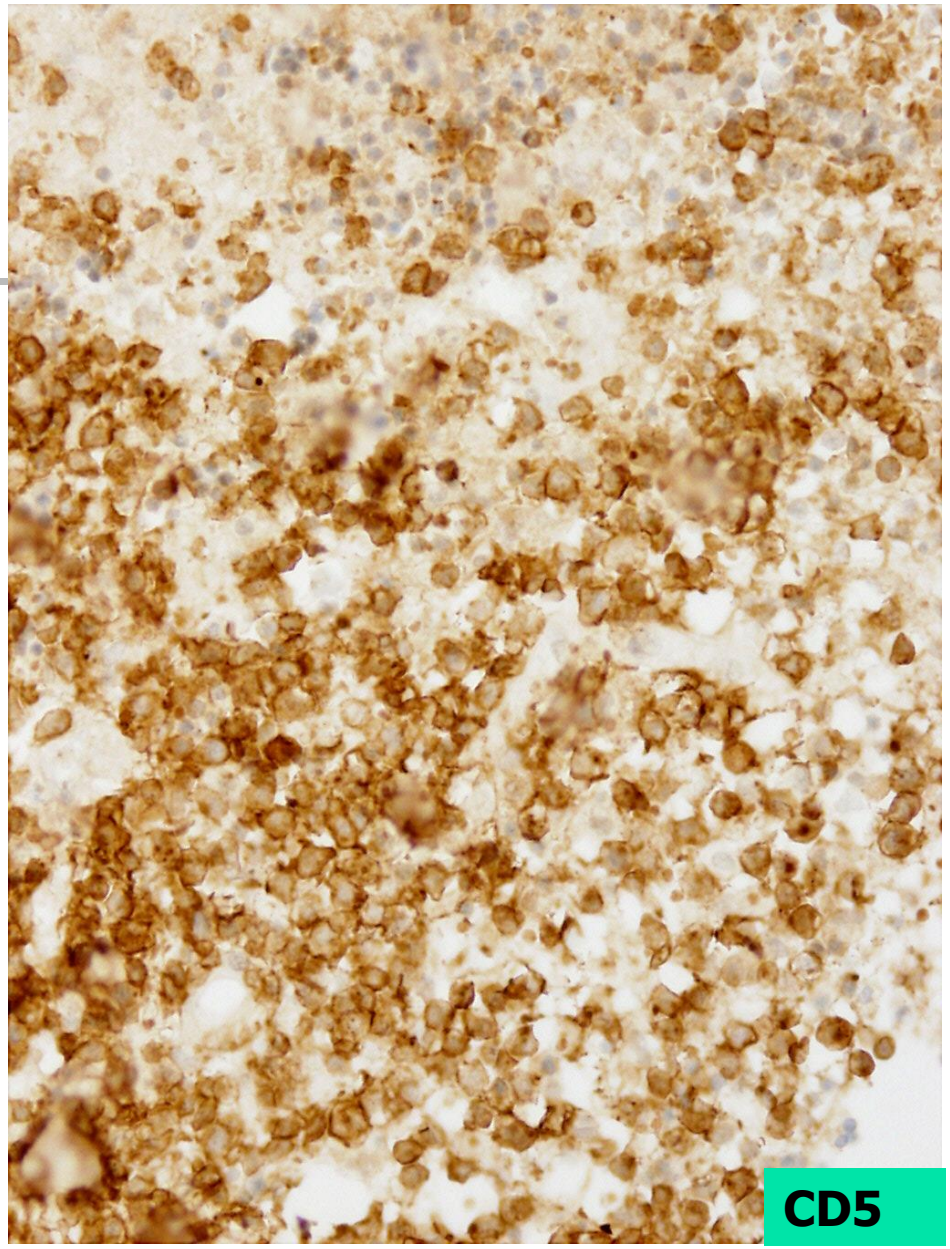
CD5

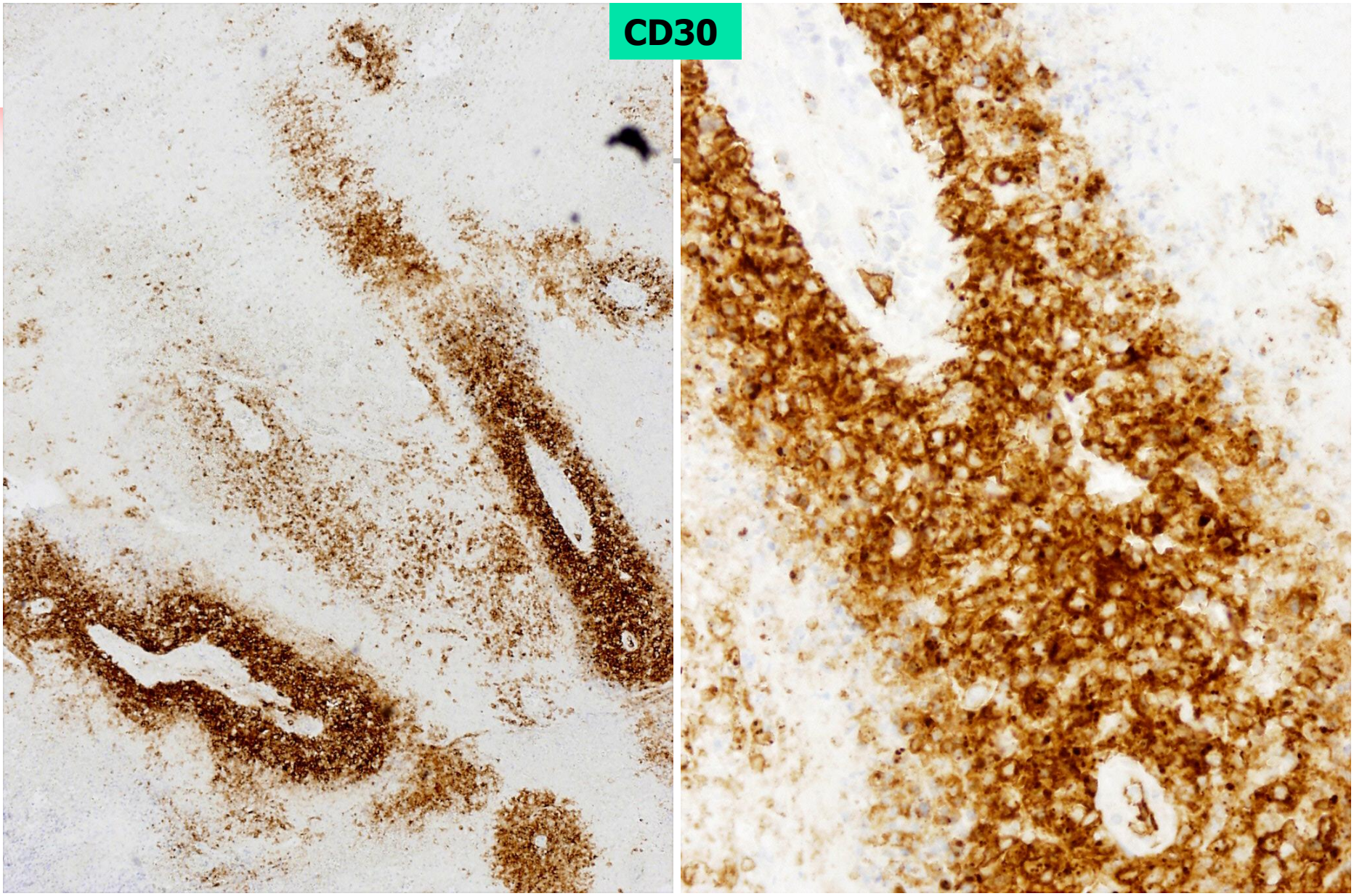
CD30

Imunoprofil:

- Pozitivita: CD3, CD5, CD30,
- Negativita: CD20, PAX5, TdT, ALK1
- **Genetika:**

  Stav lokusu ALK (2p23): limitovaný materiál, nízka intenzita signálov, 98/100 hodnotených veľkých (blastických) jadier bez prestavby, v 2/100 prítomná prestavba ALK génu

  Záver: ALK lokus (2p23) je bez prestavby.

Záver:

Infiltrácia tkaniva mozočka T-bunkovým NHL zo spektra PTCL, typu ALK negatívneho ALCL (v.s. primárny).

Prípad č. 10

- muž, 40 rokov
- fragmenty epidurálneho tumoru spinálneho kanála Th6-Th7
- paraplégia týždeň, vývoj 3 týždne
- súčasne tumor na hornej pere, zatiaľ nie je výsledok
- konzultácia Cytopathos, BA

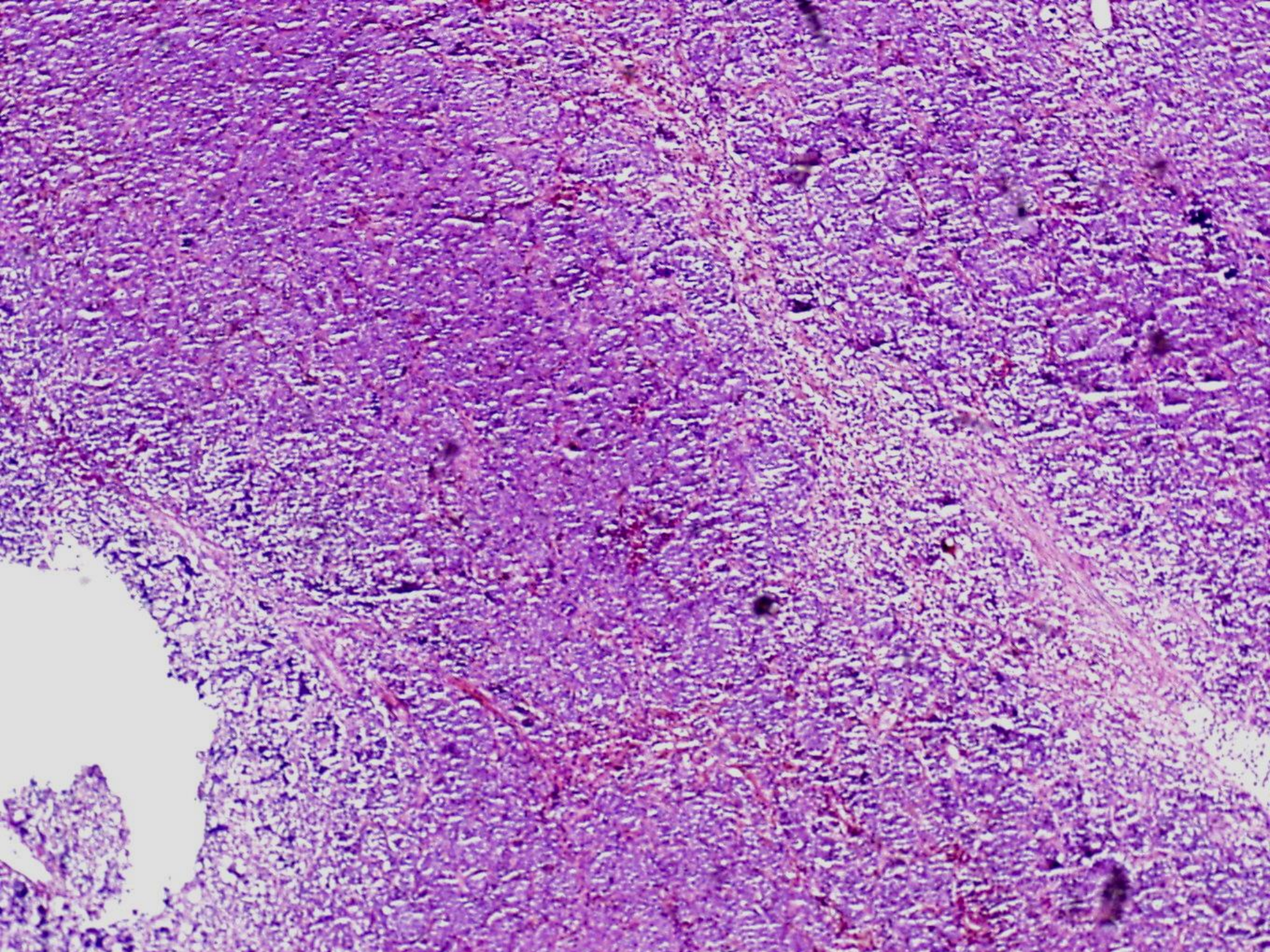

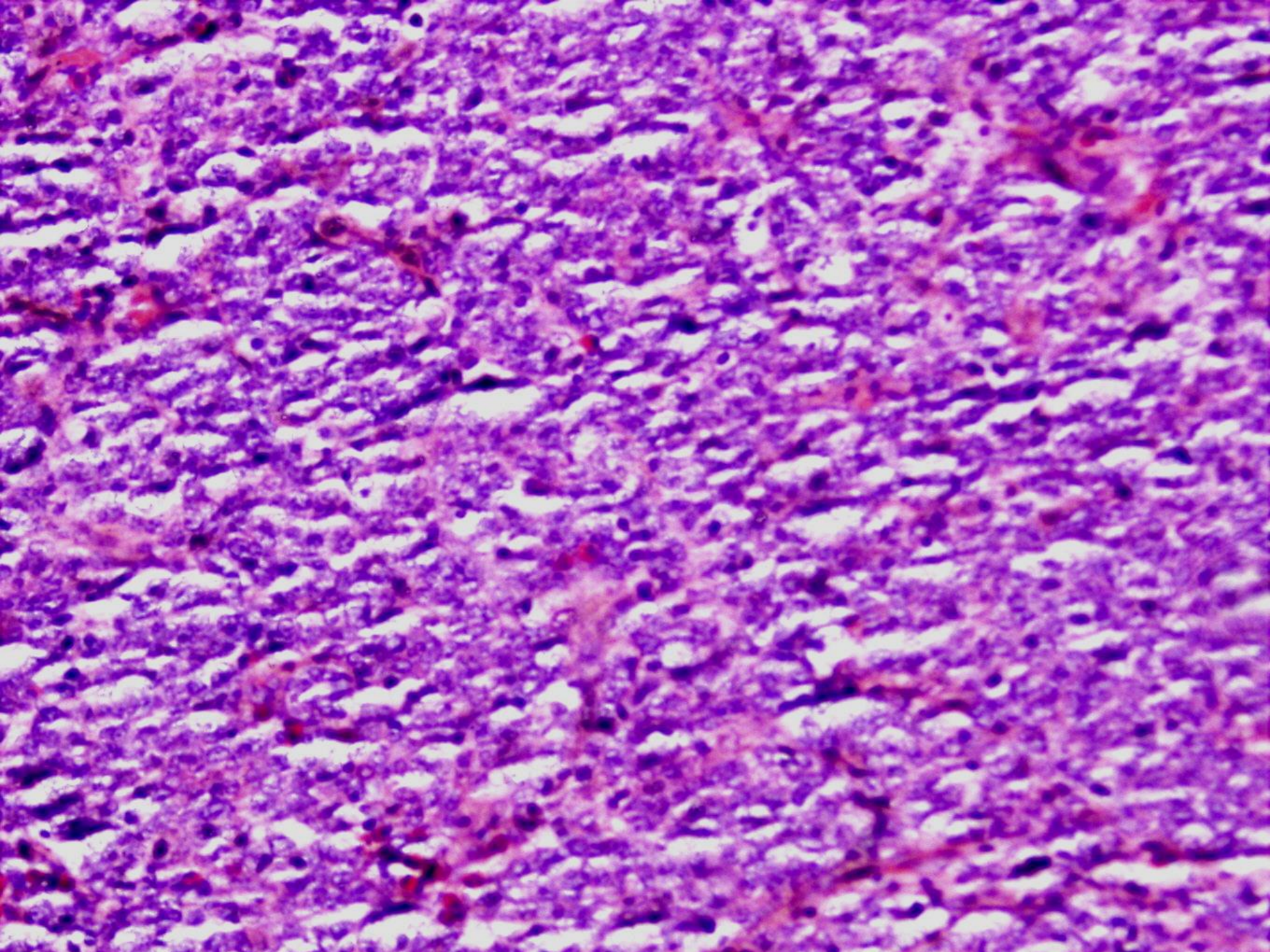

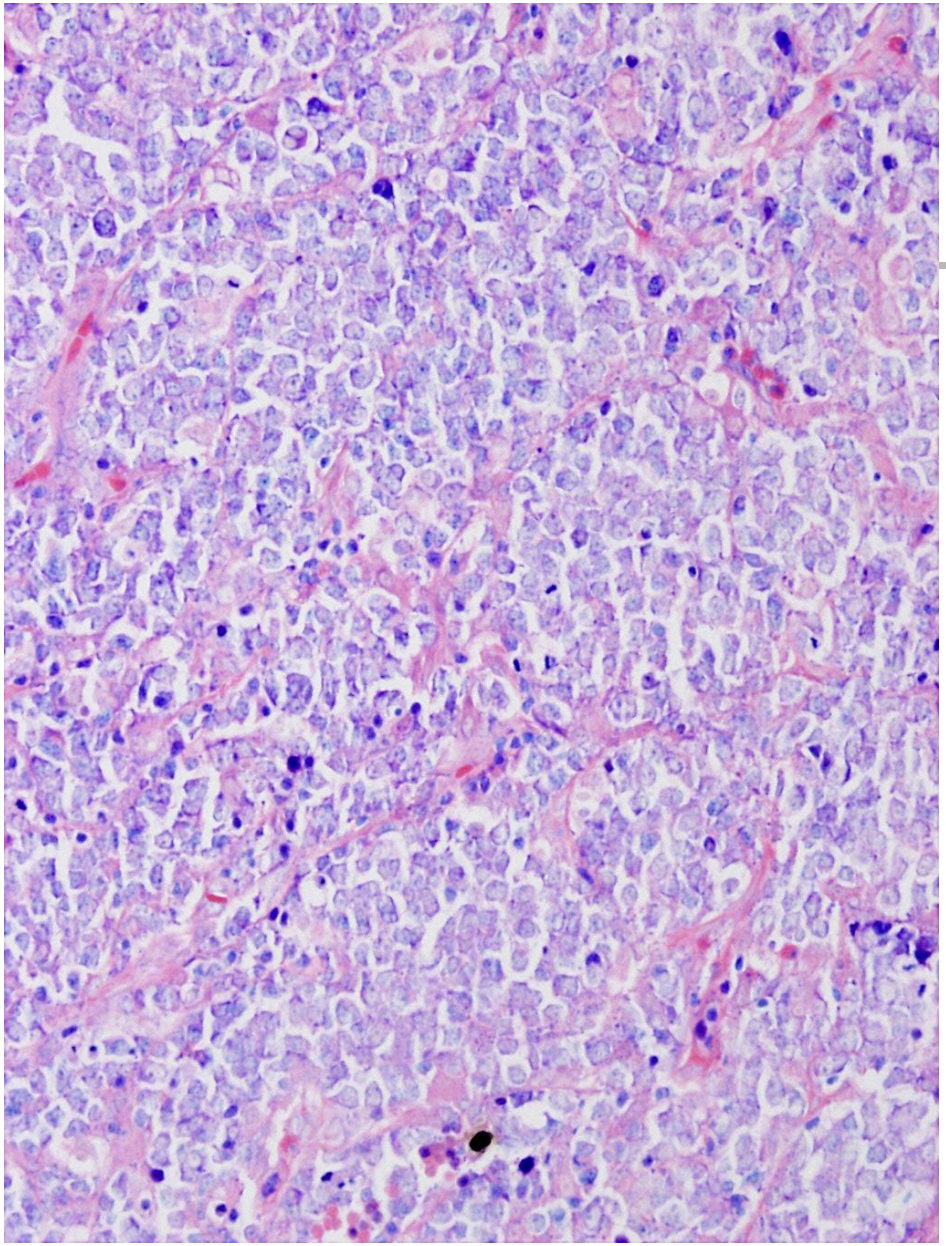

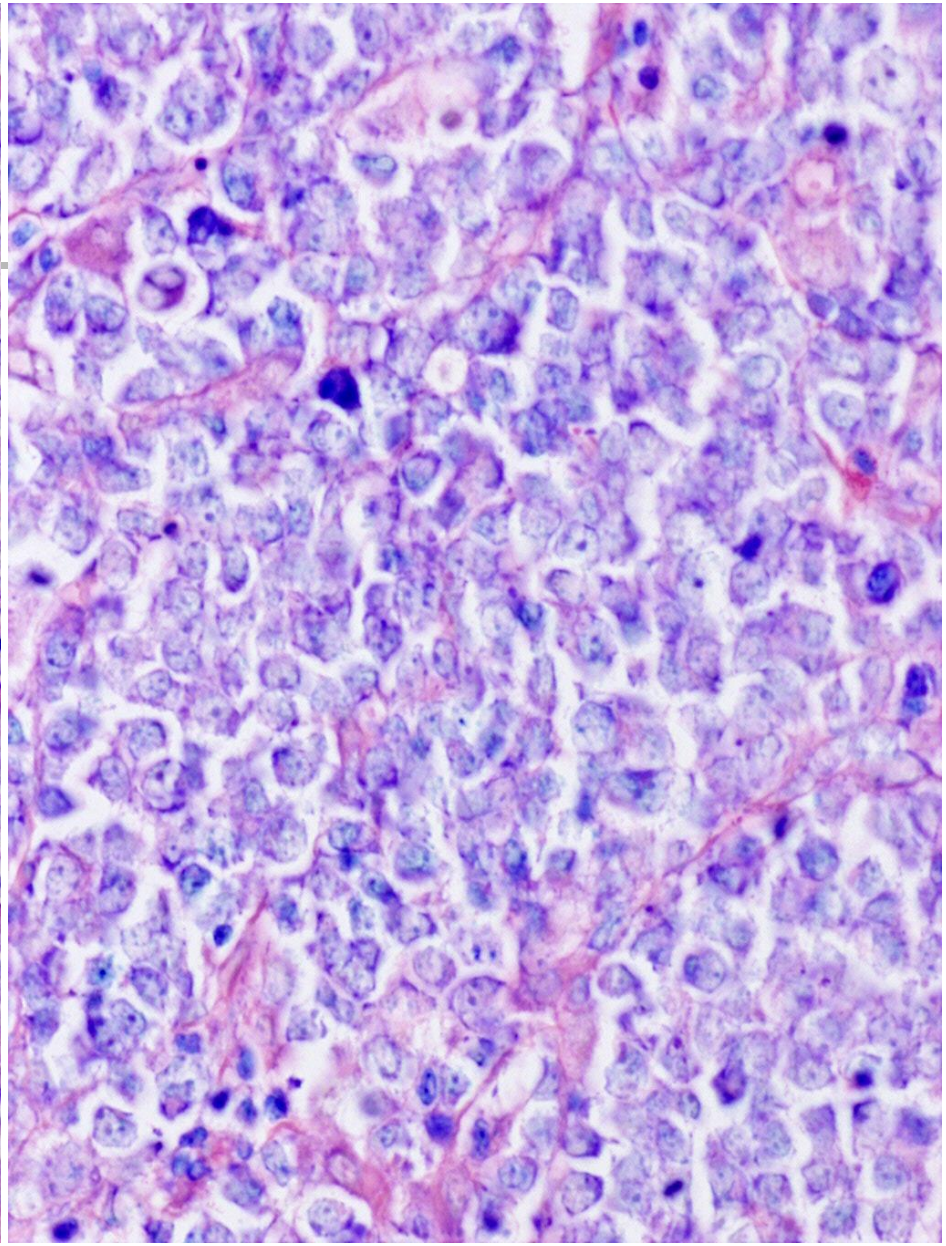

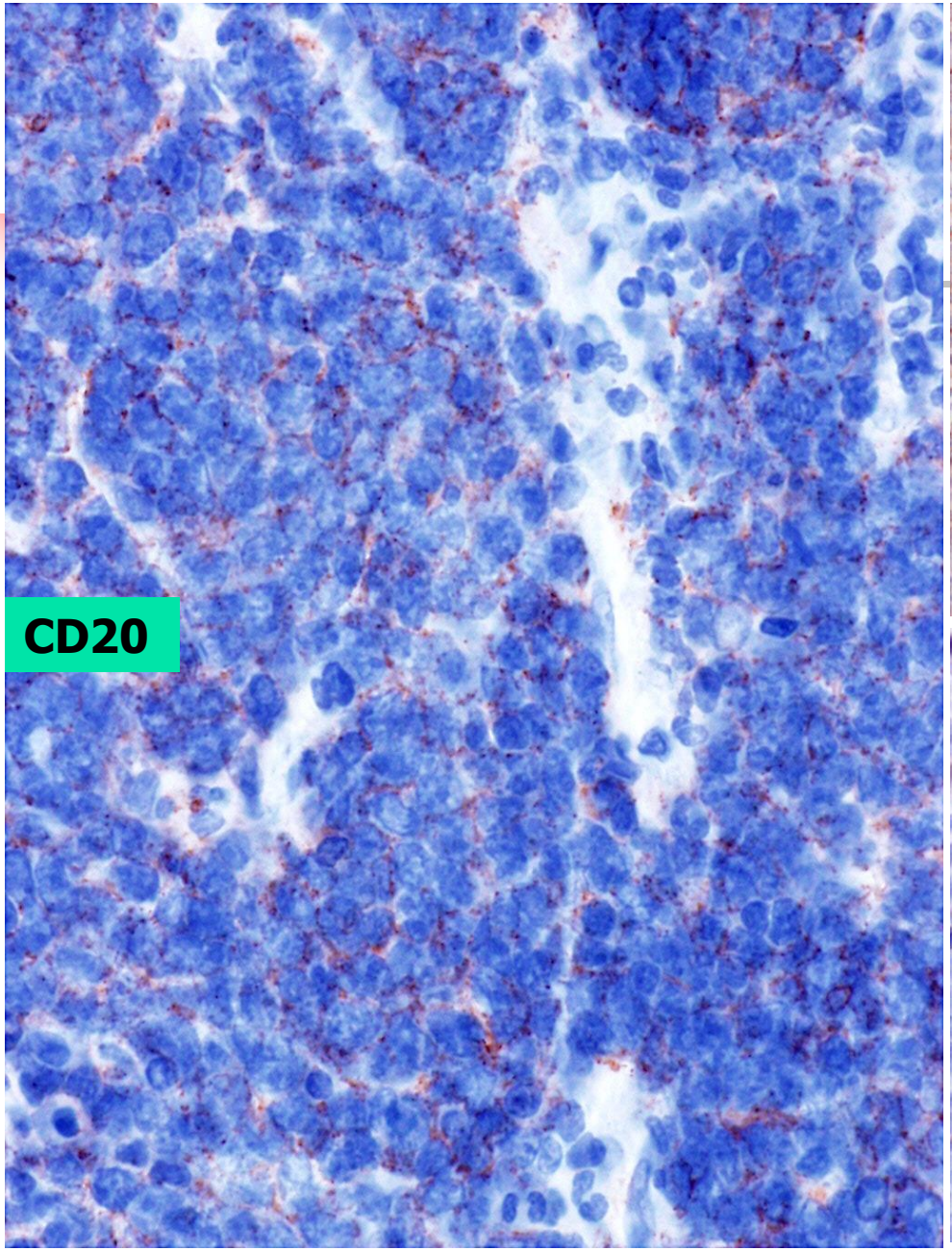
CD20

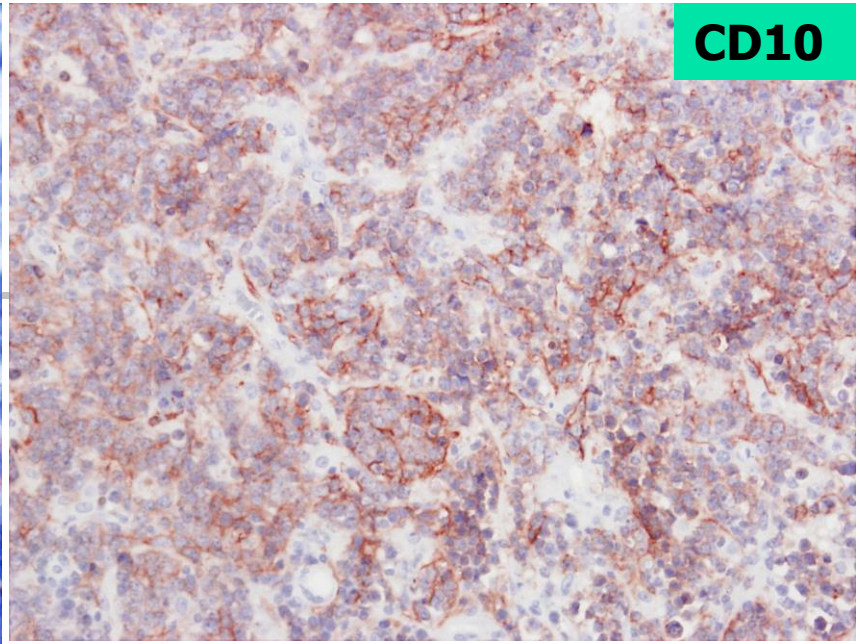
CD10

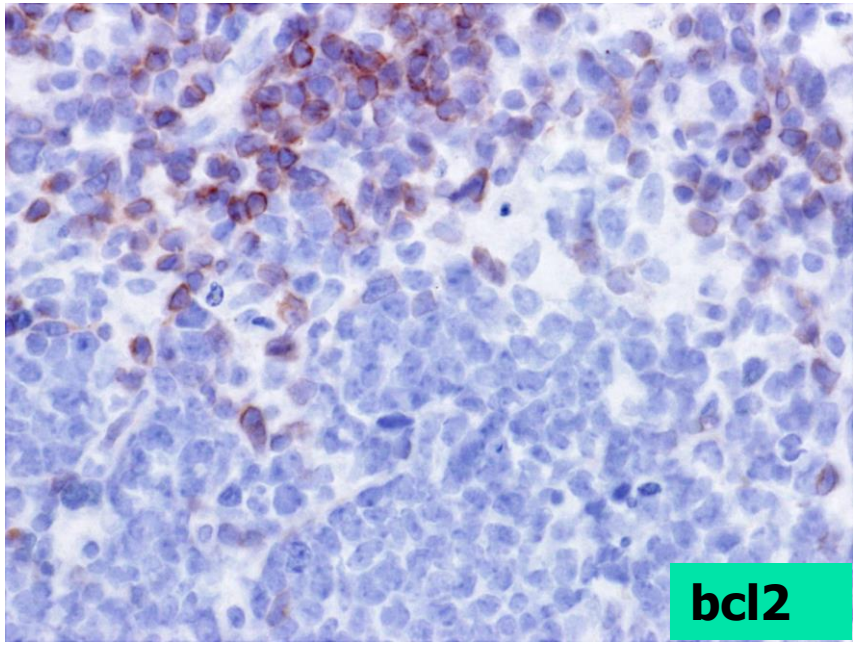
bcl2

Imunoprofil:

- Pozitivita:
  CD20, CD10, bcl6 (+/-), MIB1 100%,
  Ig typu lambda

- Negativita: CD3, bcl2, MUM1

Záver:

V kontexte recentne konzultačne vyšetrenej biopsie primárneho ložiska na hornej pere ide o identický B-NHL typu Burkittovho lymfómu (BL), variant s plazmocytoidnou diferenciáciou a s dokázanou infiltráciou KD.

Prípad č. 11

- žena, 37 rokov
- LU z axily vľavo, extrémne krehká
- Dg.: suspektný lymfóm (HL?)
- konzultácia PAO Rožňava (04/08)

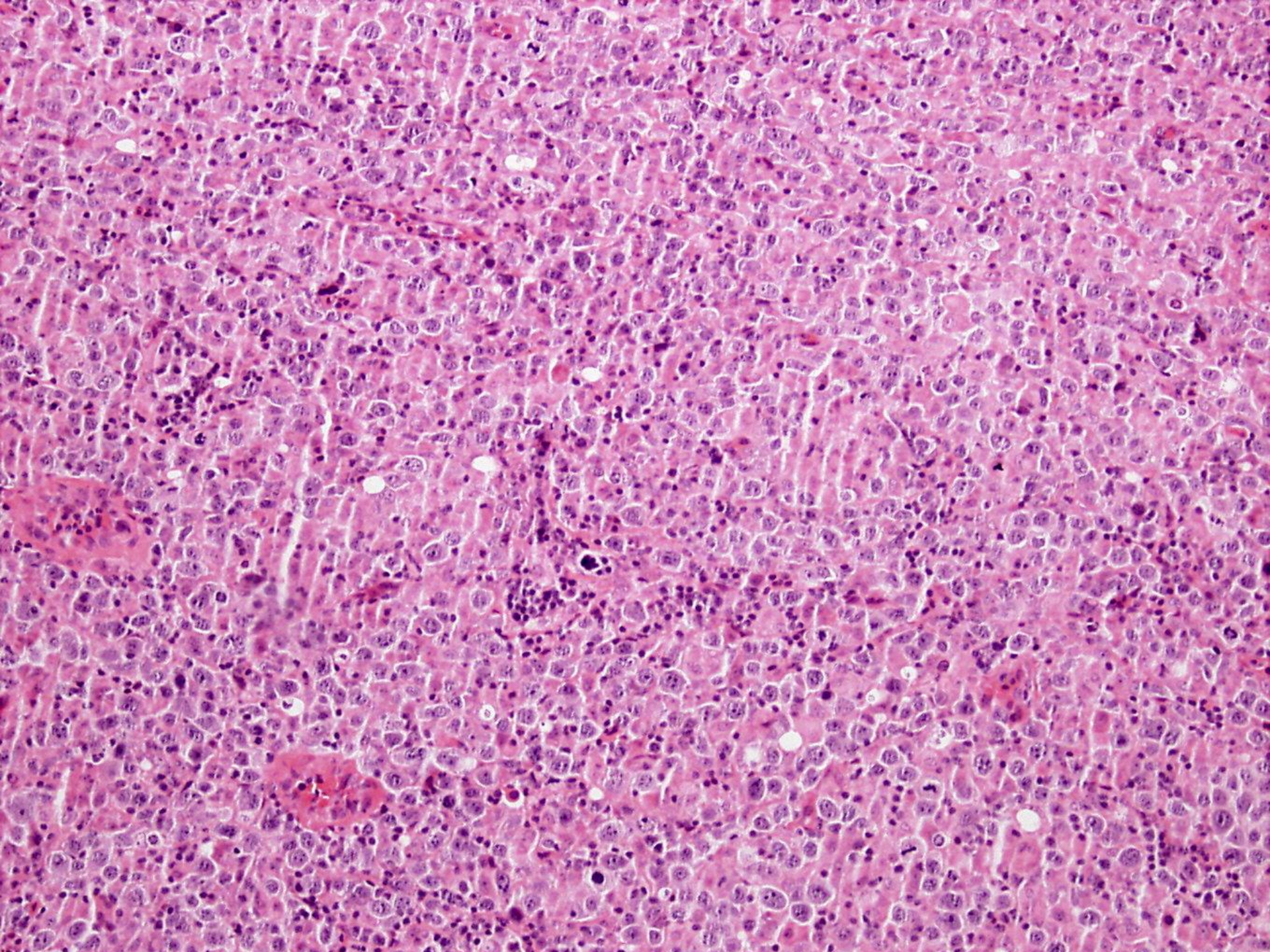

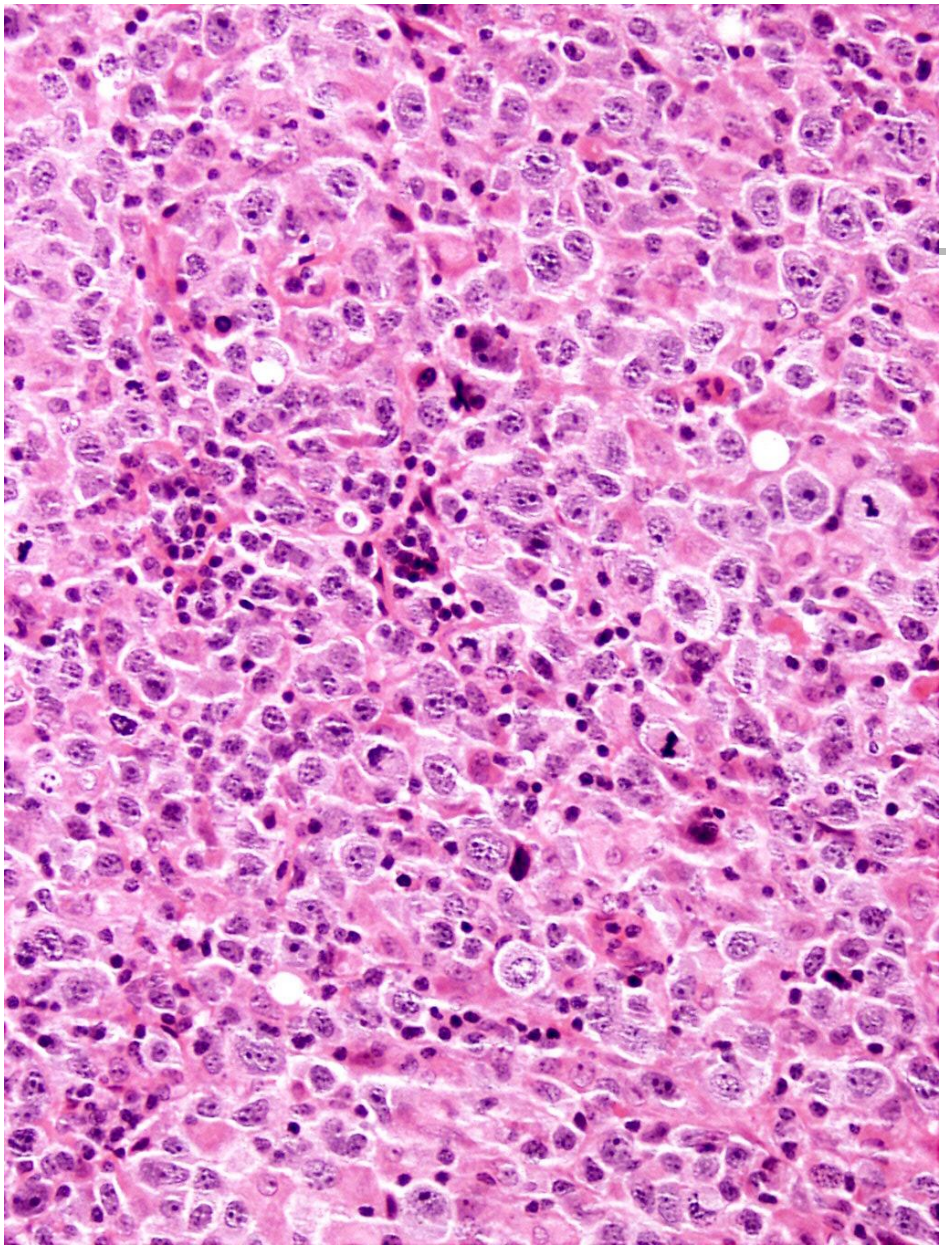

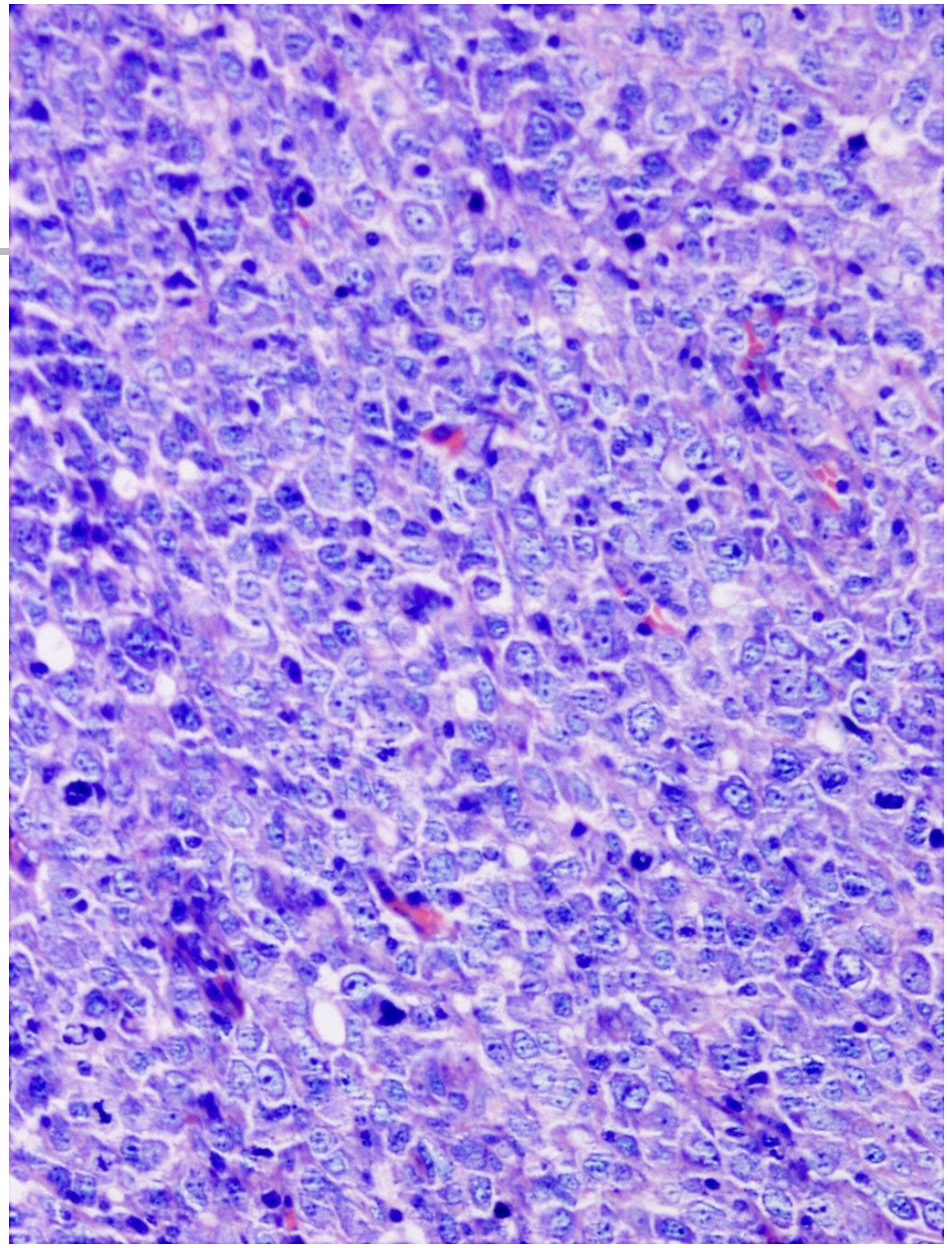

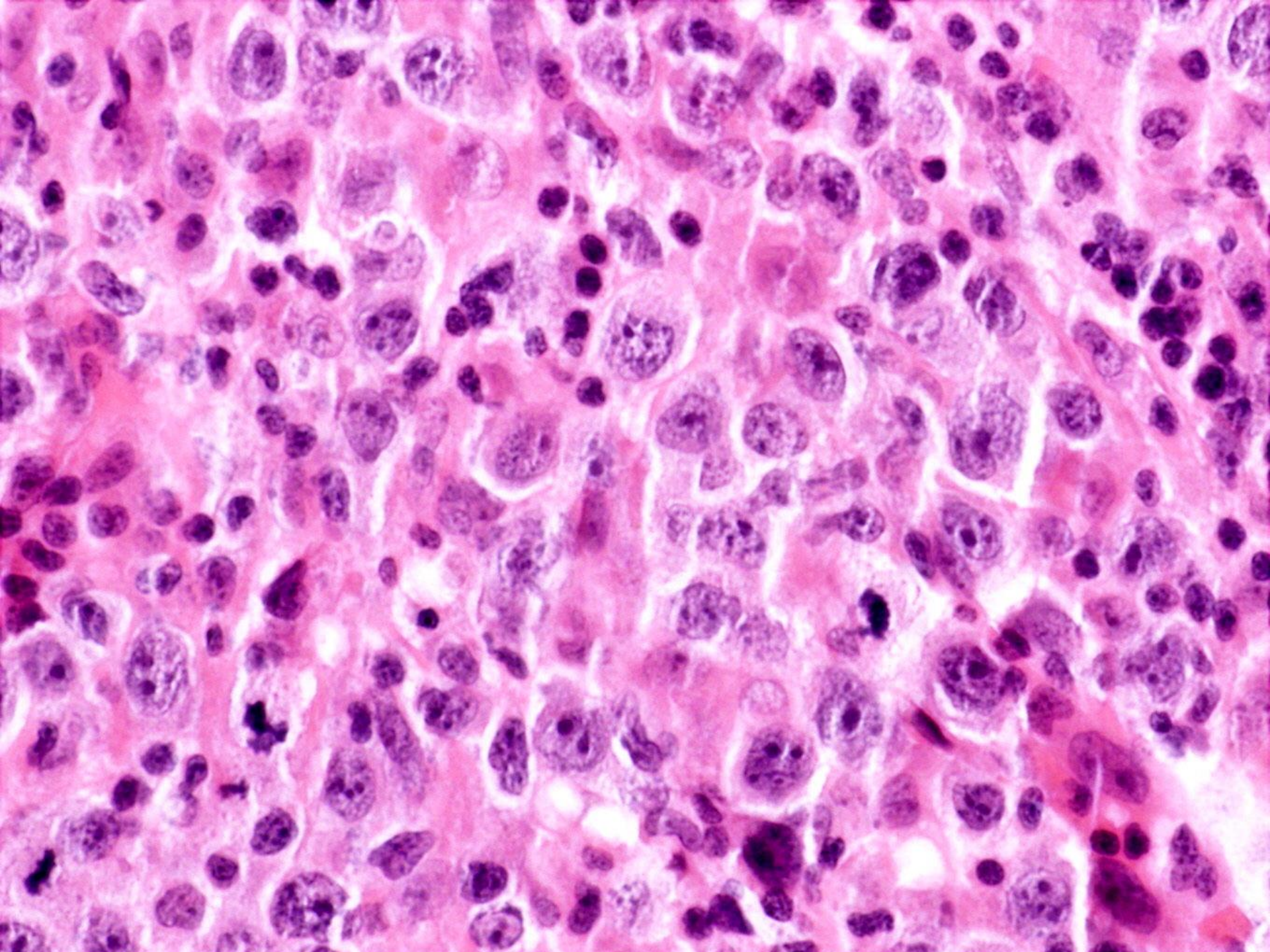

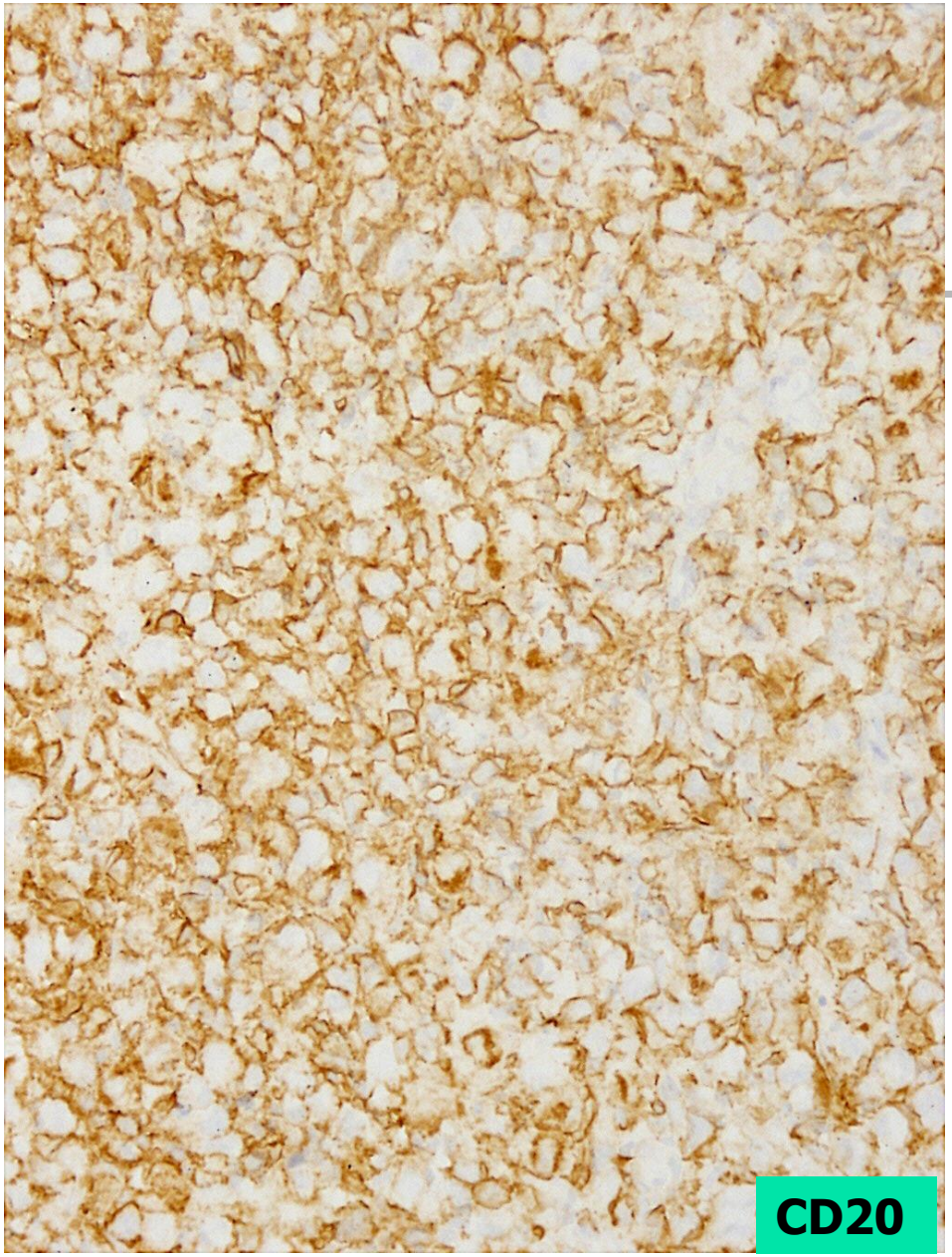
CD20

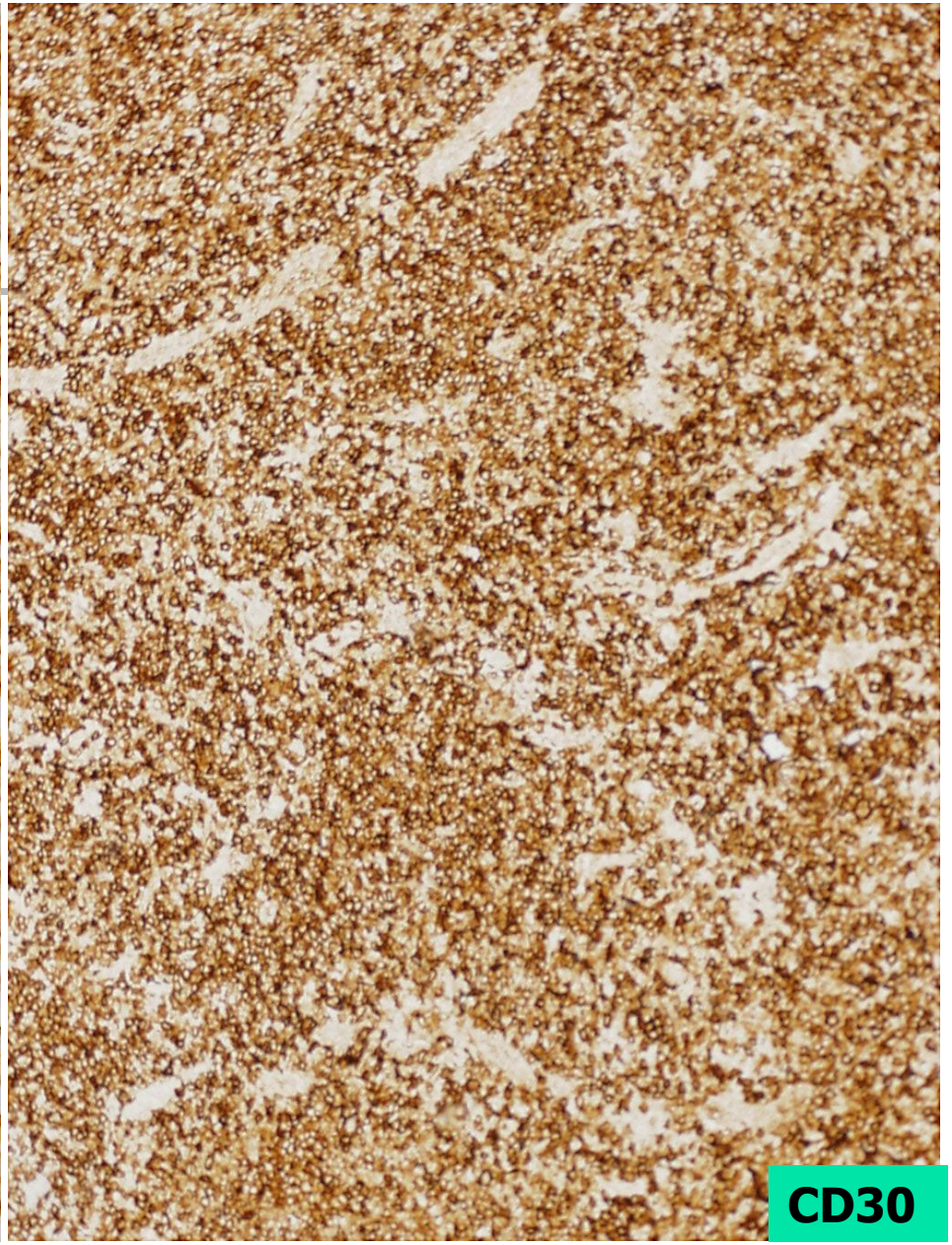
CD30

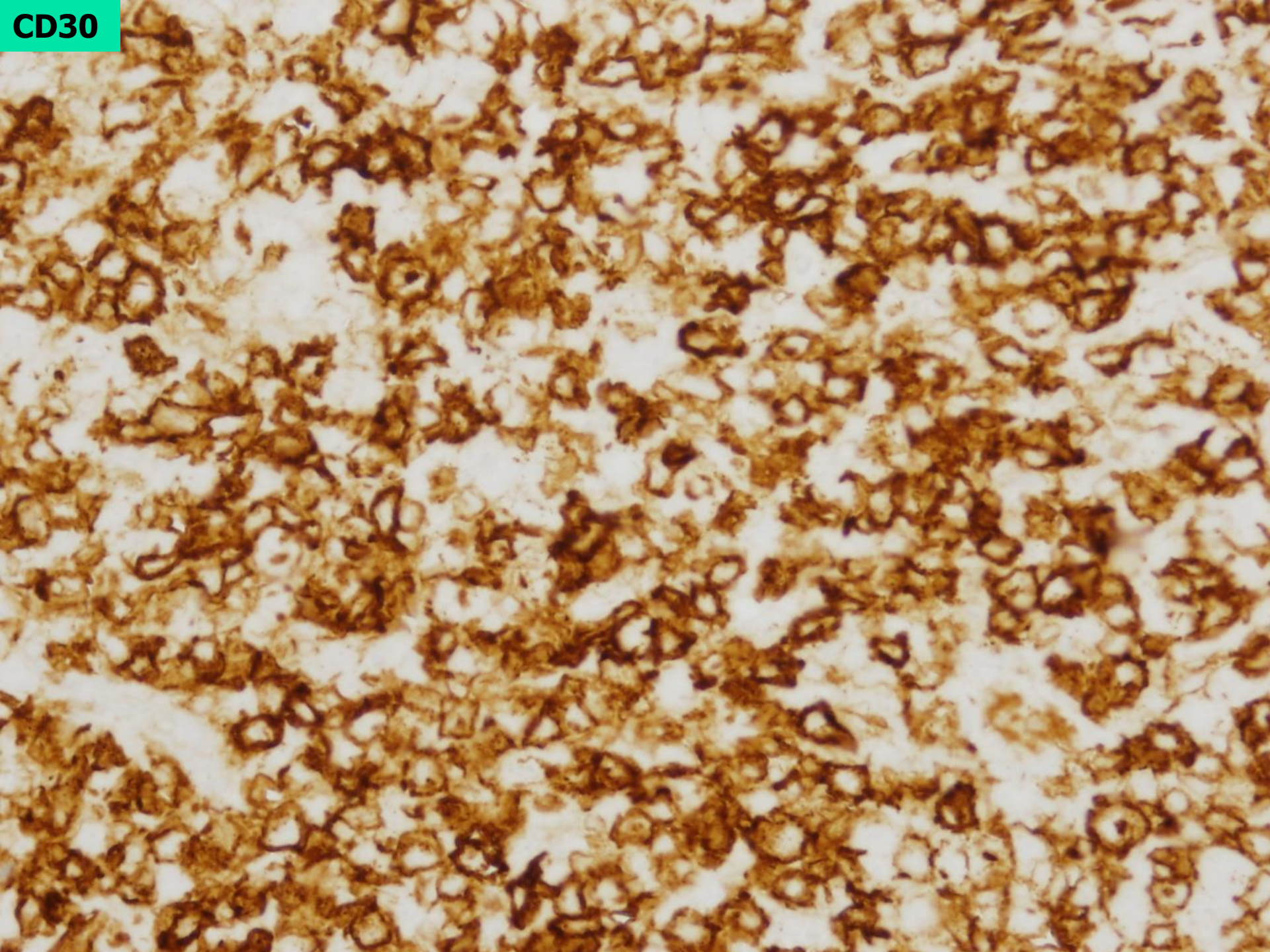
CD30

Imunoprofil:

- Pozitivita: CD20, CD30, bcl2
- Negativita: CD3, CD10, CD15, bcl6

Záver:

Ide o infiltráciu LU blastickým nádorom, ktorý patrí do kategórie agresívneho, tzv. anaplastického variantu DLBCL s non-GC (v.s. ABC) fenotypom.

Biopsia Tu mozgu (12/09)

- žena, 38 rokov
- Tu cerebri F l.sin., susp. meningeóm
- dif. dg. MTS NHL (v MT diagnostikovaný anaplastický variant DLBCL)
- konzultácia PAO UNLP KE

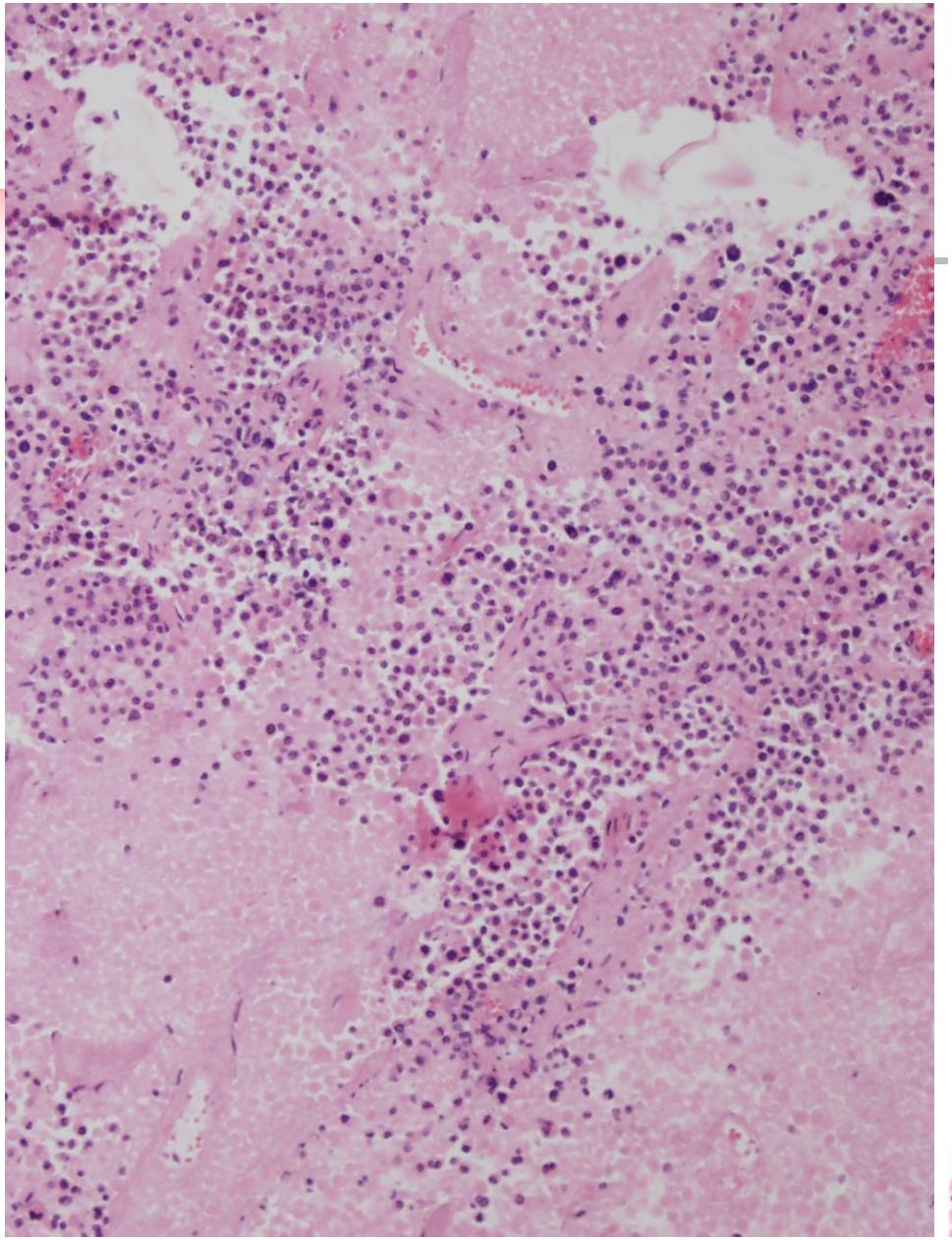

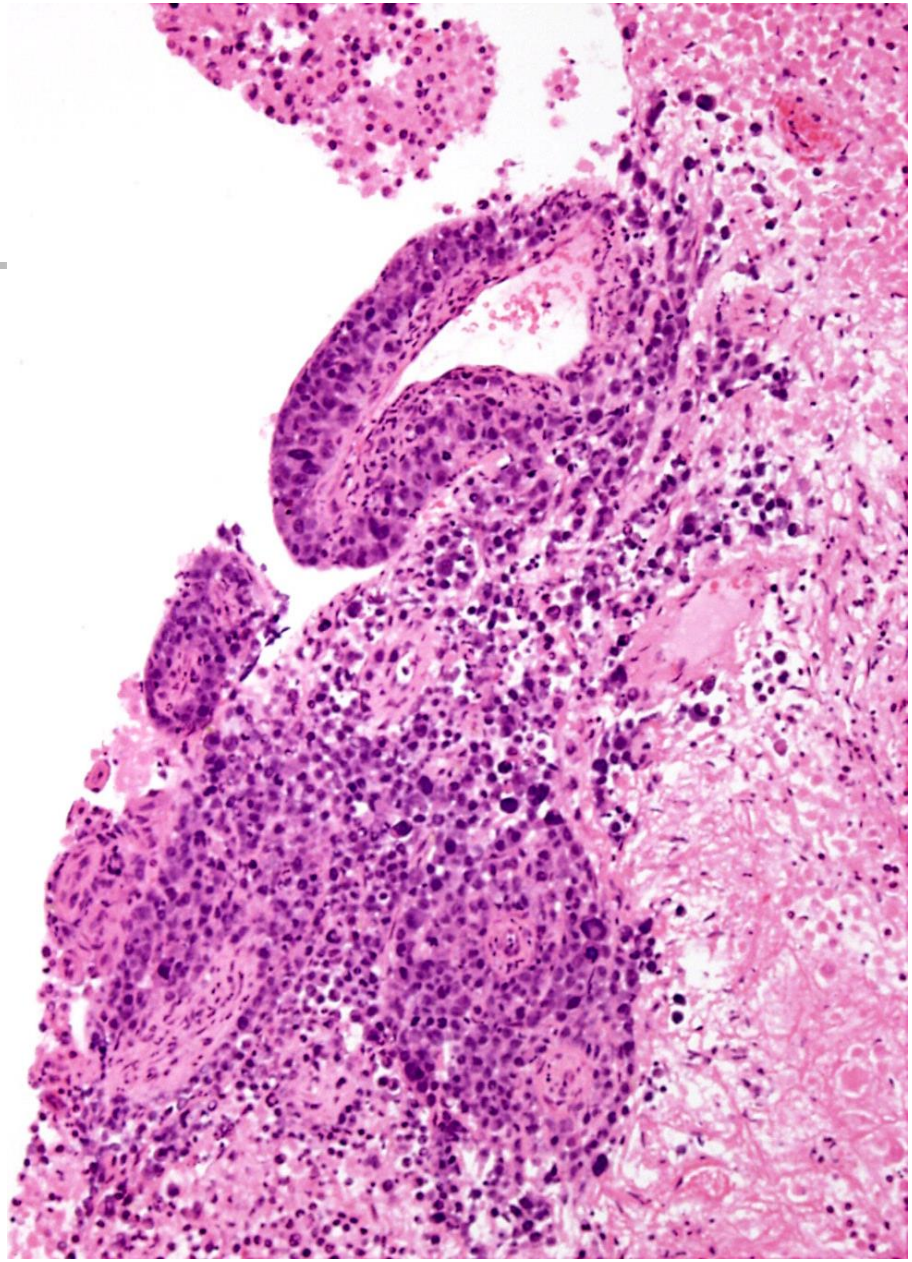

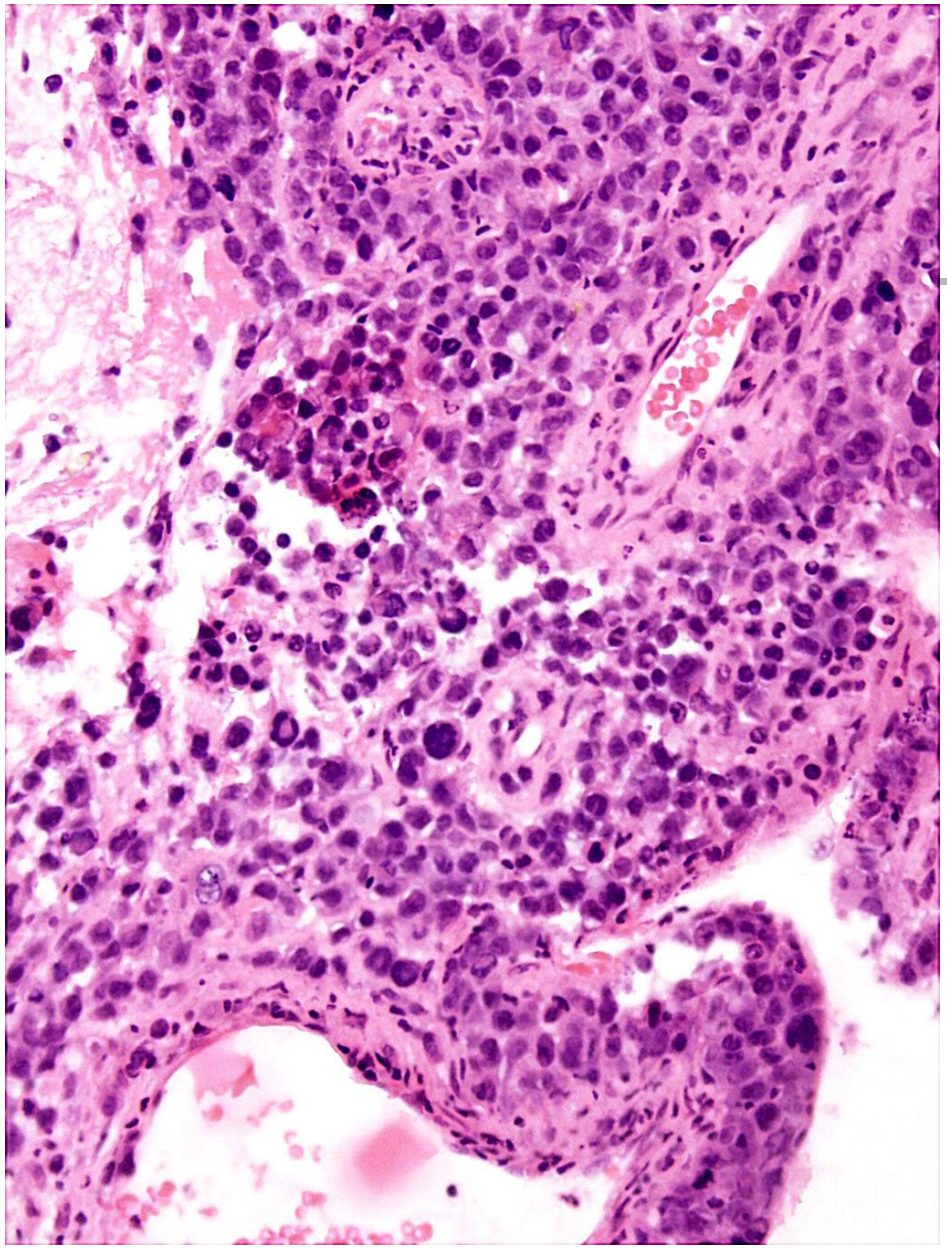

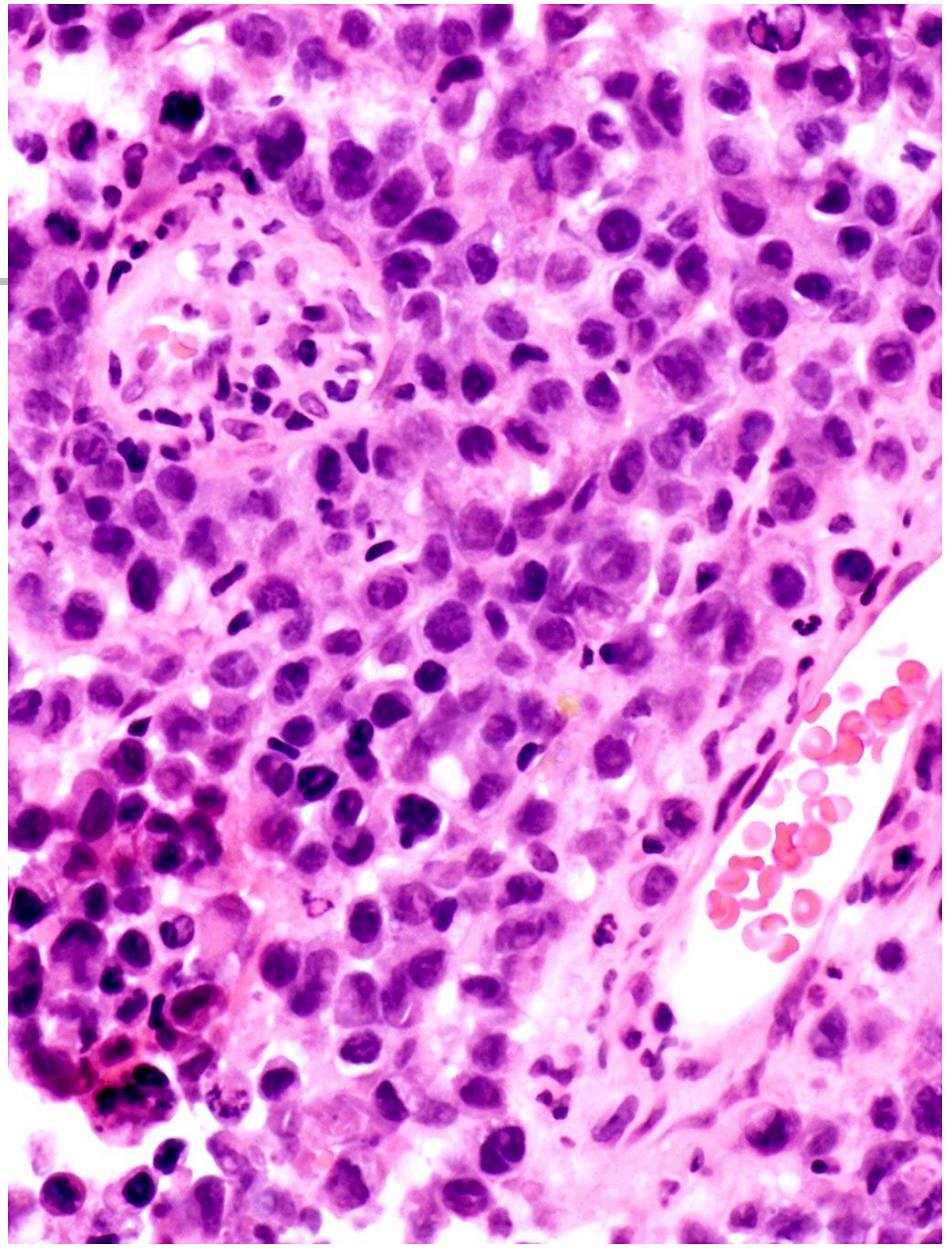

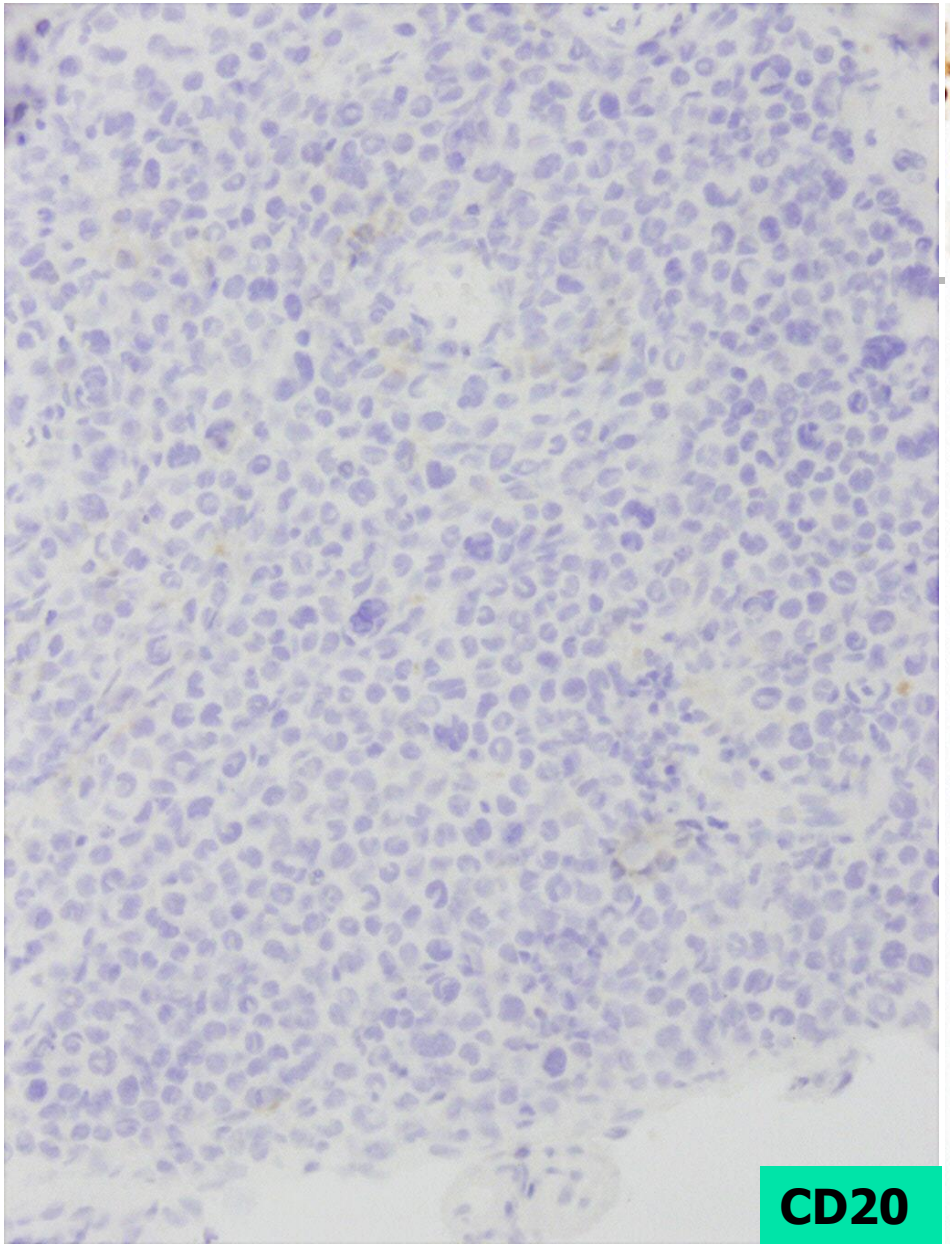
CD20

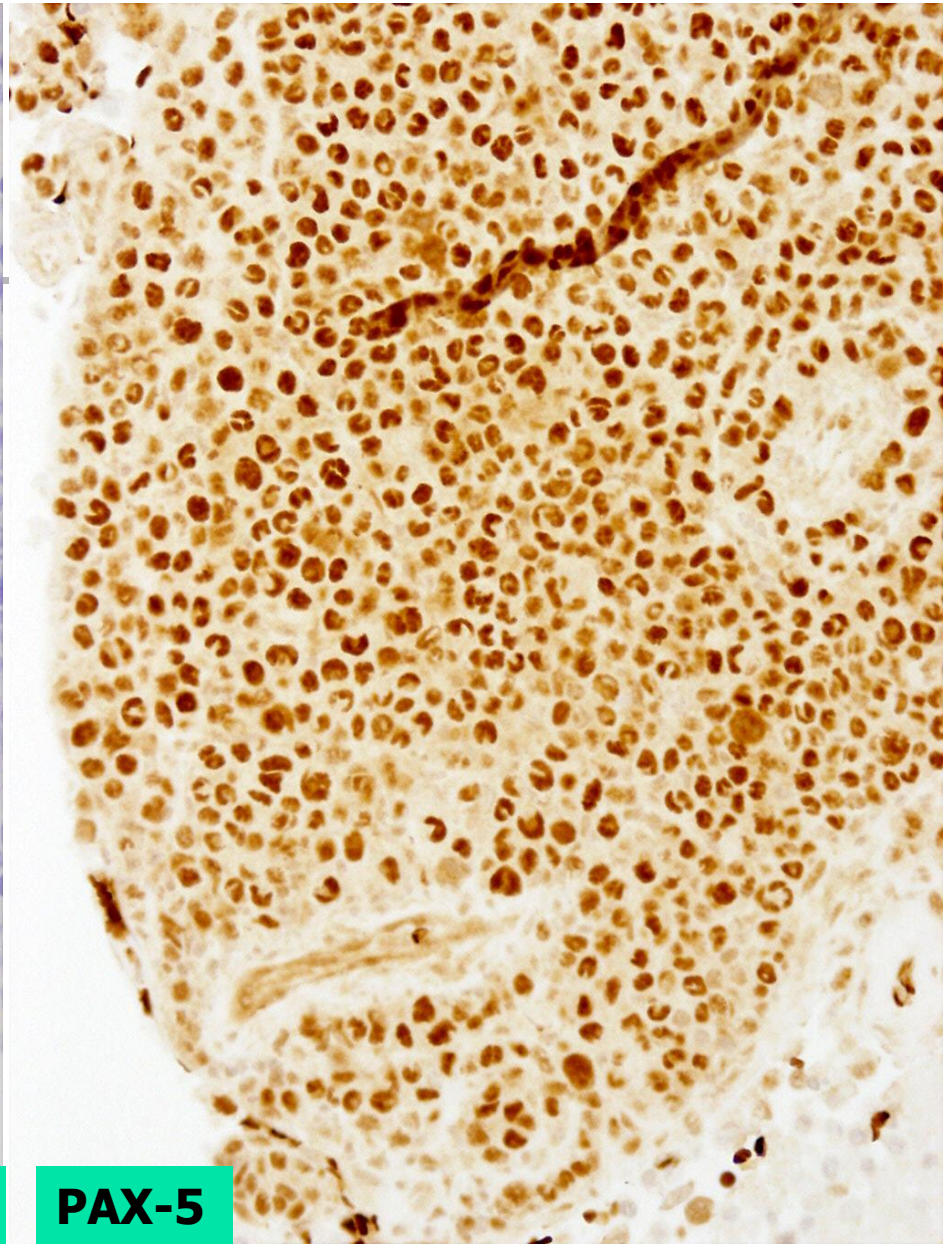
PAX-5

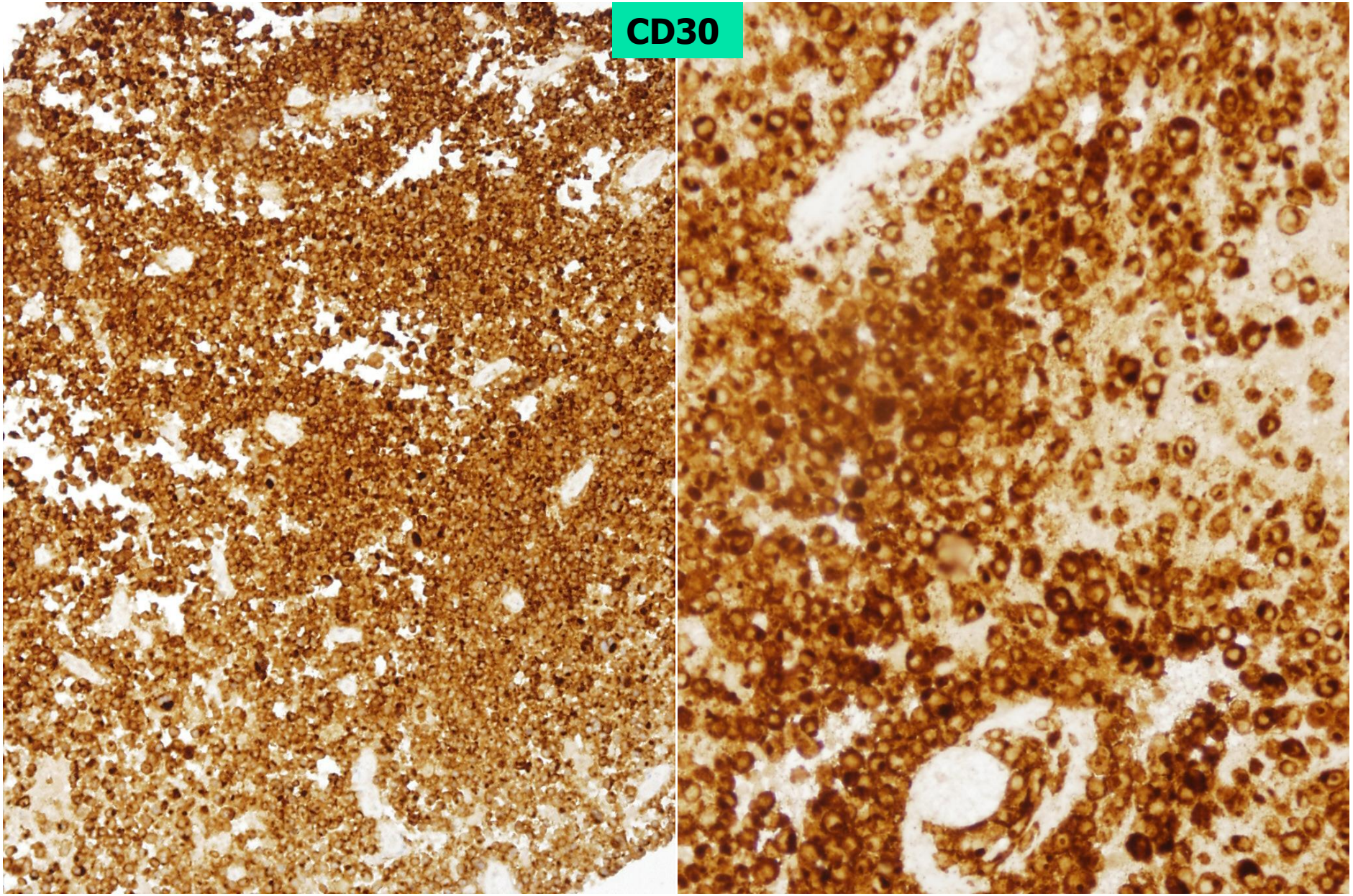
CD30

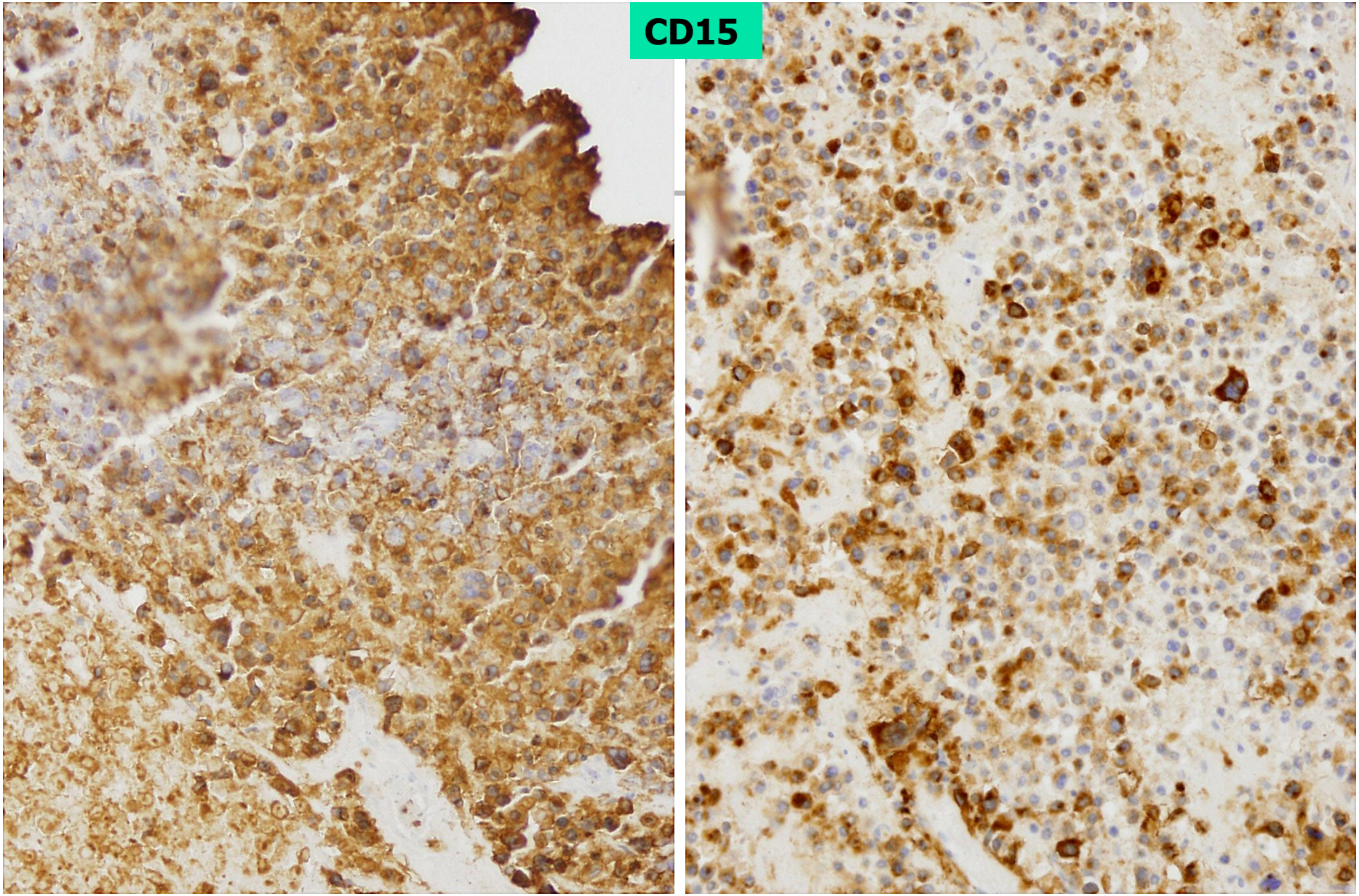
CD15

Imunoprofil:

- Pozitivita:

  (CD45), PAX5, CD30 ("dot-like" Golgiho typ a membránový typ pozitivity), CD15 granulárne

- Negativita: CD20, CD79a, CD2, CD7

  (ALK1, CD10, CD43, CD3, CD5, CD4, CD8, CD43, CD45RO ?, CD56, CD57, MUM1, bcl6)

Genetika z LU (2010)

- 1.) V hodnotených blastoch sme dokázali zvýšený počet signálov (2-4O2-6G2-4Aq) bez IGH/MYC fúzie. Počet kópií MYC génu sa zdal byť ekvivalentný počtu centromér chromozómu 8.
- 2.) Ani opakovaným vyšetrením (18.02., 05.03. a 12.03.) sa nám nepodarilo vyšetriť stav MYC lokusu (8q24).
- 3.) V hodnotených blastoch dokázali prítomnosť 2-4 kópií BCL2 génu bez prestavby.

Záver: Realizovanými FISH vyšetreniami sme vylúčili prestavbu v oblasti BCL2 lokusu (8q21). MYC lokus (8q24) sa nám v tomto materiáli spoľahlivo vyšetriť nepodarilo. Dokázaný počet signálov by mohol svedčiť pre zvýšený počet chromozómov 8, 14 a 18 (polyzómia?, polyploidia?).

Záver:

- Ide o anaplastický DLBCL s koexpresiou CD30 aj CD15 pozitivity, pričom nádor sa tak prinajmenej teoreticky stáva procesom "šedej zóny" medzi DLBCL a c-HL (aj keď koexpresia CD15 je opísaná v nízkom percente nielen T-ALCL, ale raritne aj v anaplastickom DLBCL).
- V porovnaní s predošlým vyšetrením LU axily je zrejmá strata (fenotypovej) diferenciácie (strata expresie CD20) a pribudnutie expresie CD15 (v pôvodnom nádore bola negatívna)
- Podľa klinických údajov v 06/2009 pacientka absolvovala autológnu TPKB – PTLD ?

Poďakovanie

- kolegom z ÚPA UNM
- poskytovateľom konzultačných biopsií za dôveru a spoluprácu
- organizátorom za pozvanie
- Vám všetkým za pozornosť

STUBAIER GLETSCHER
TOP OF TYROL
3.210 m

ROSSIGNOL
ROSSIGNOL