

XXI. Martinský bioptický seminář, SD IAP

Lúčky 2015

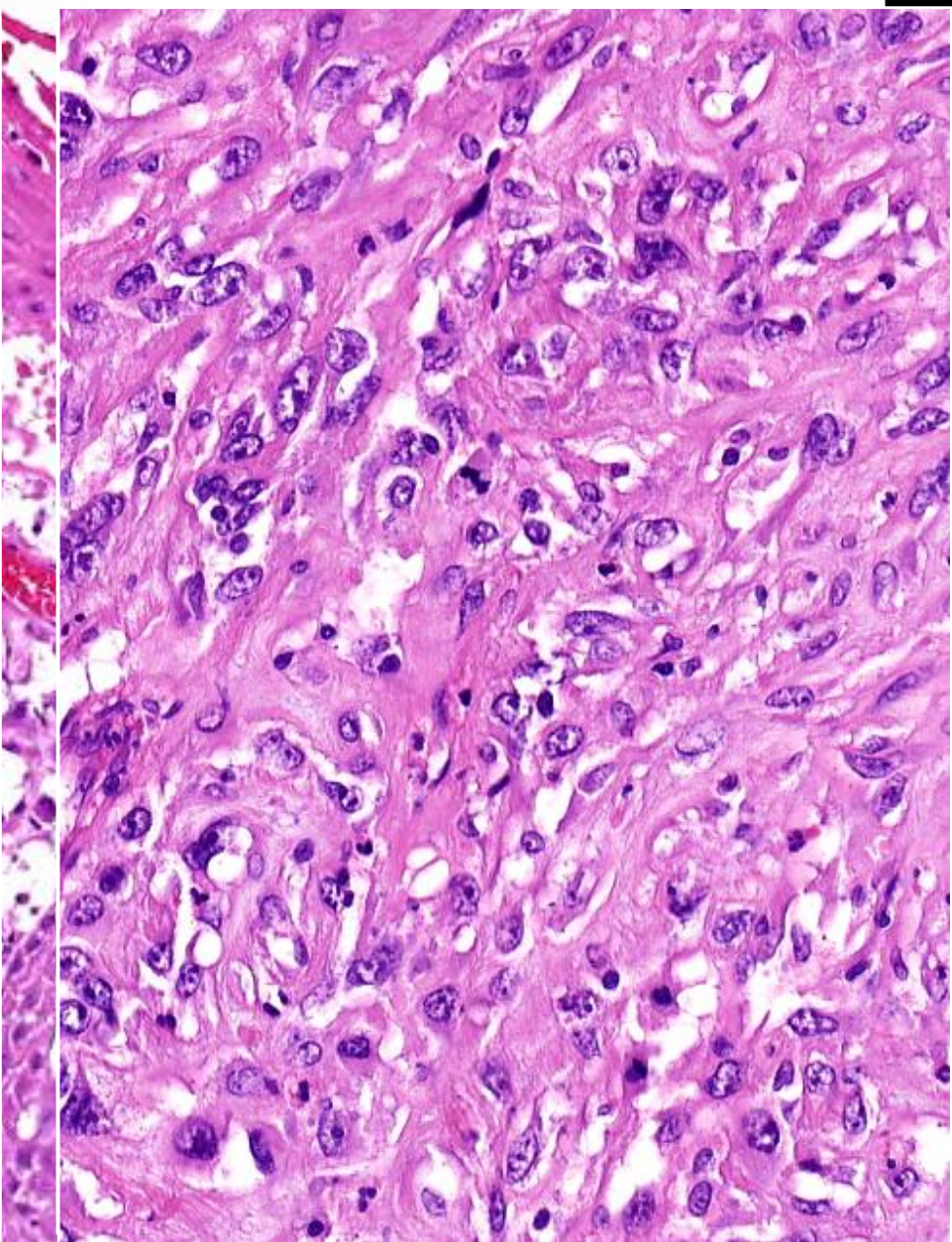
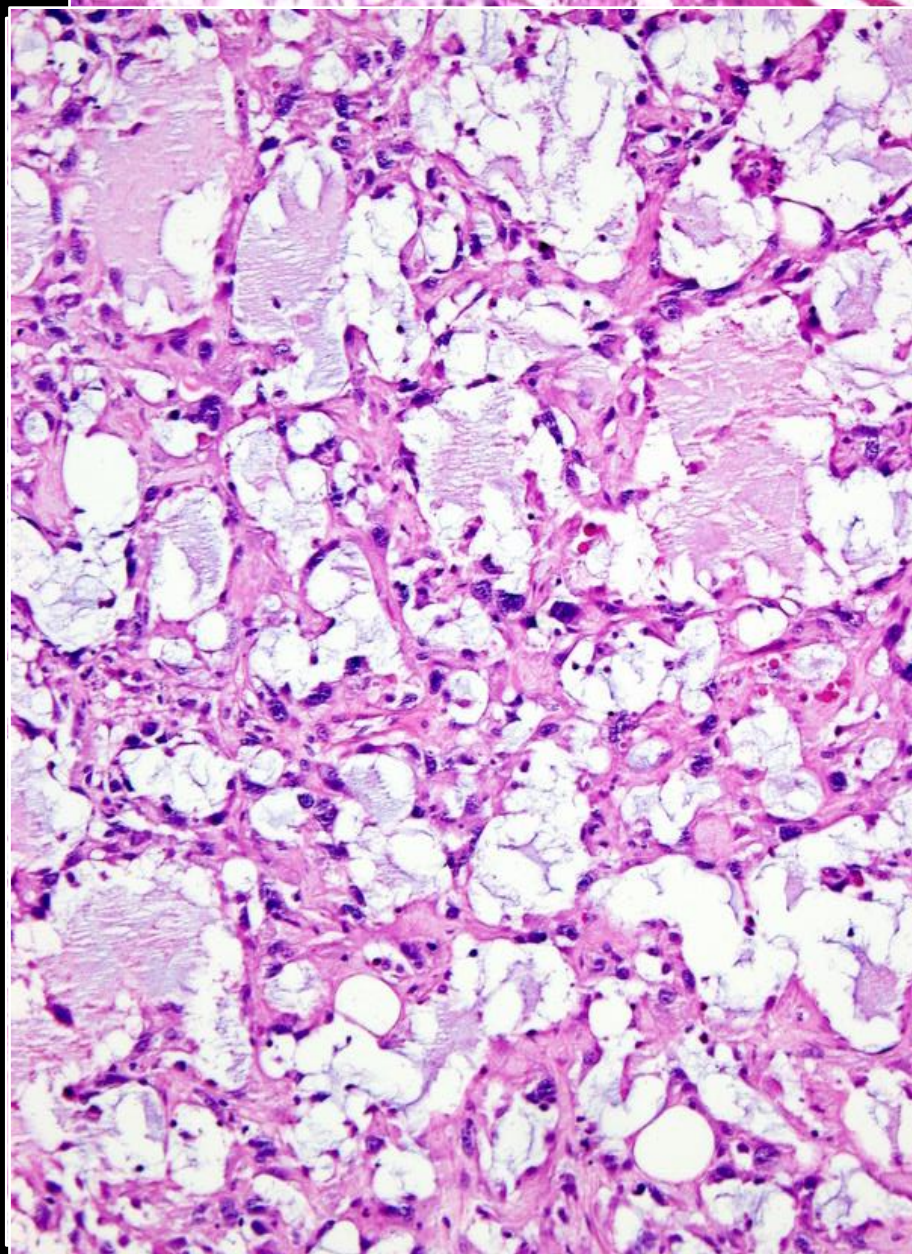
Případ č. 537

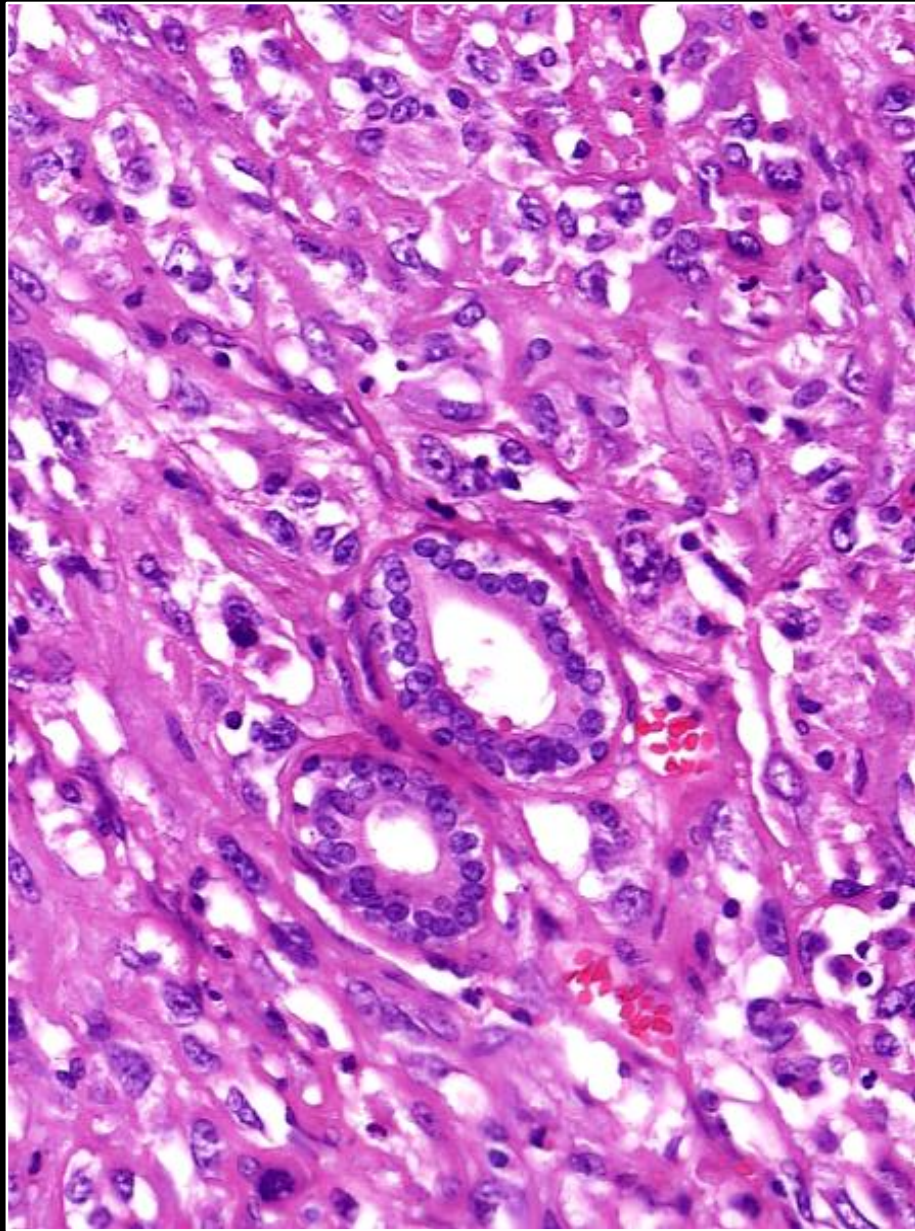
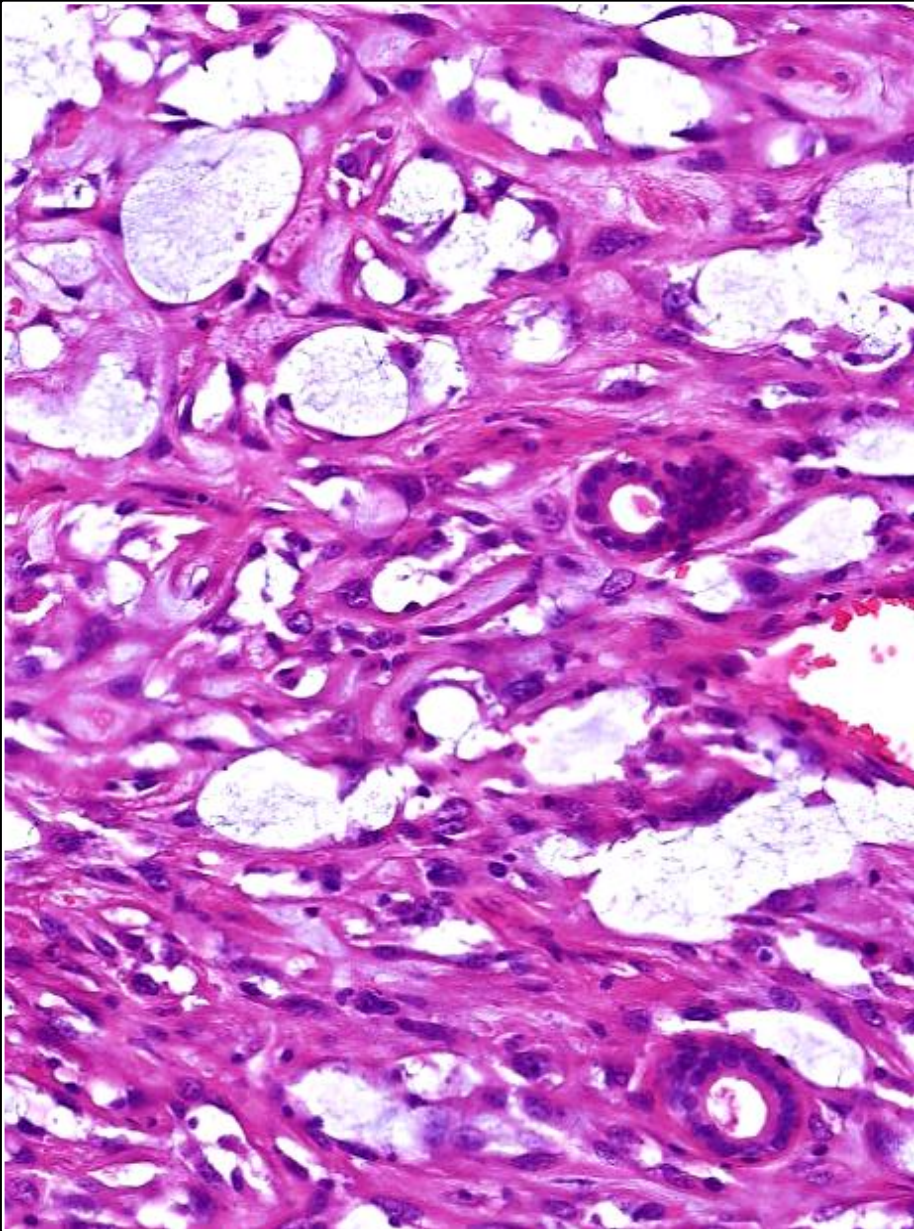
Zdeněk K I N K O R

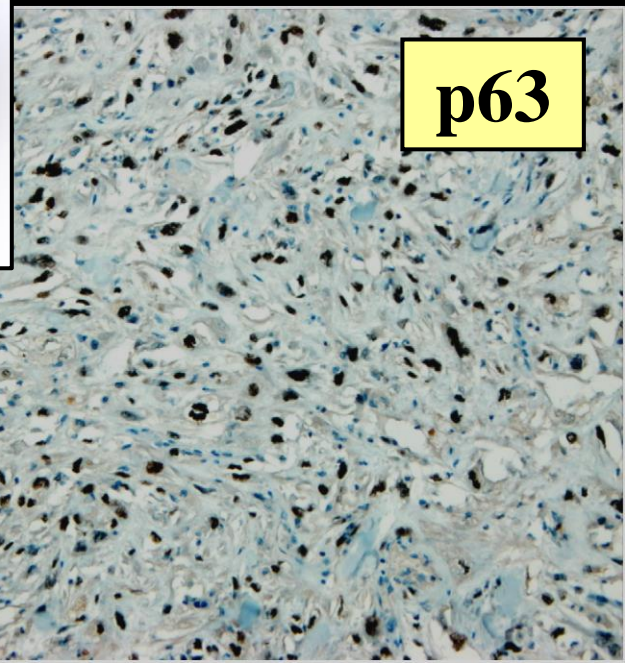

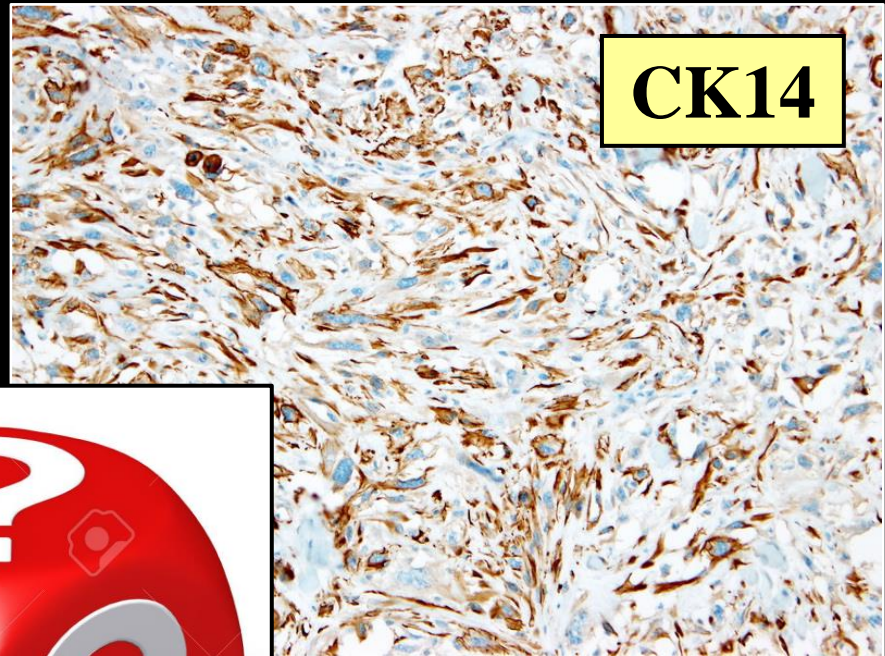
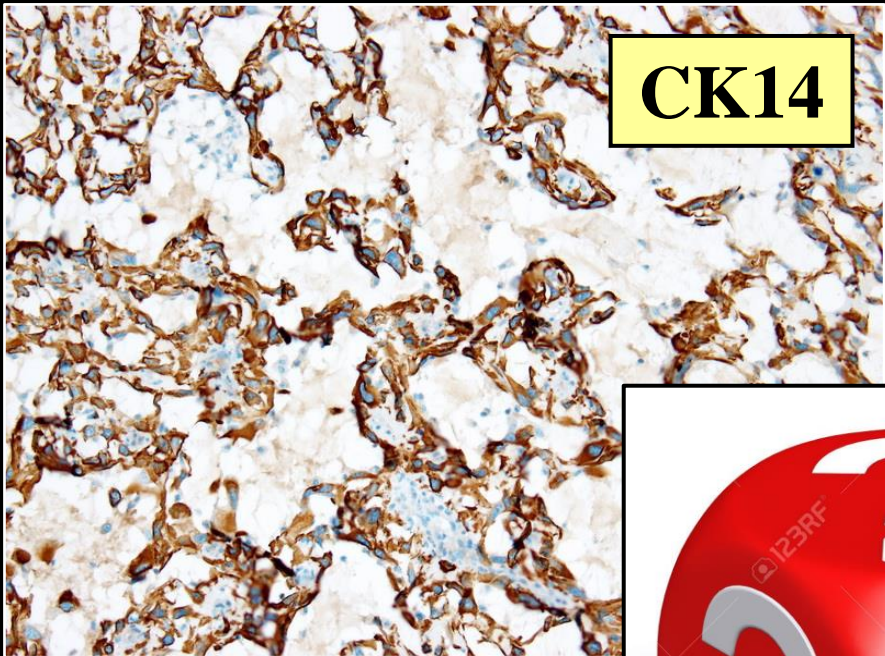


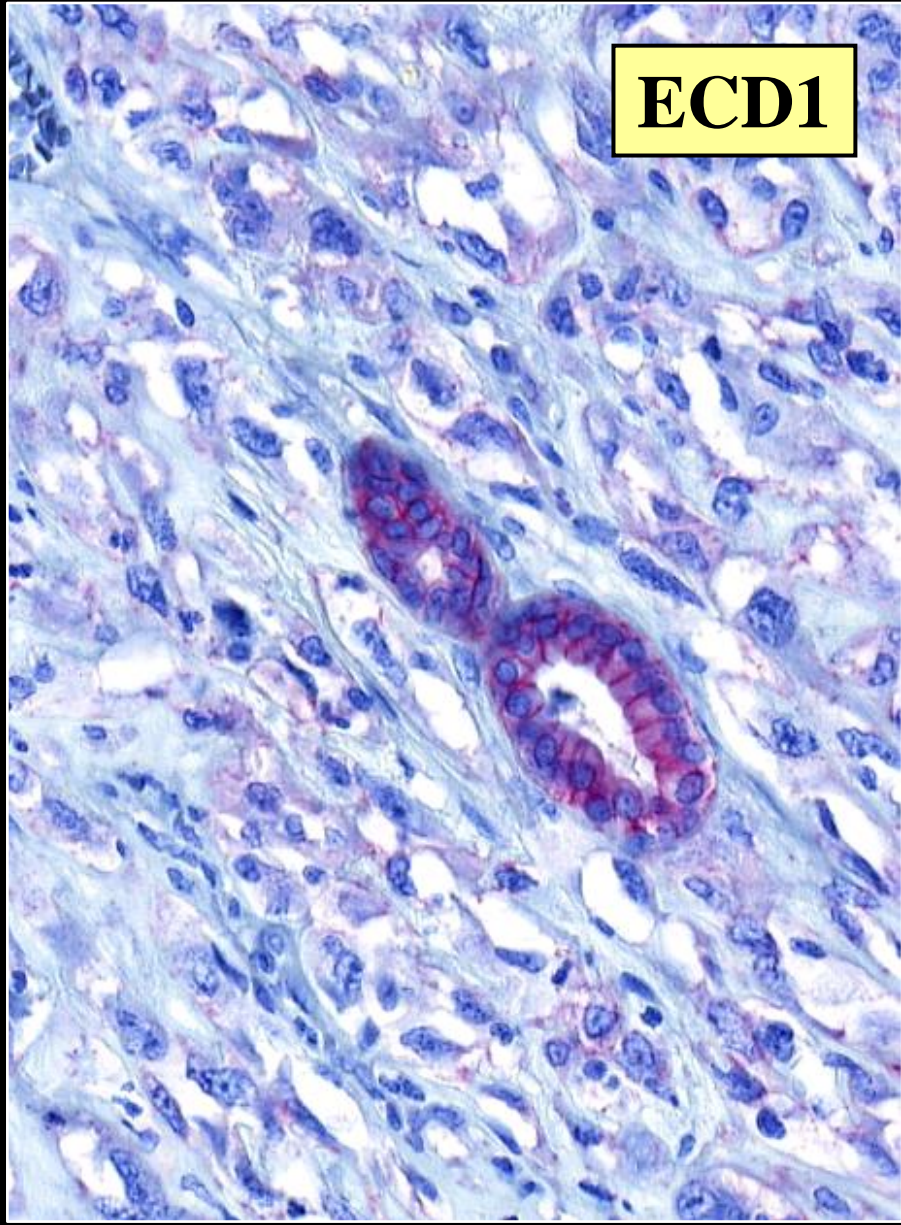
žena 67 let, tumor prsu 5 cm - těsně pod kůží ...

- před 8 lety G2 DCIS - lumpektomie, radiace
- zasílající patolog: v.s. postradiační angiosarkom ?









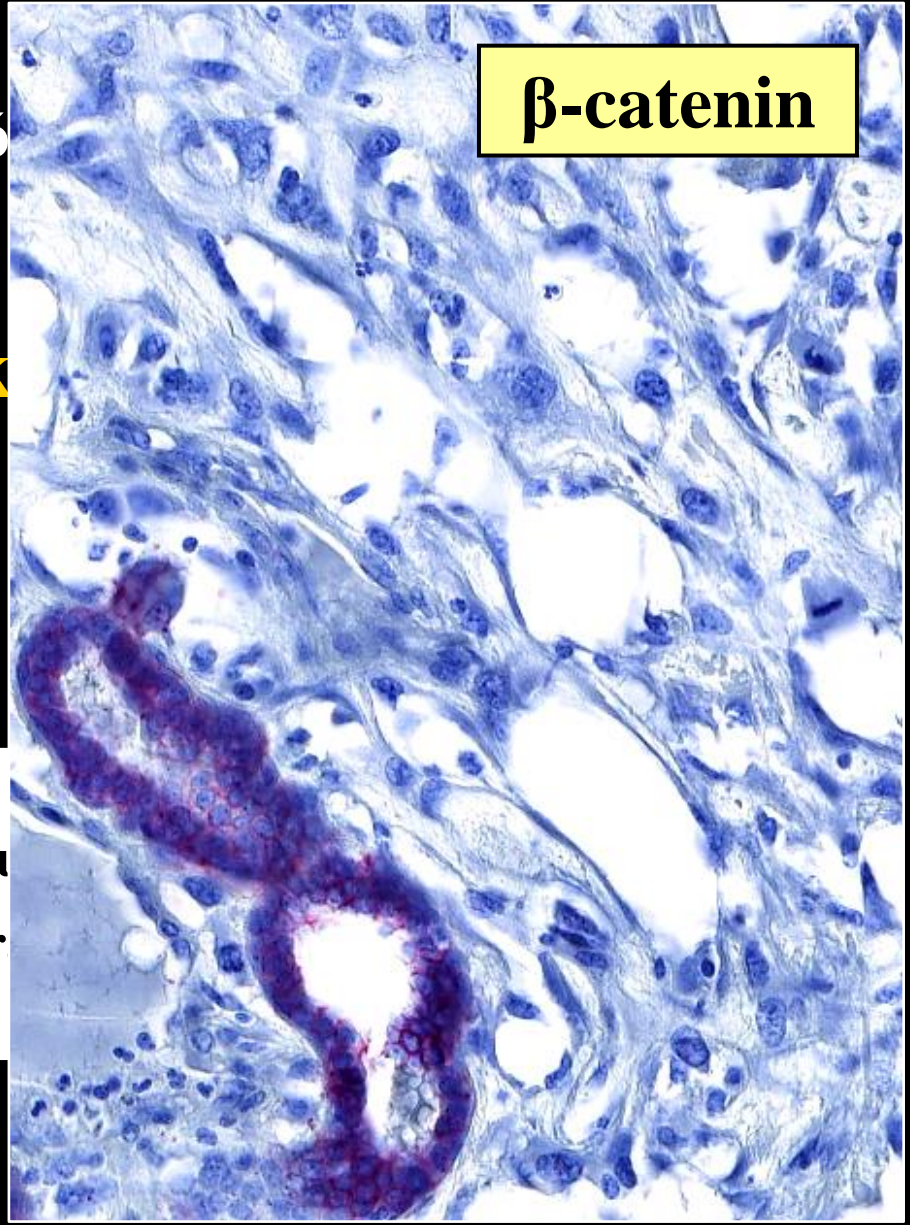
nó

ek

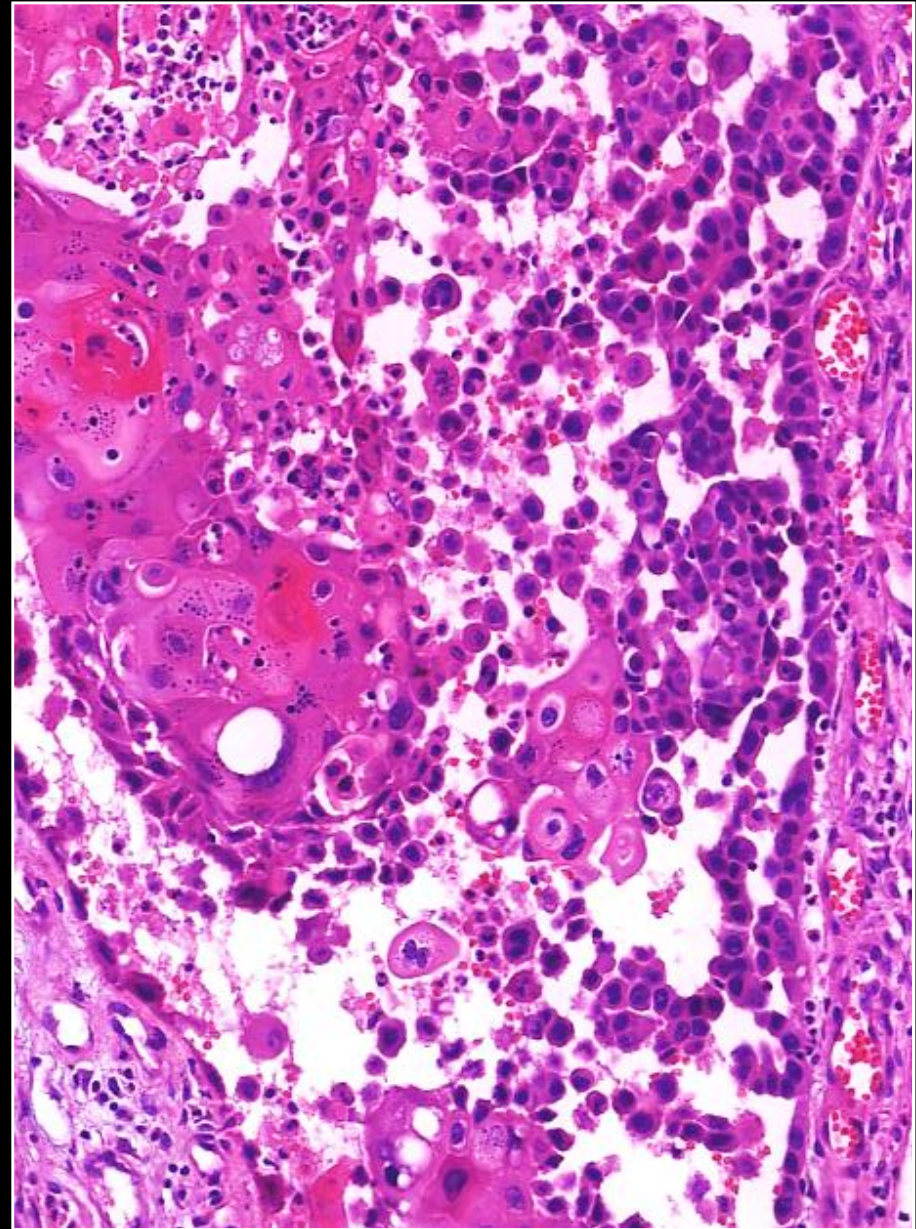
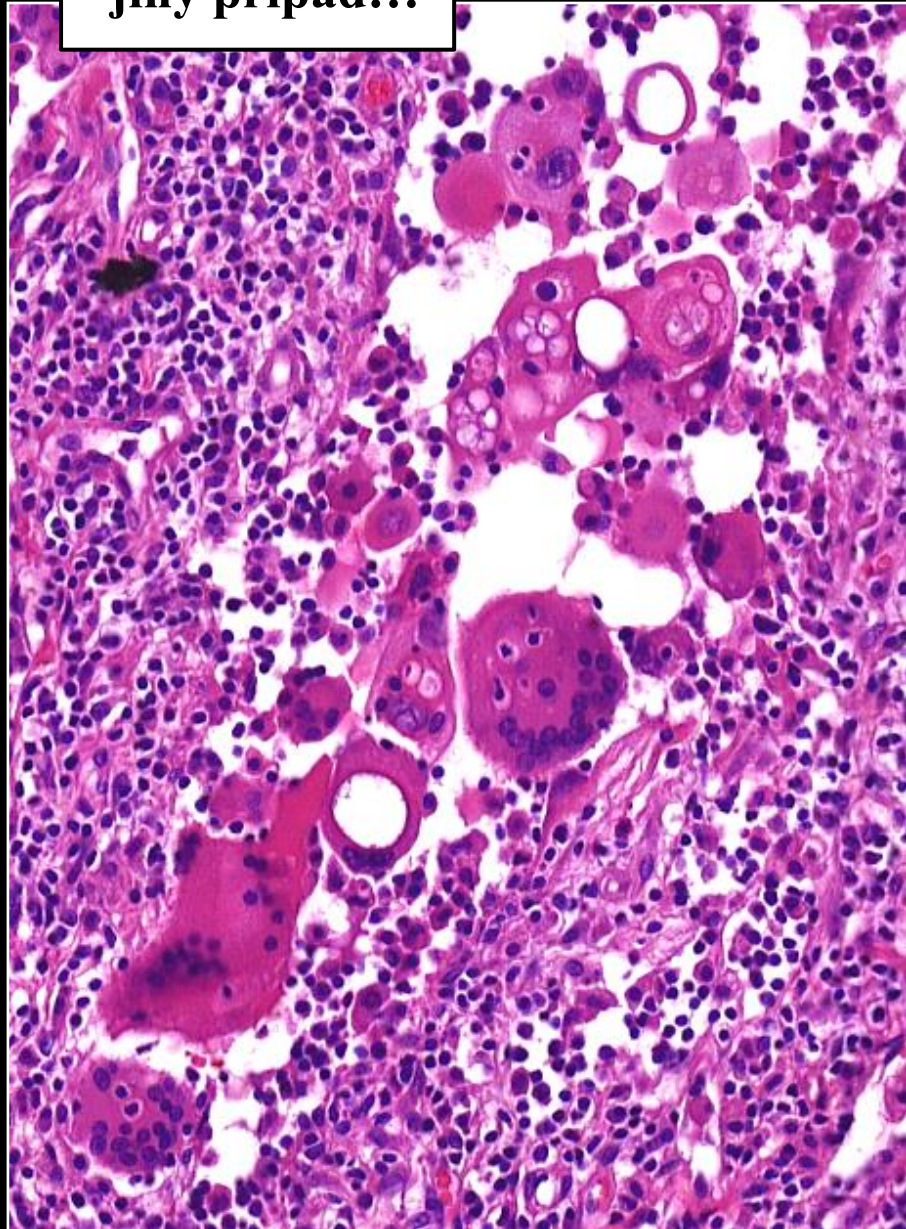
)

nou

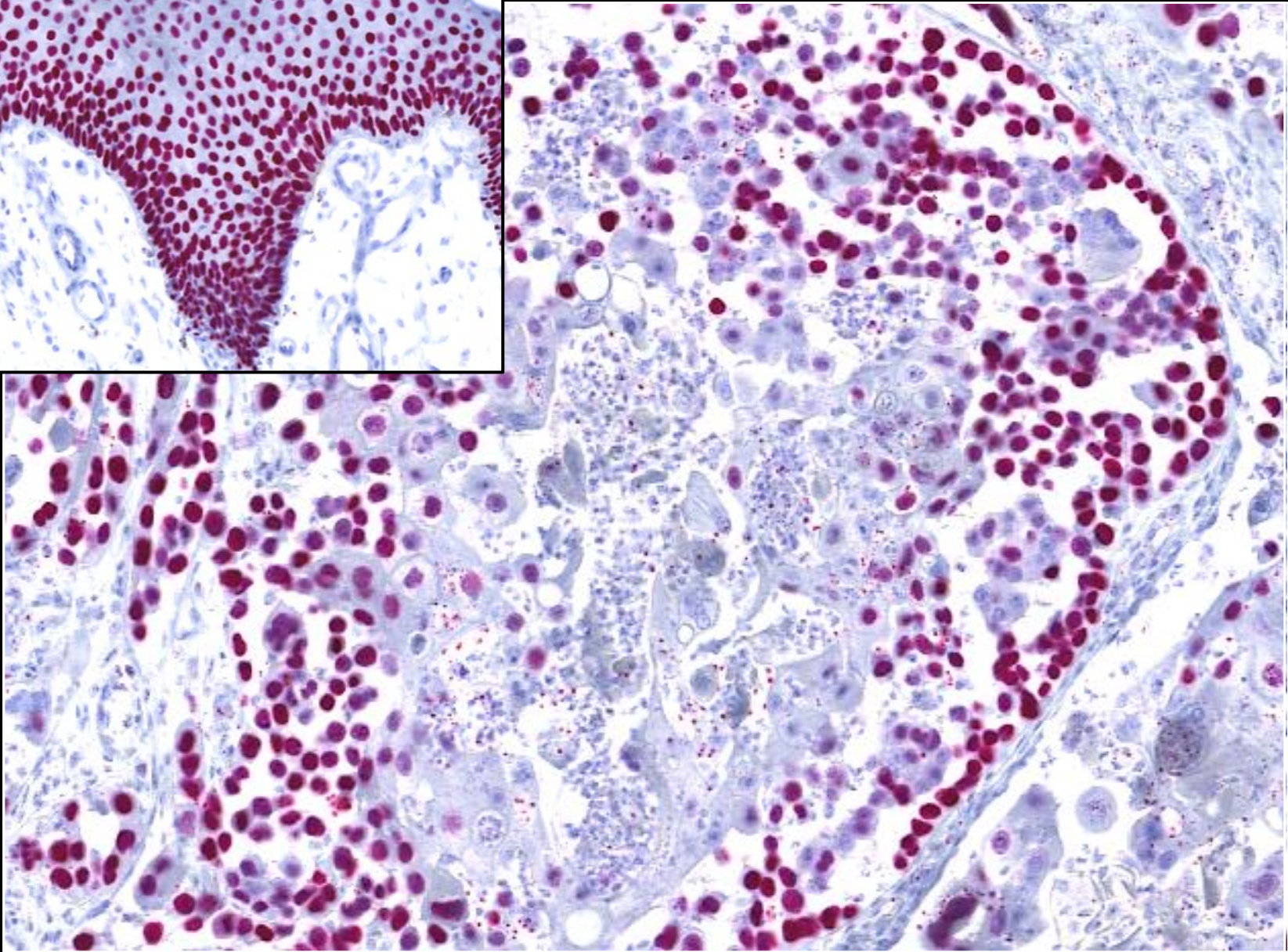
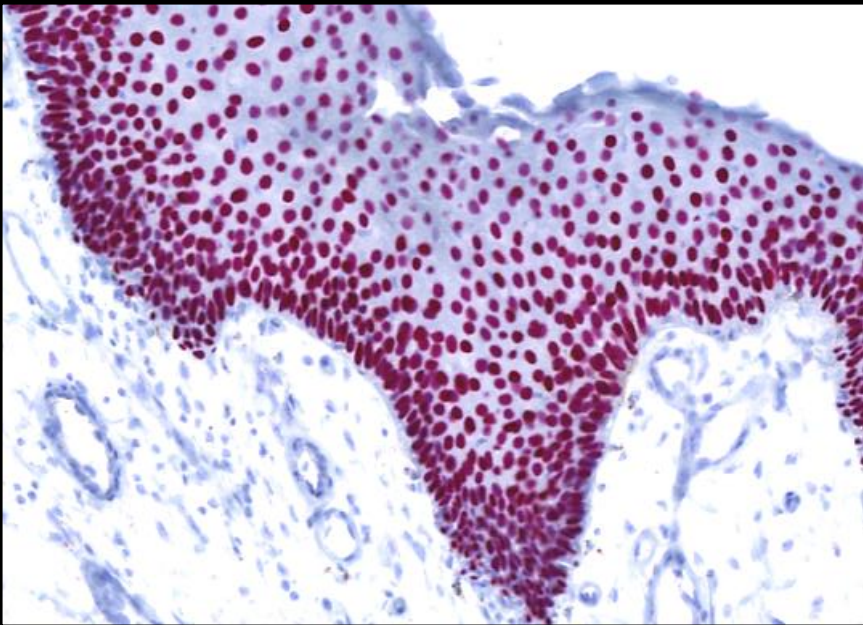
ter



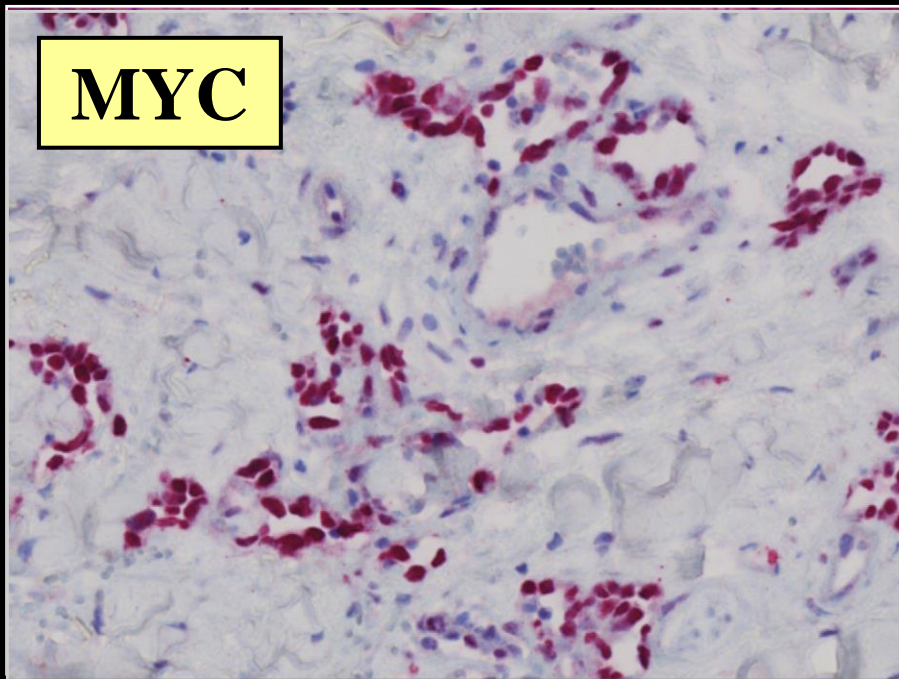
jiný případ...



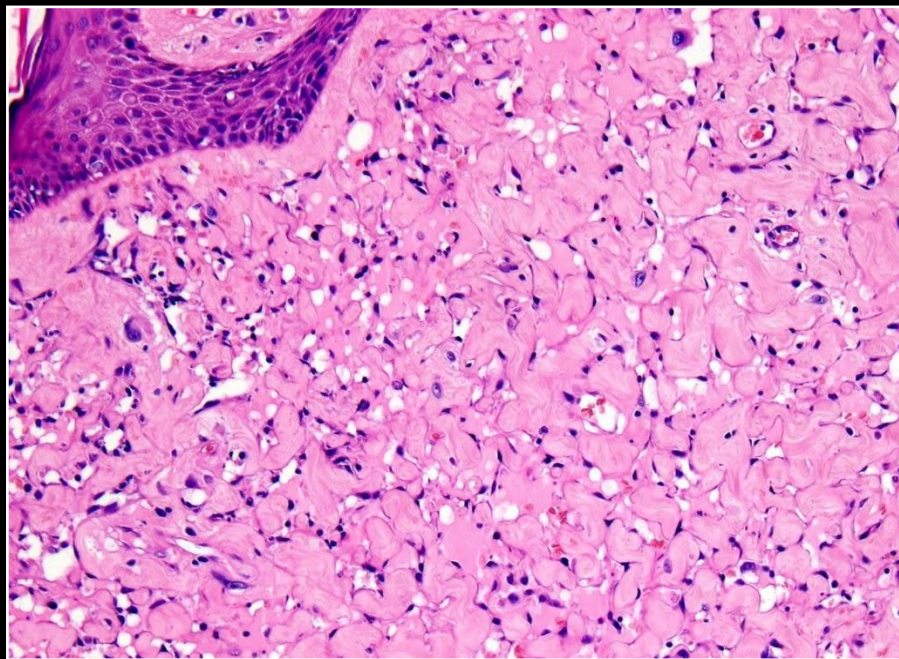
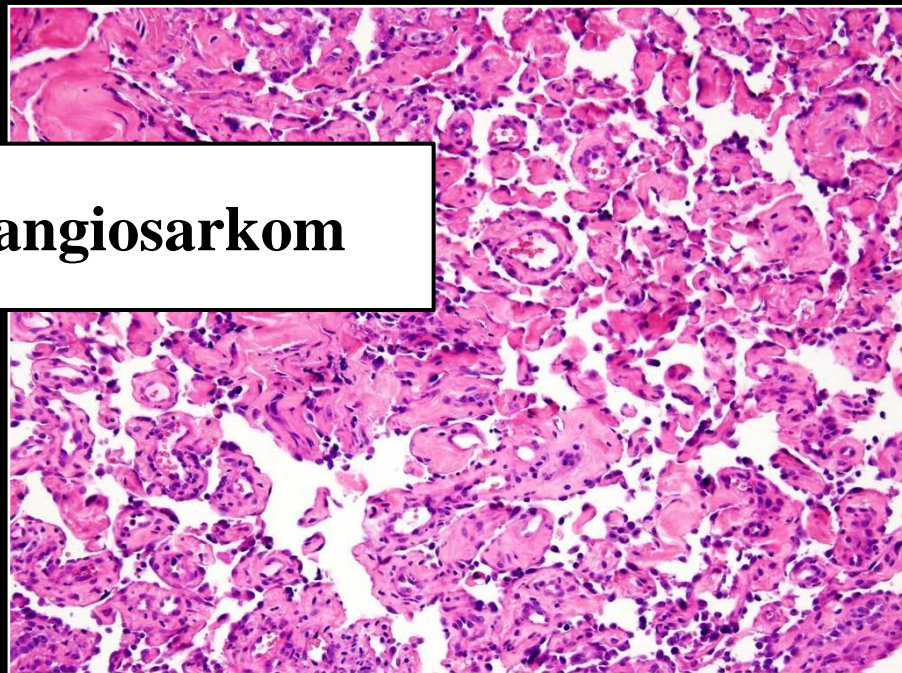p40/p63



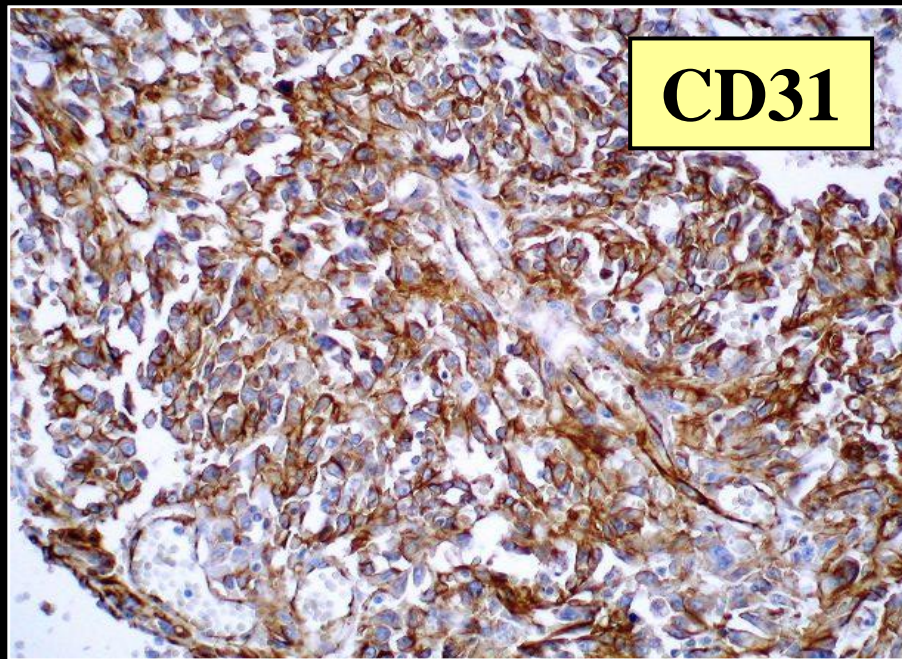
MYC



í angiosarkom

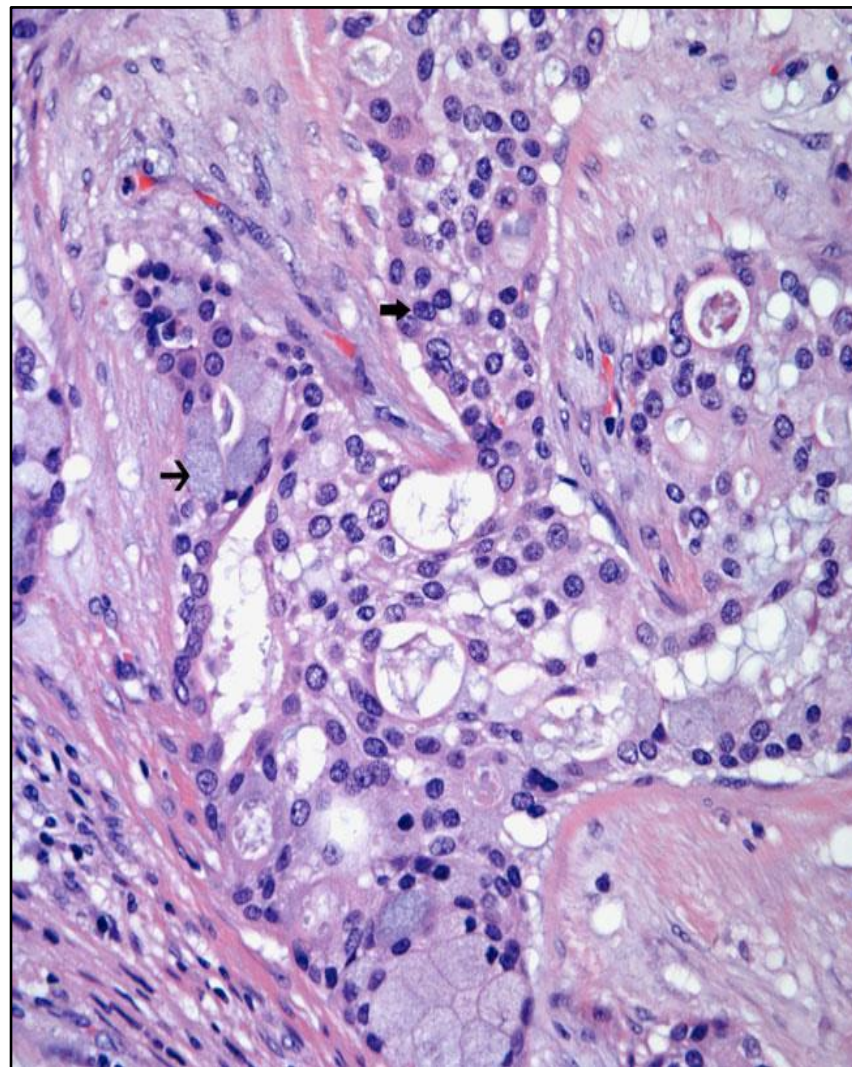


CD31

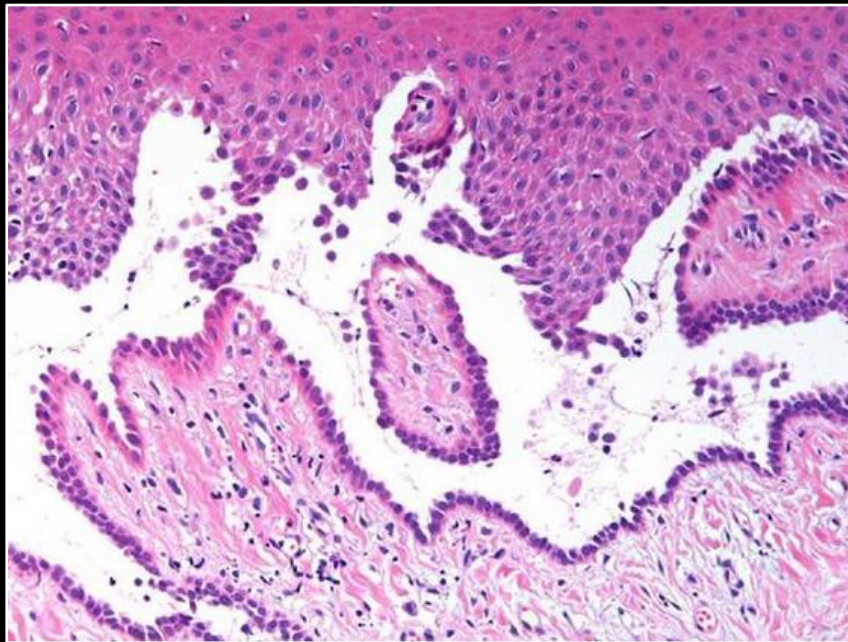
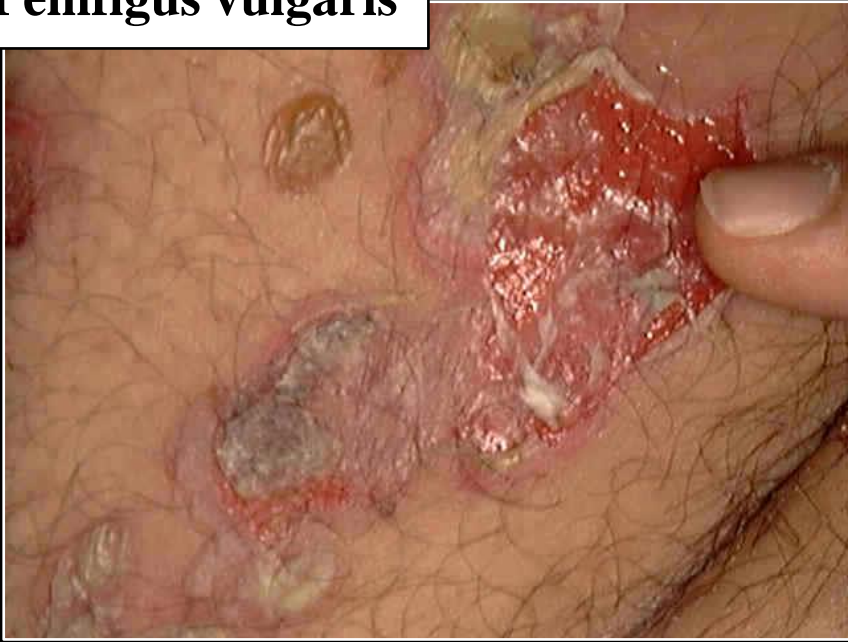

Skvamózní diferenciace v karcinomu prsu

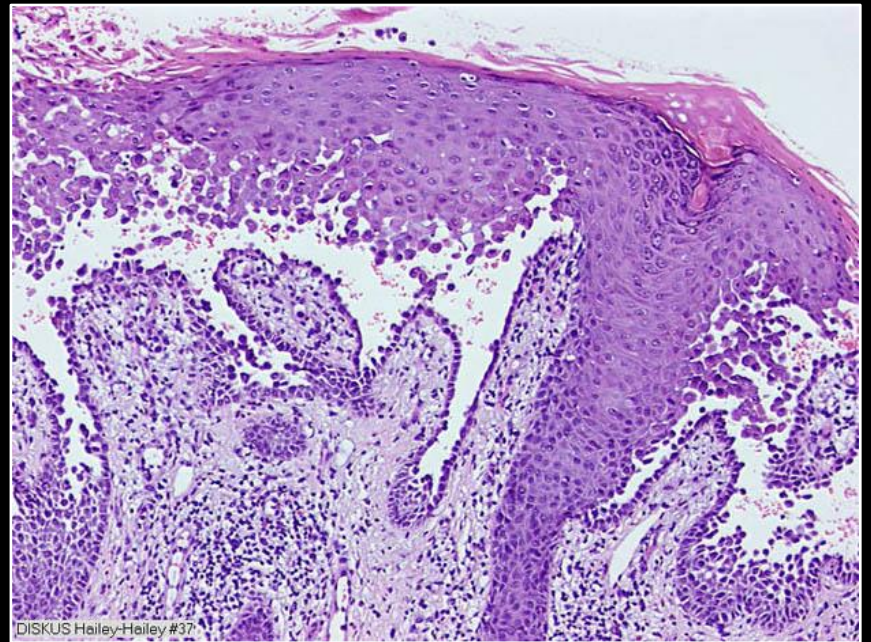
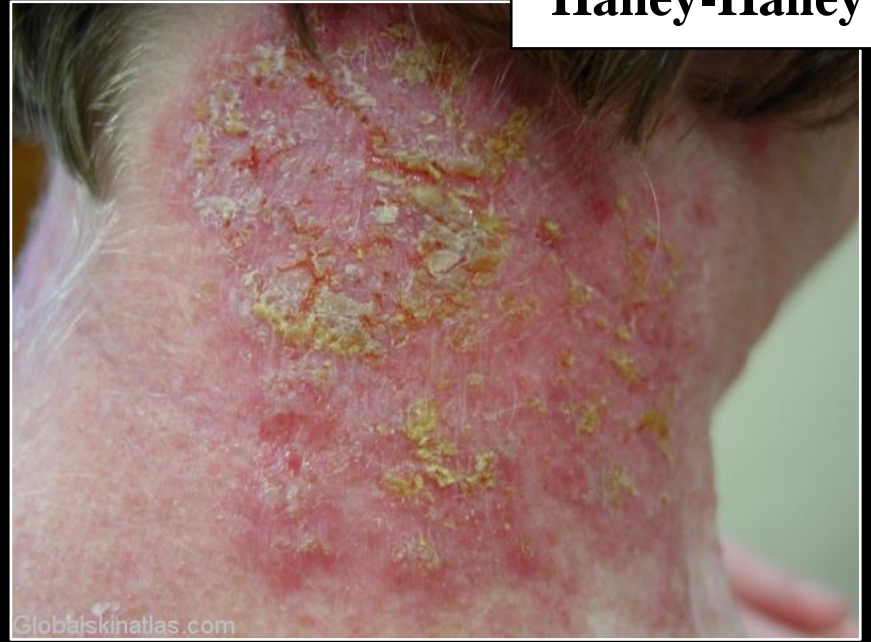- primární čistě skvamózní
- LG adenoskvamózní
- vřetenobuněčný skvamózní
- adenoskvamózní
- akantolytický
- IDC, NST se skvamózní metaplázií
- smíšený „small cell“ / skvamózní
- mukoepidermoidní
- metastatický



Pemfigus vulgaris

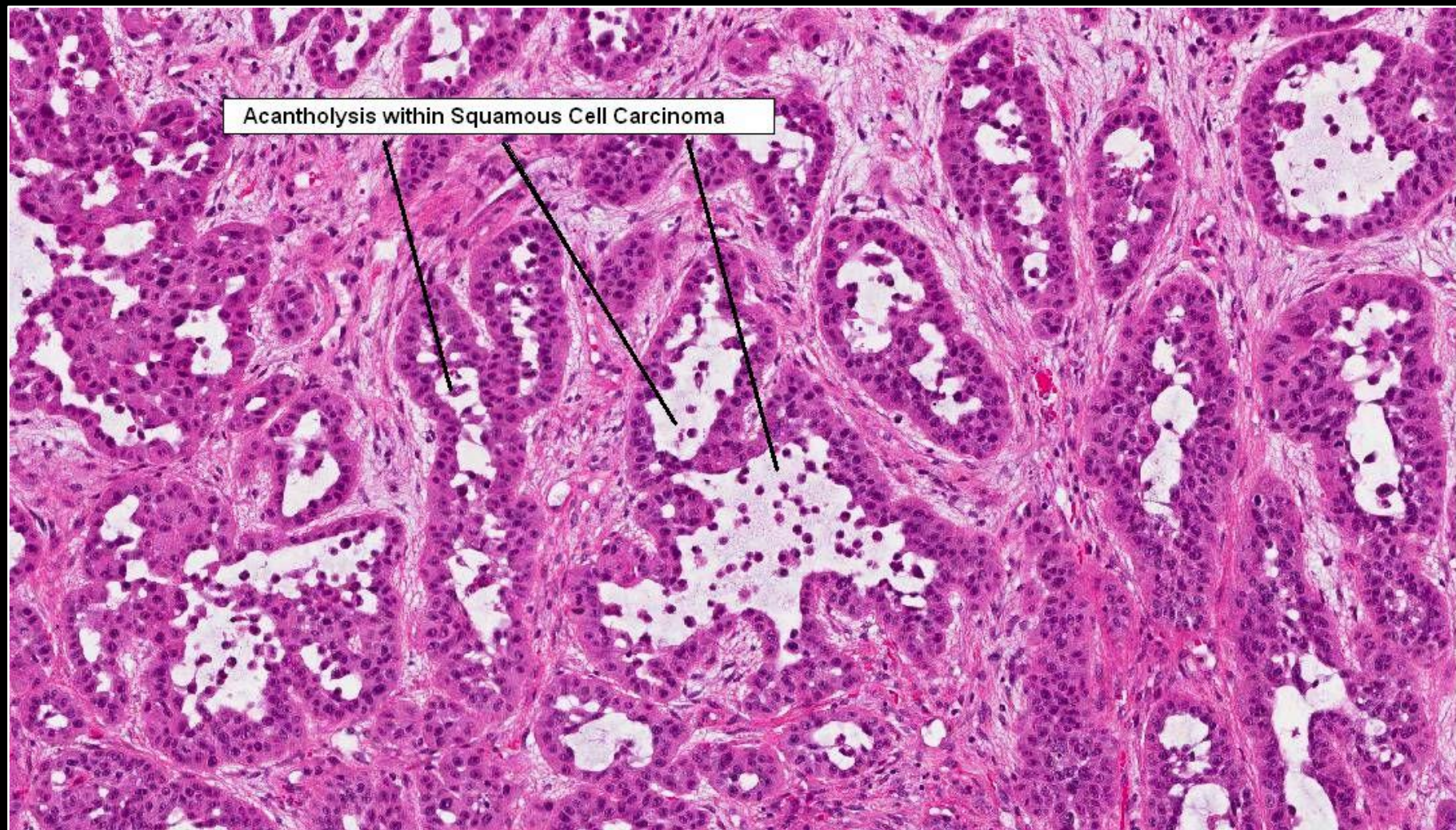


Hailey-Hailey





Akantolytický skvamózní CA napodobující adenokarcinom...





Hlavou zed' neprorazíš,
ale můžeš přijít na zajímavé myšlenky . . .