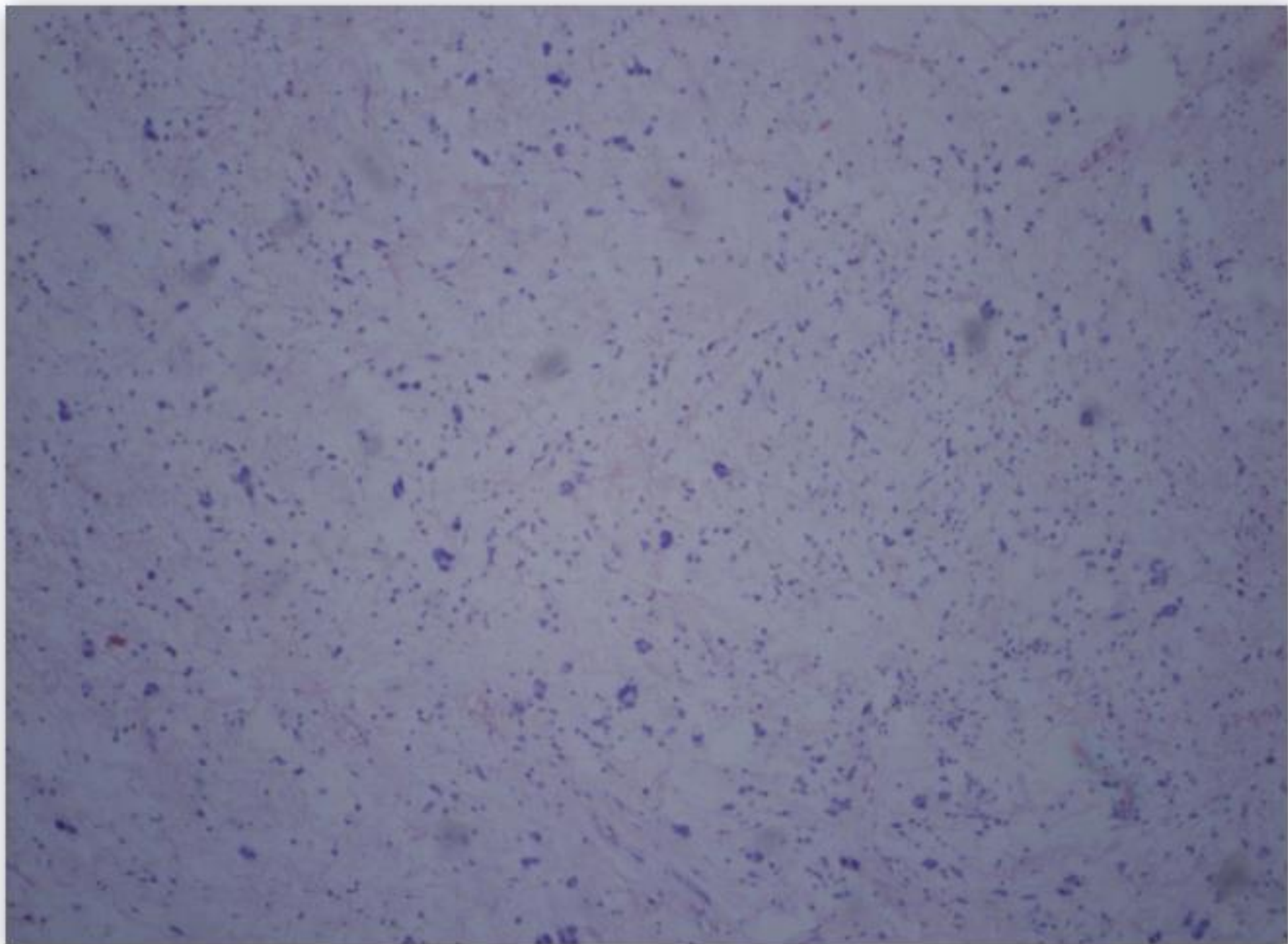
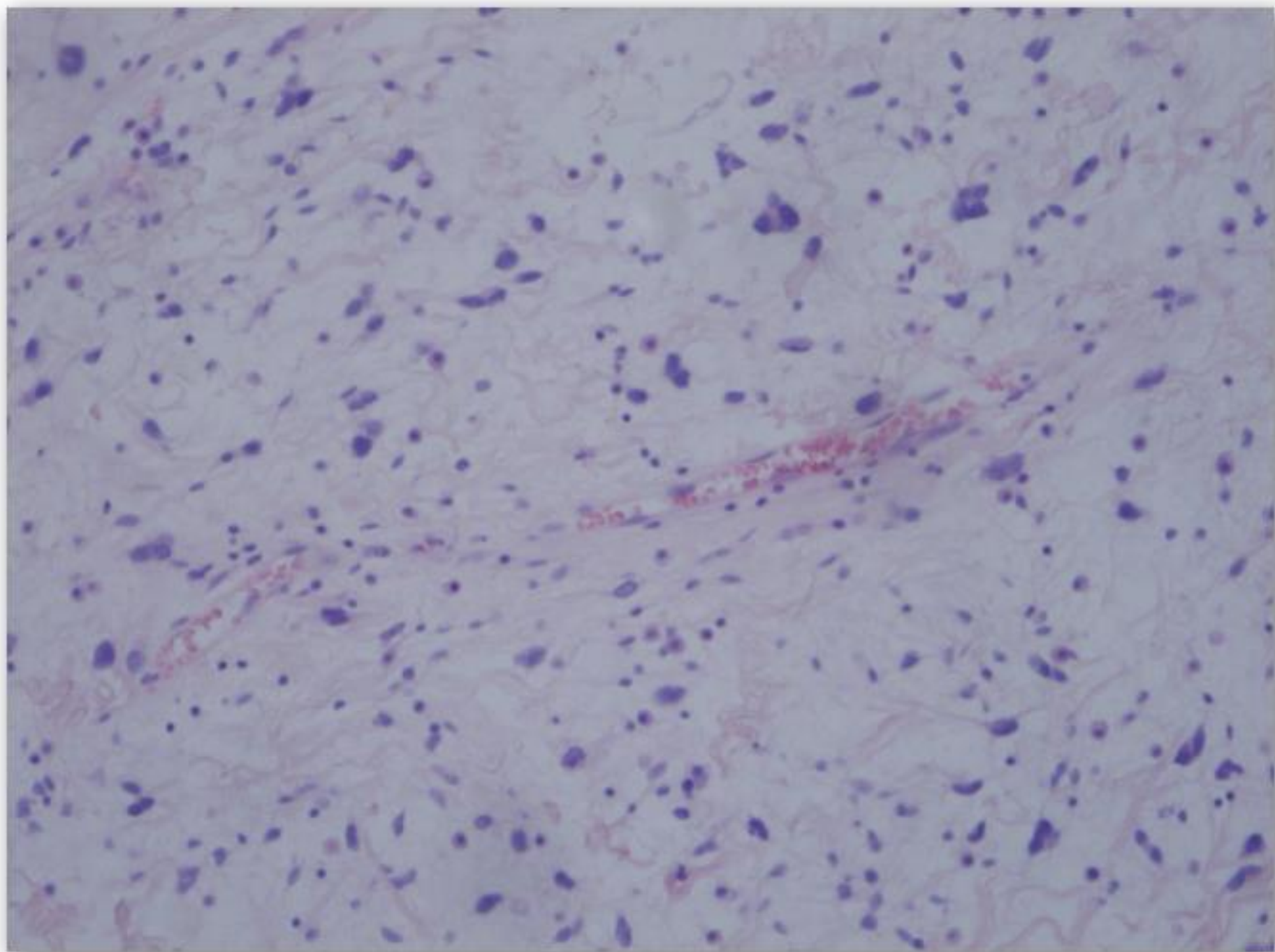


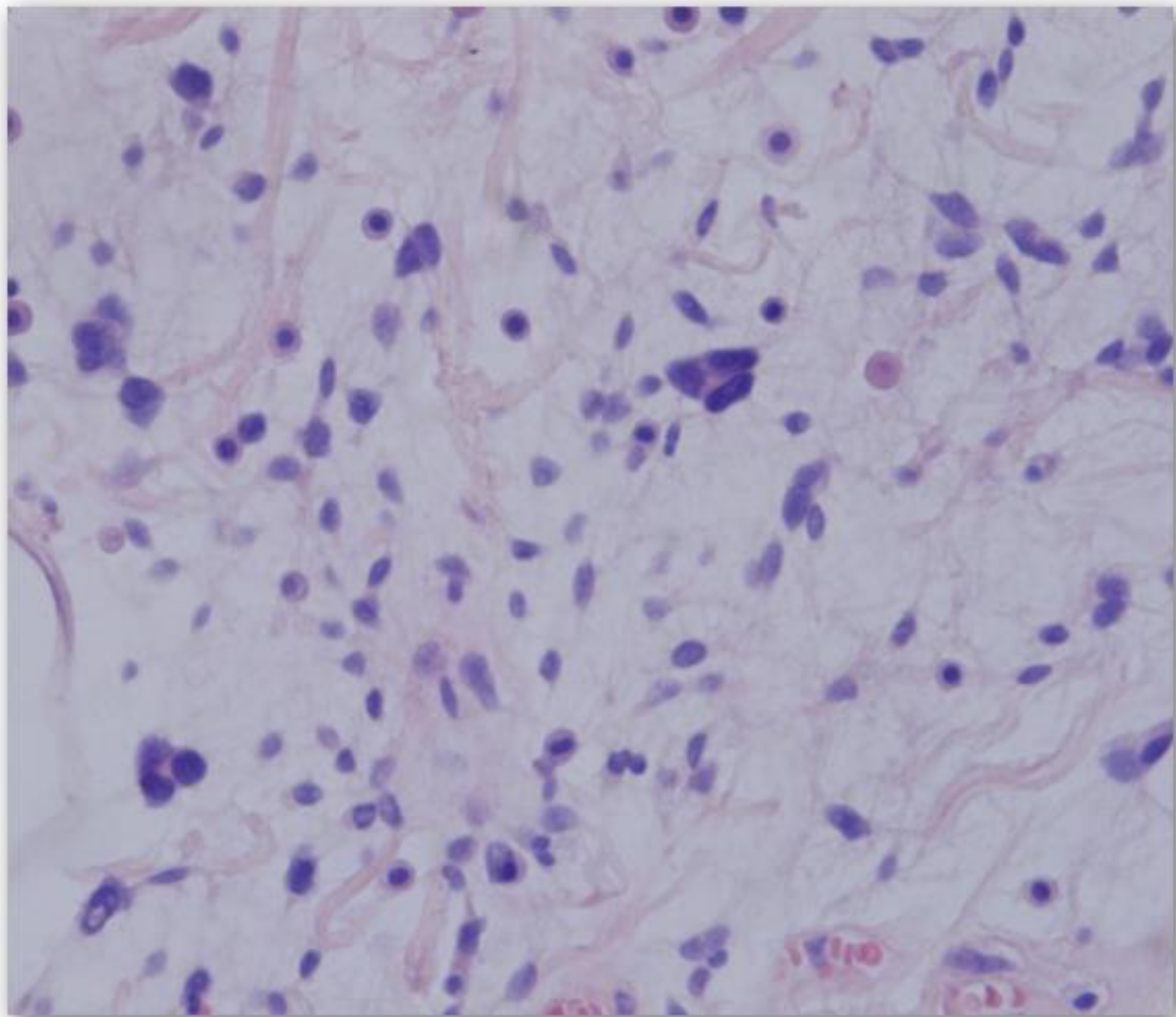
Prípád SD-IAP č. 529

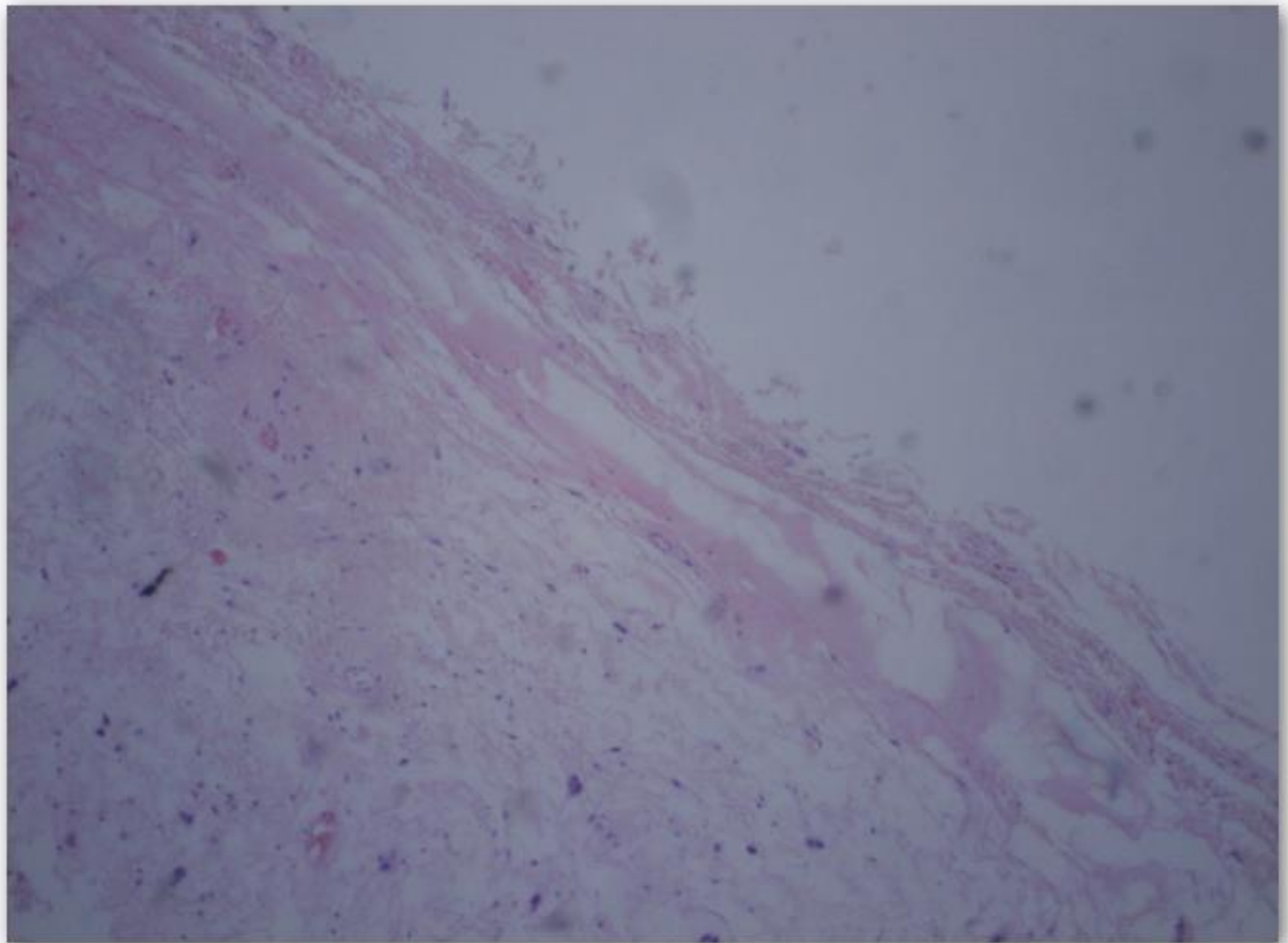
P.Talarčík, Cytopathos, Bratislava

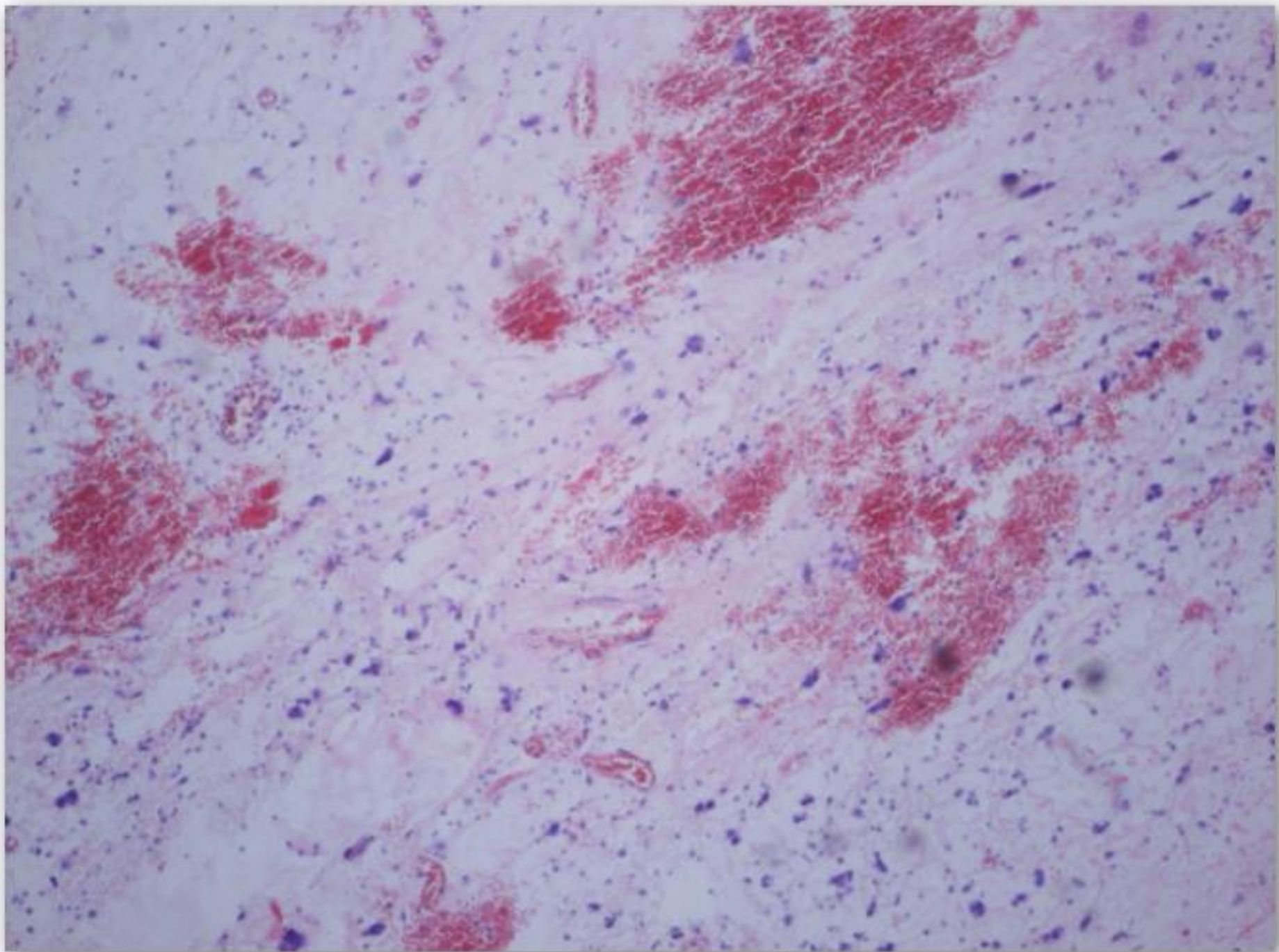


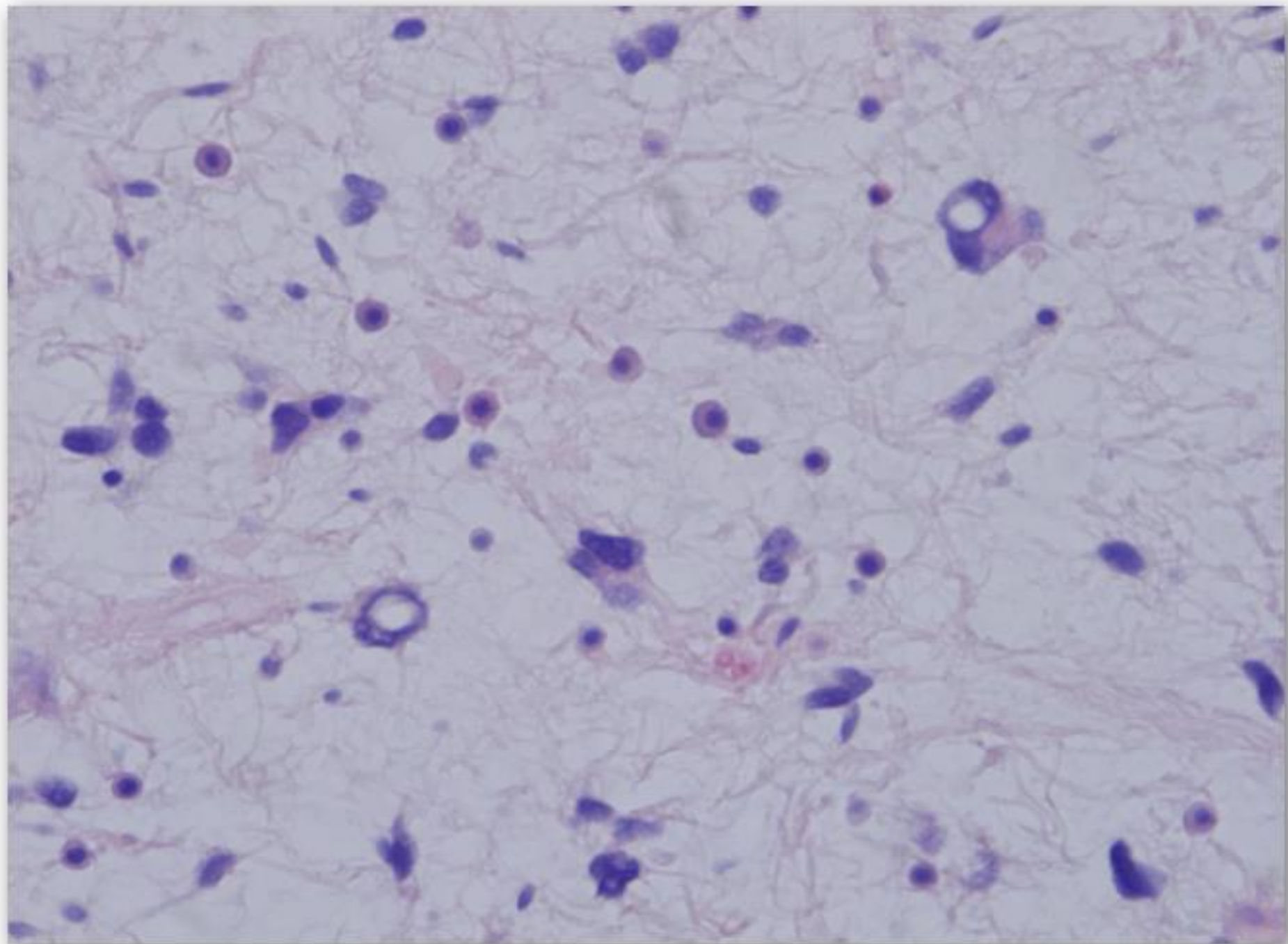


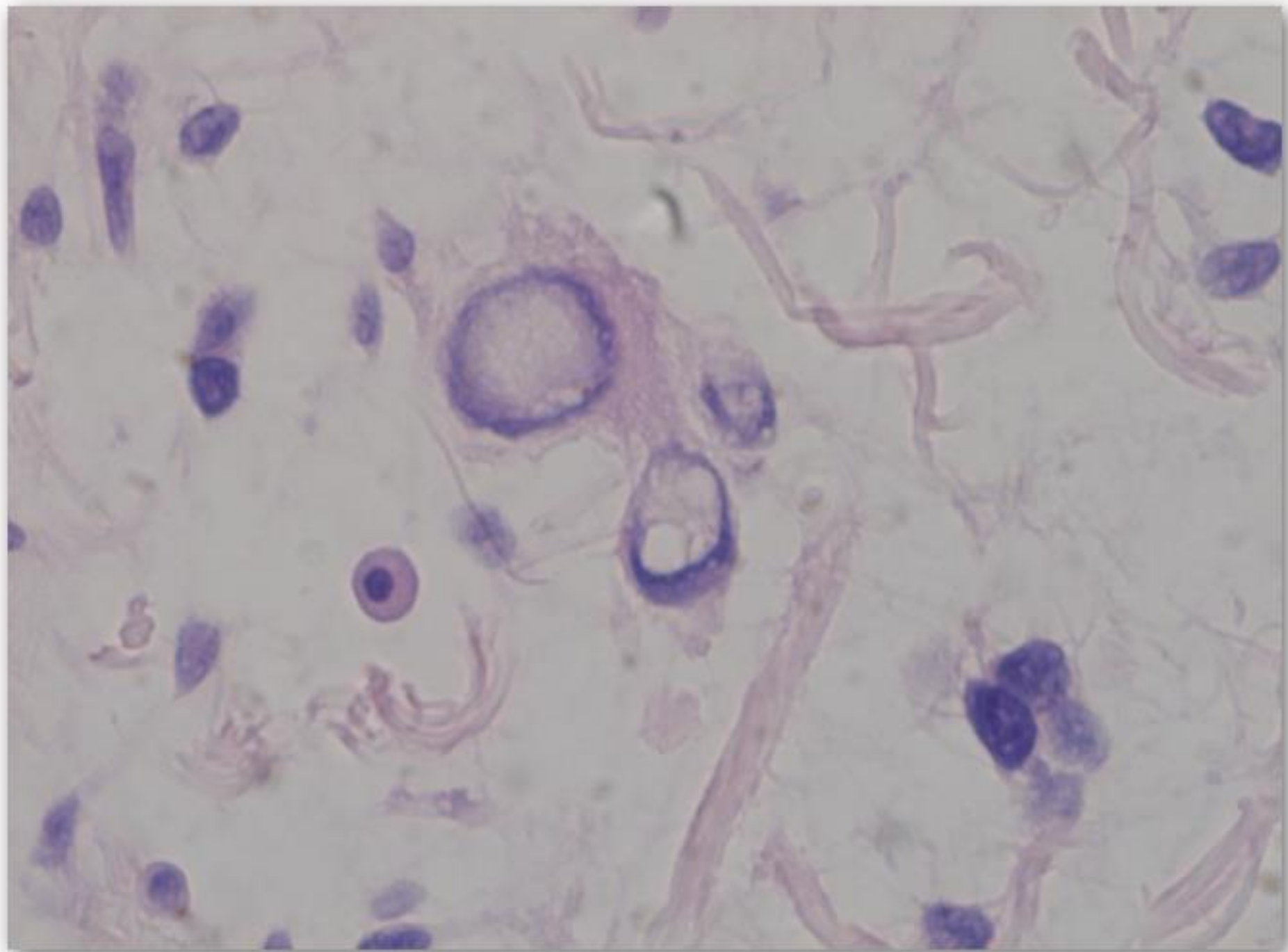


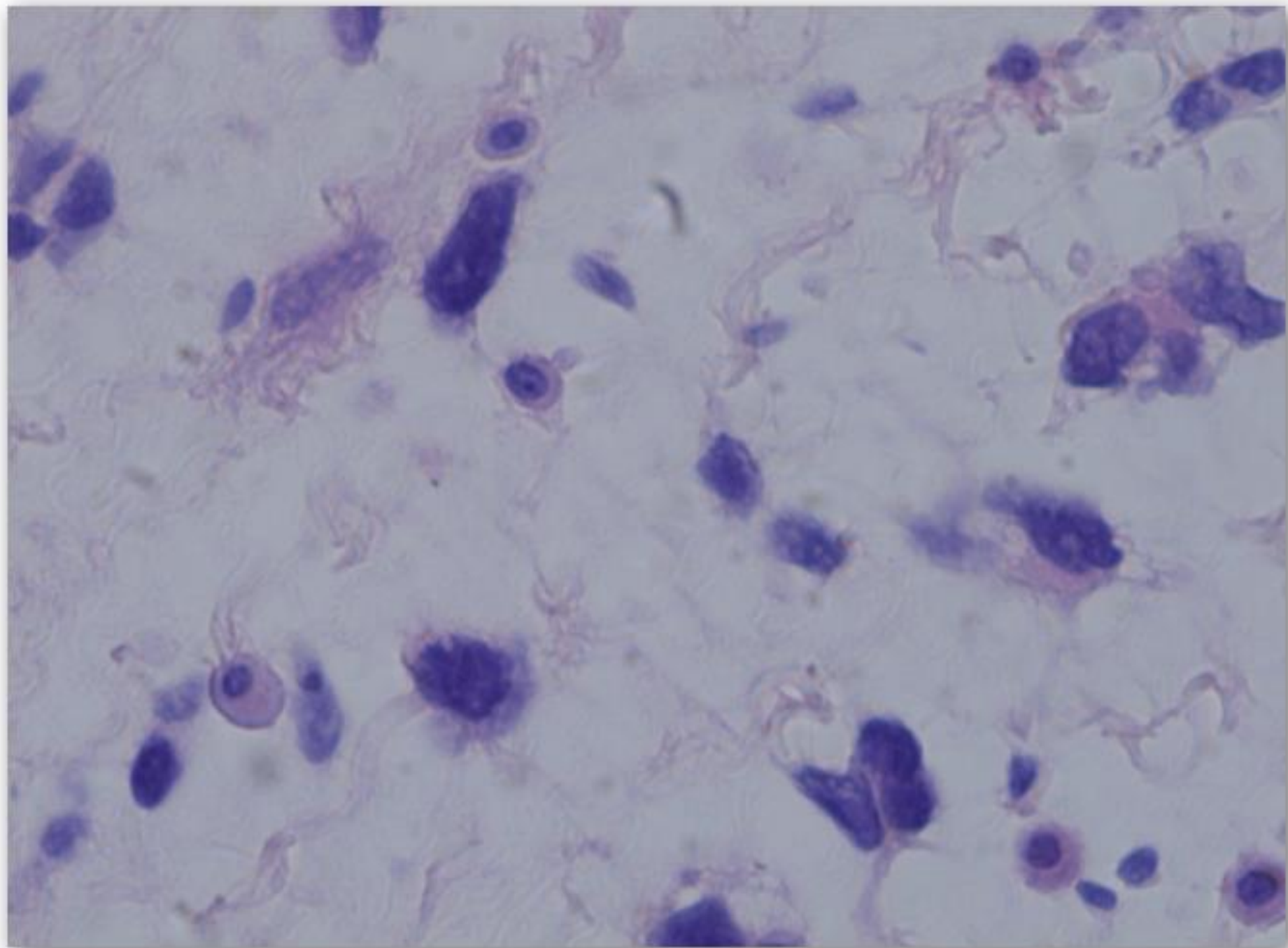


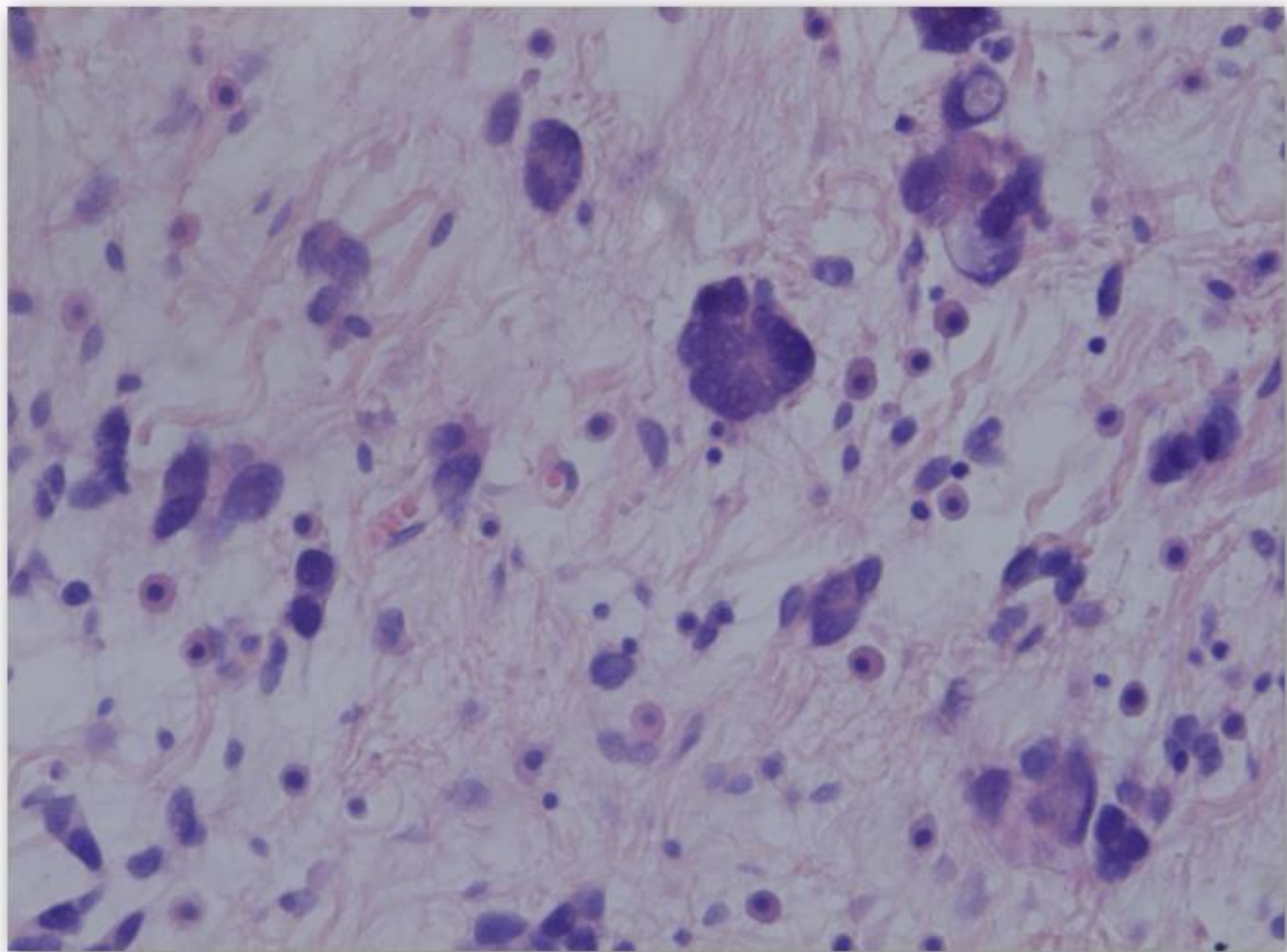


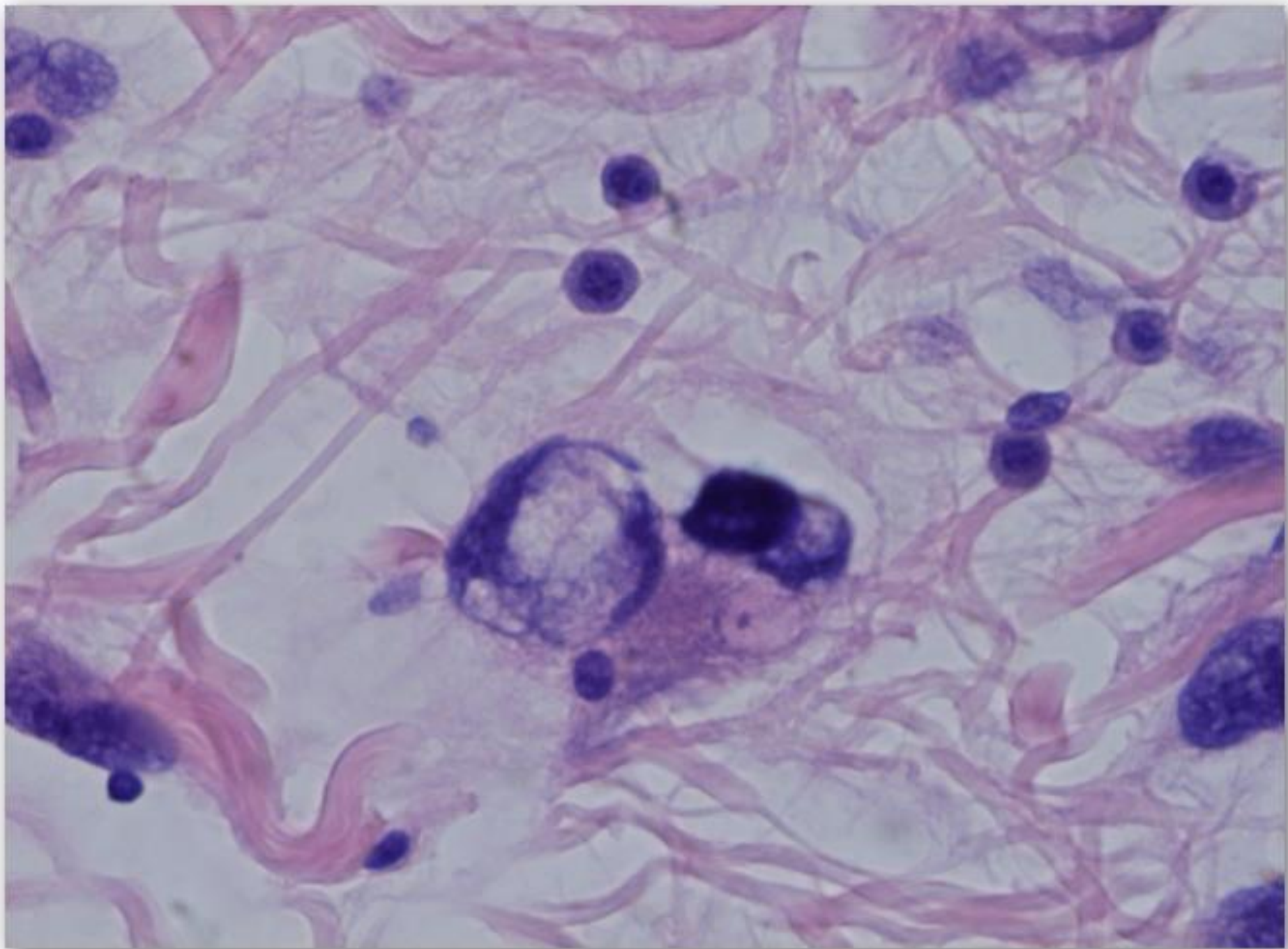


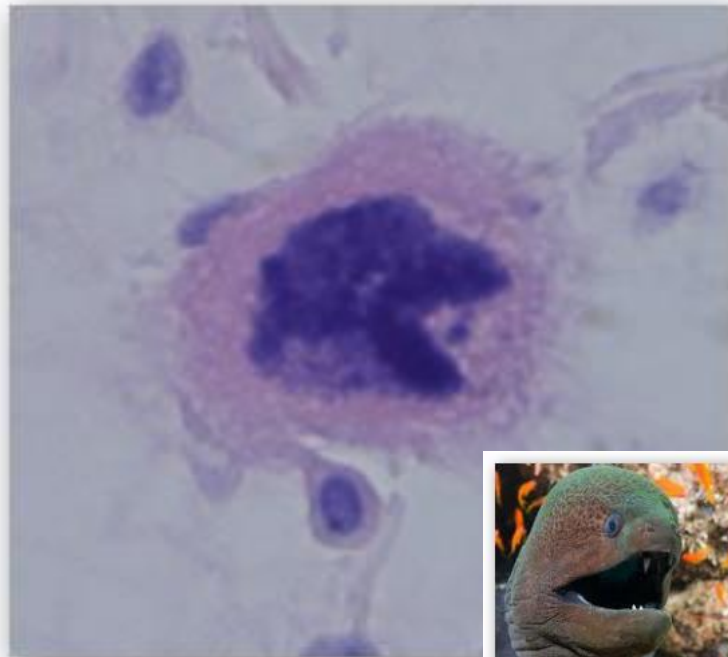
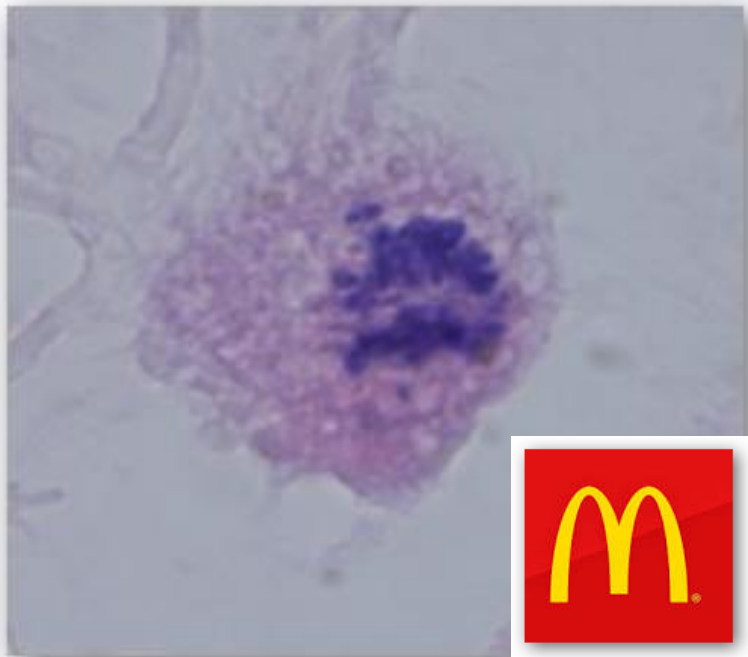
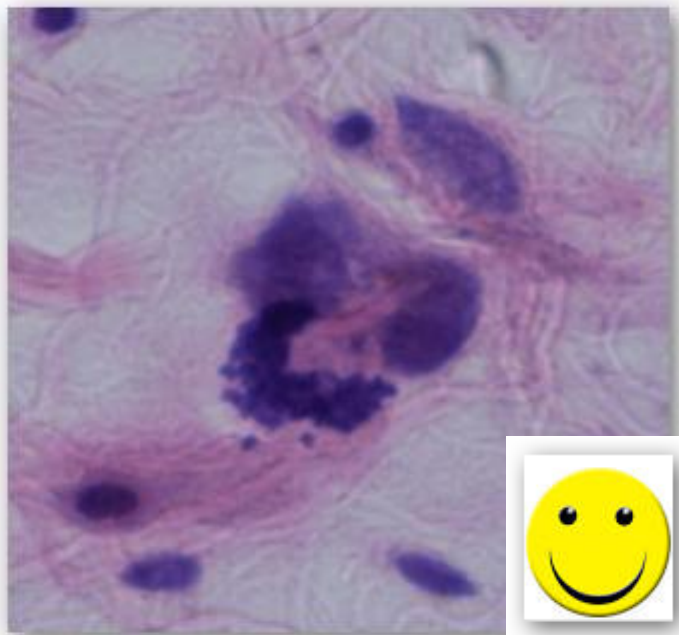


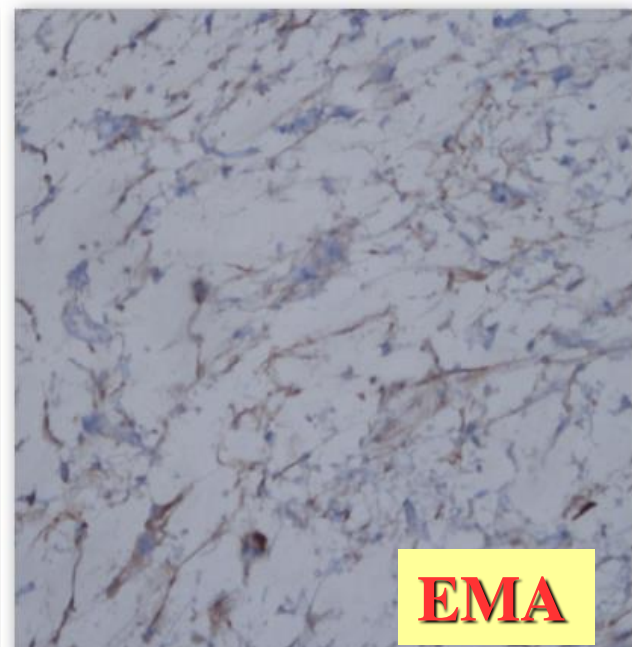
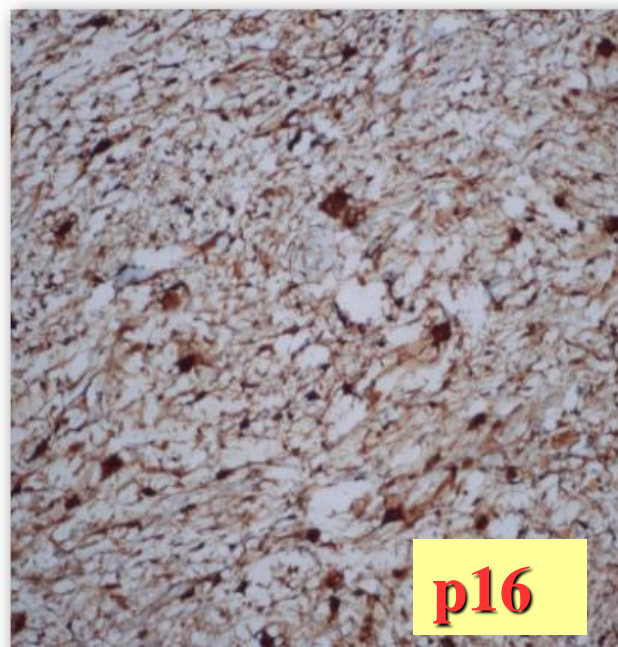
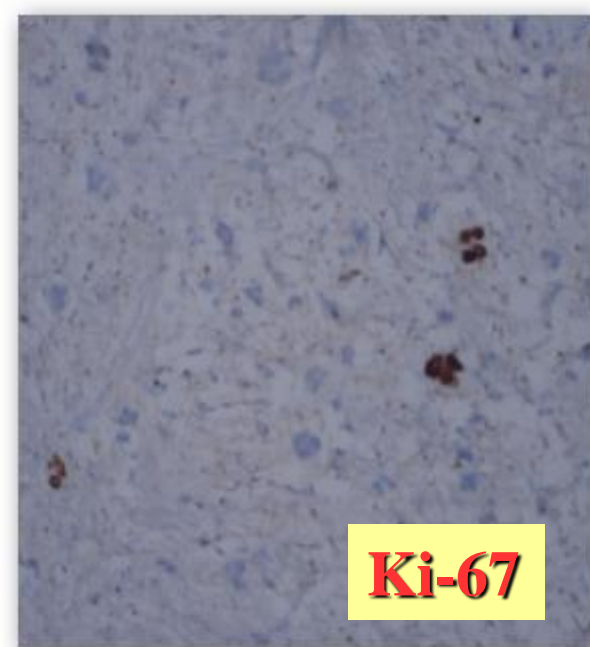
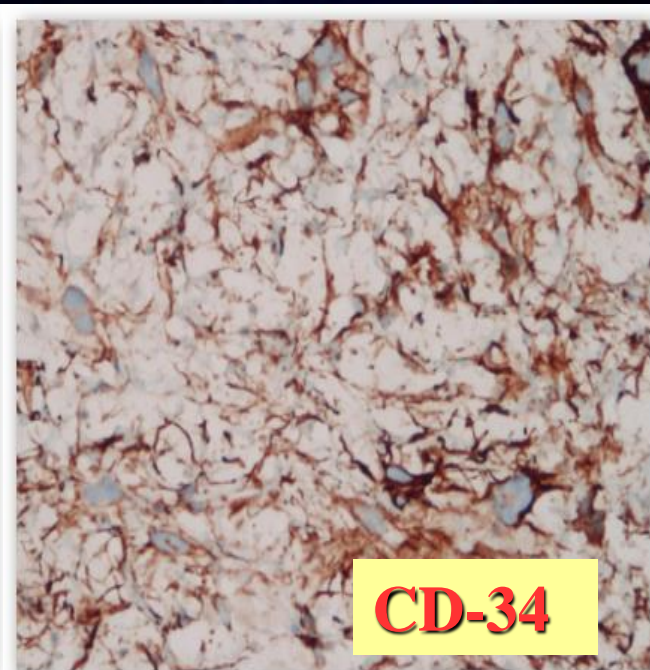
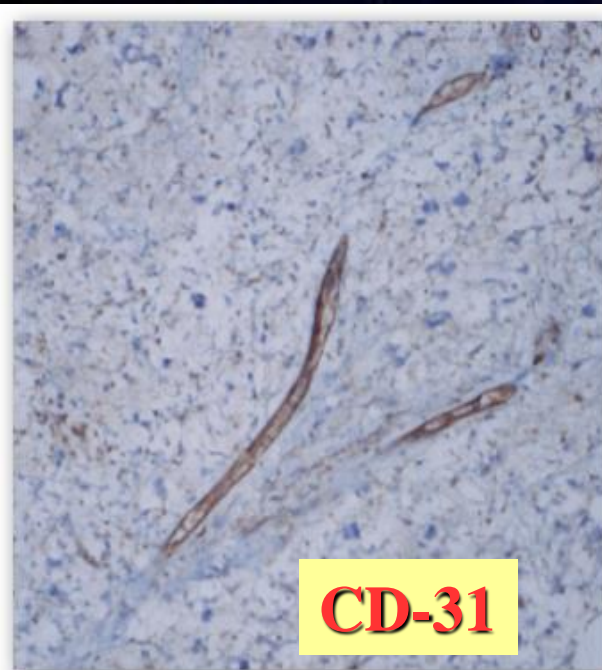
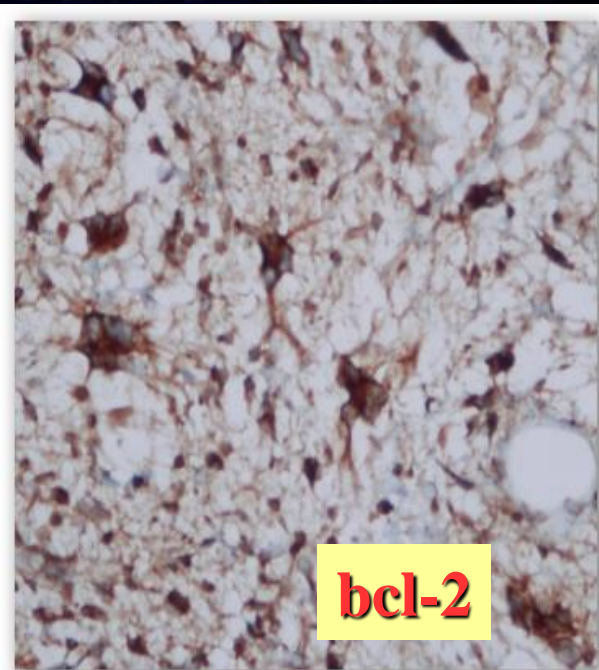












**FAT-FREE MYXOID
PLEOMORPHIC LIPOMA.
*/low-fat/***

Low-Fat and Fat-Free Pleomorphic Lipomas: A Diagnostic Challenge

Mandi P. Sachdeva, MD, John R. Goldblum, MD,† Brian P. Rubin, MD, PhD,† and Steven D. Billings, MD*†*

Pleomorphic lipoma lacking mature fat component in extensive myxoid stroma: a great diagnostic challenge

Xu-Yong Lin^{1,2}, Yan Wang^{1,2}, Yang Liu^{1,2}, Ying Sun³, Yuan Miao^{1,2}, Yong Zhang^{1,2}, Juan-Han Yu^{1,2} and En-Hua Wang^{1,2*}

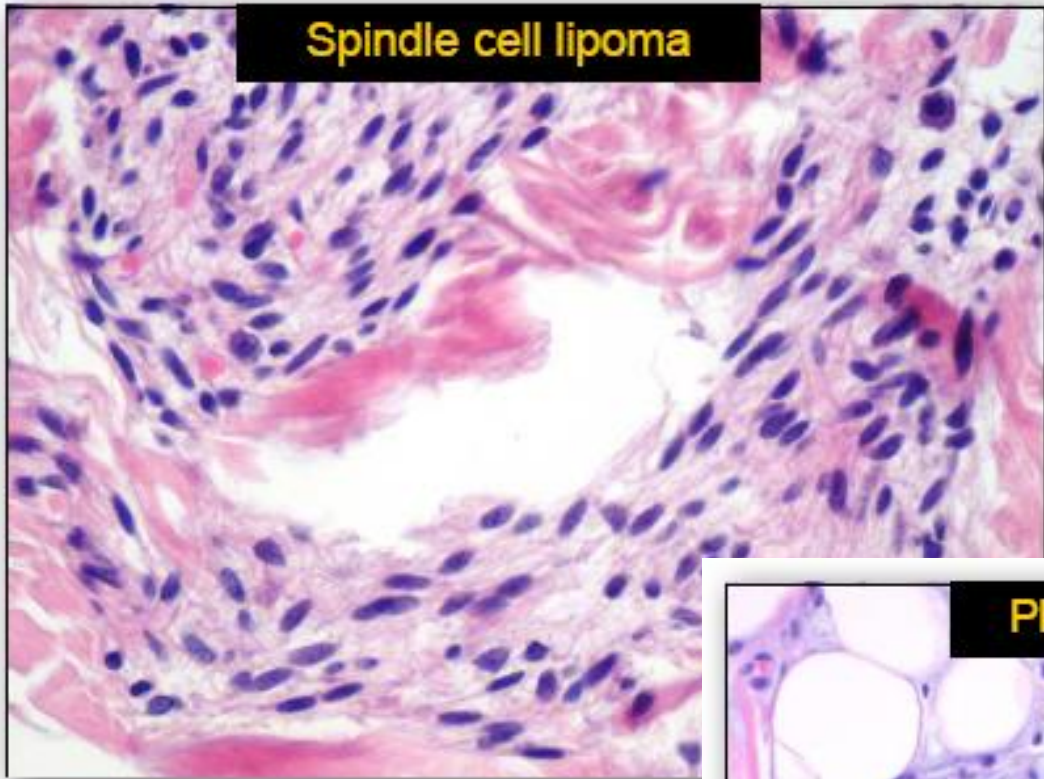
A case of 'fat-free' pleomorphic lipoma occurring in the upper back and axilla simultaneously

Liang Wang^{1,2}, Yang Liu^{1,2}, Di Zhang^{1,2}, Yong Zhang^{1,2}, Na Tang^{1,2} and En-Hua Wang^{1,2*}

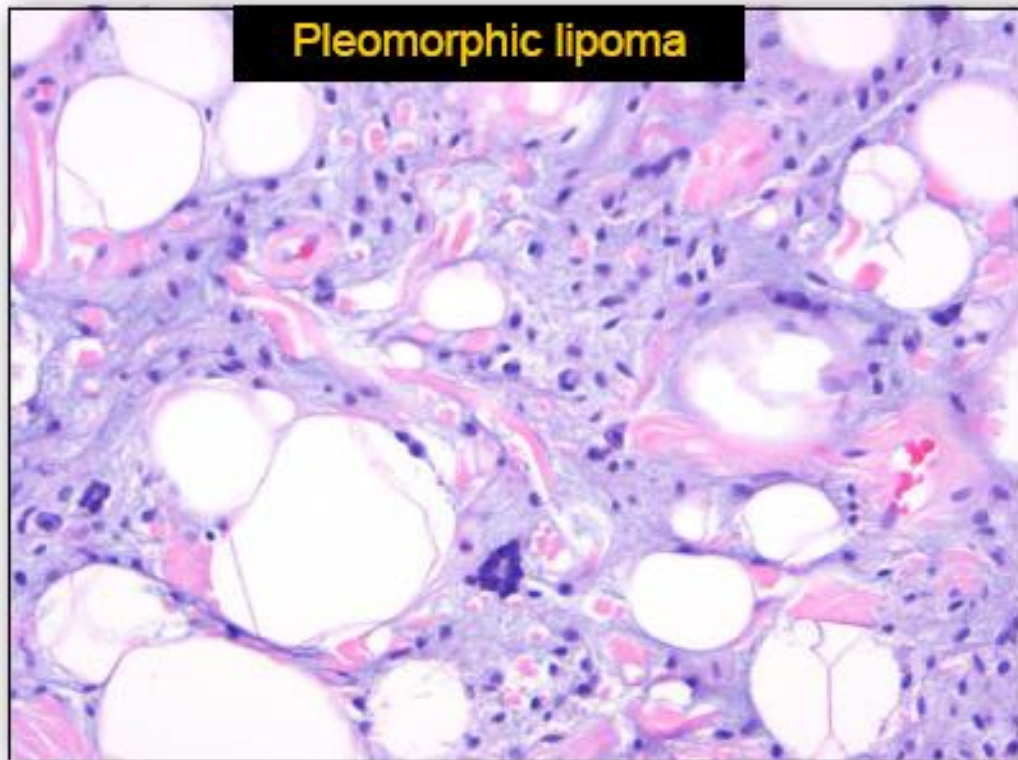
Diagnostically Challenging Spindle Cell Lipomas: A Report of 34 "Low-Fat" and "Fat-Free" Variants

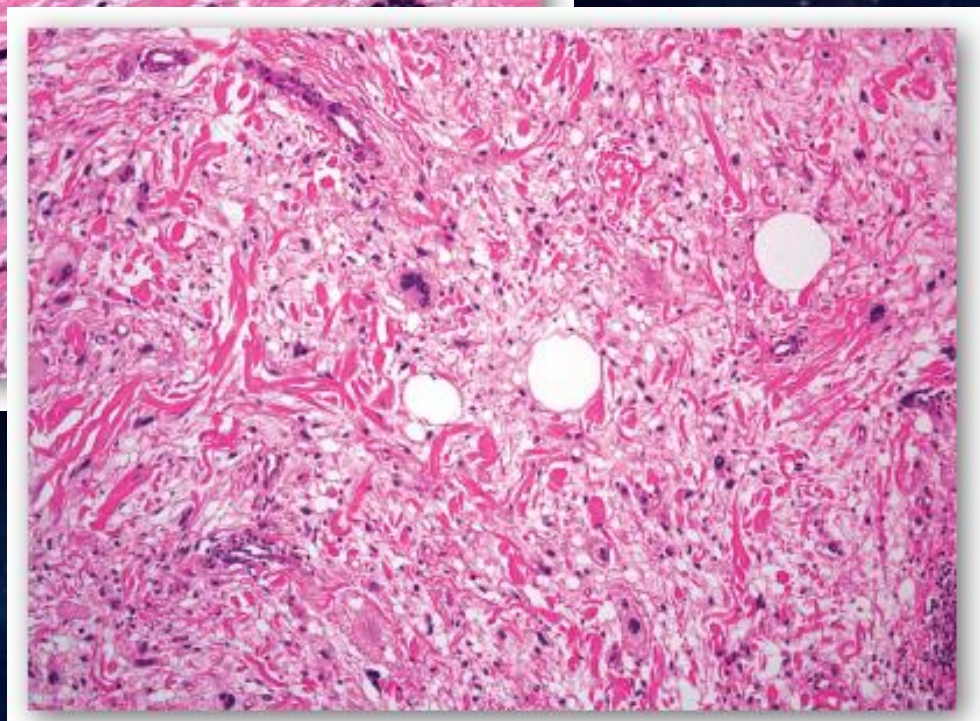
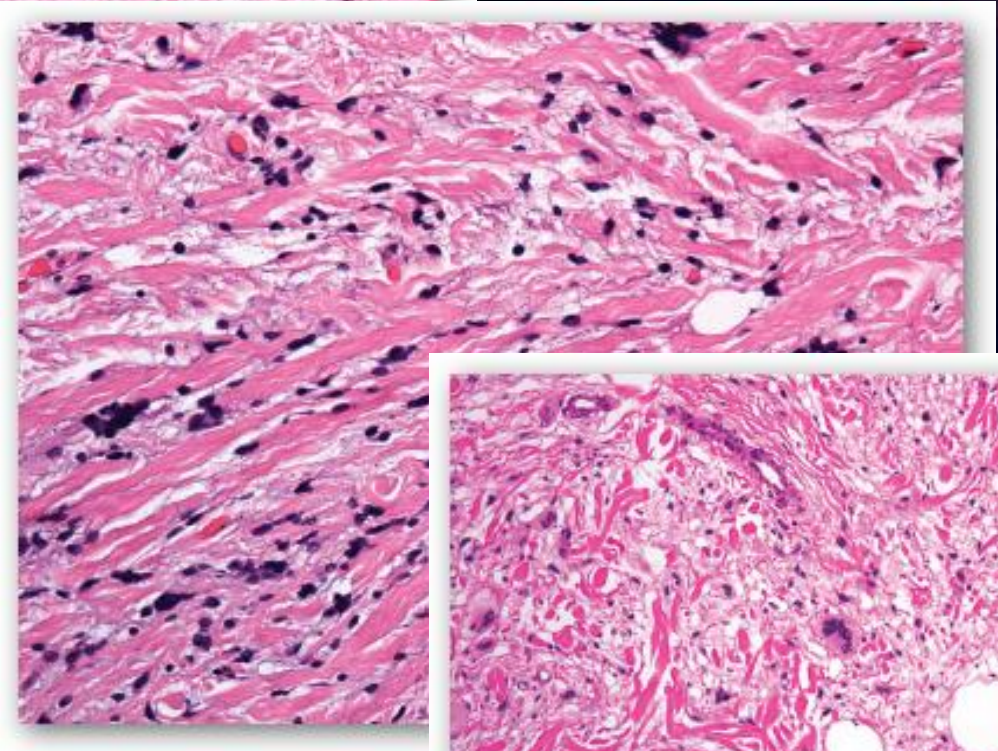
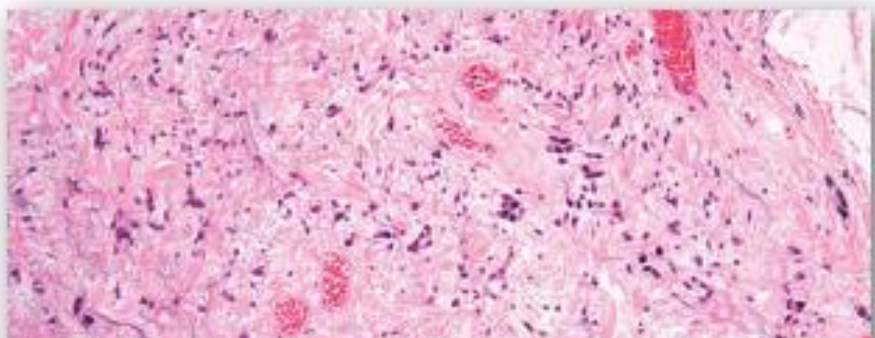
Steven D. Billings, MD and Andrew L. Folpe, MD†*

Spindle cell lipoma



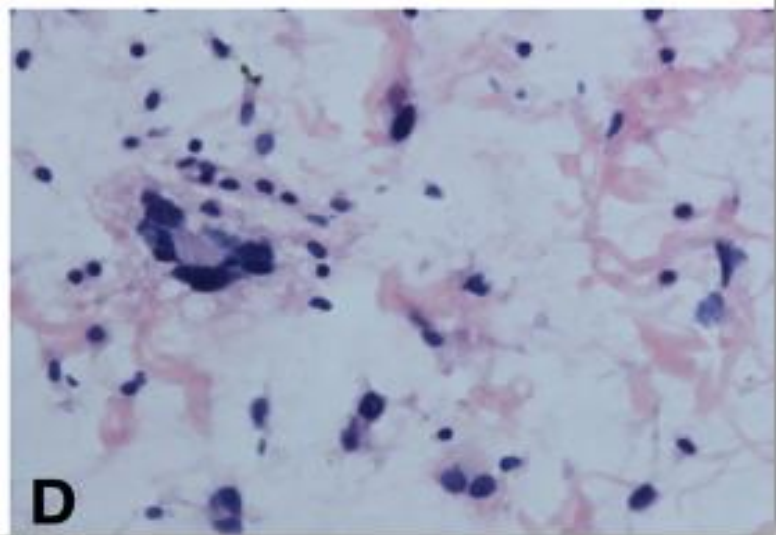
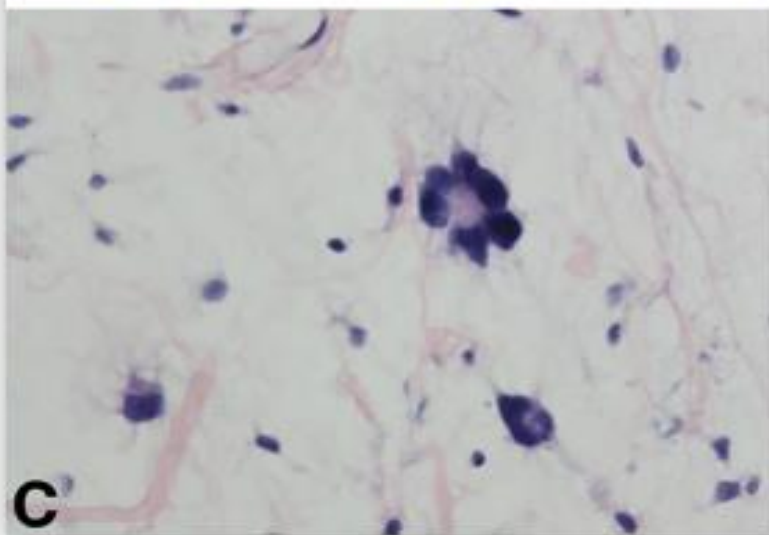
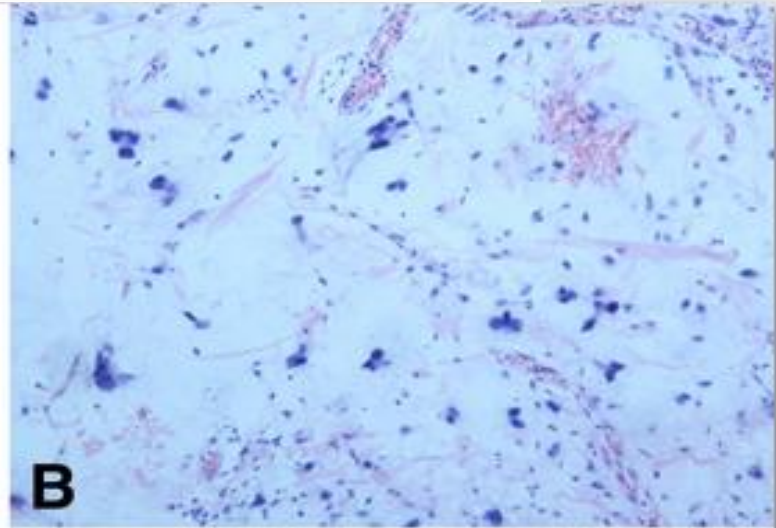
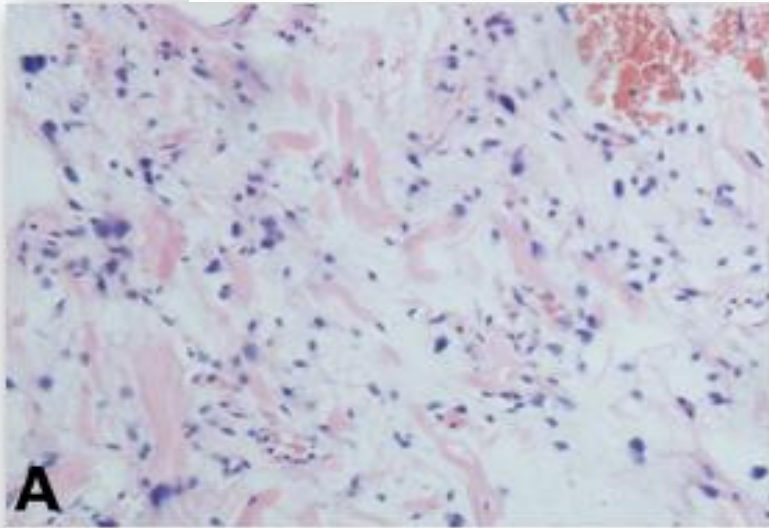
Pleomorphic lipoma





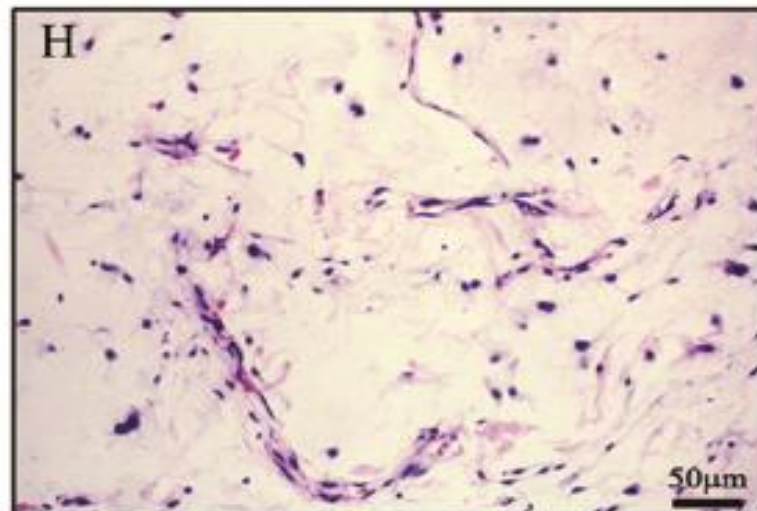
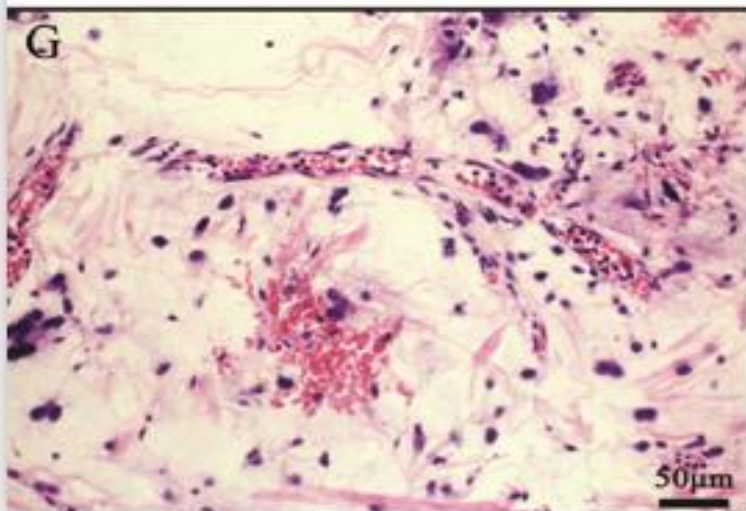
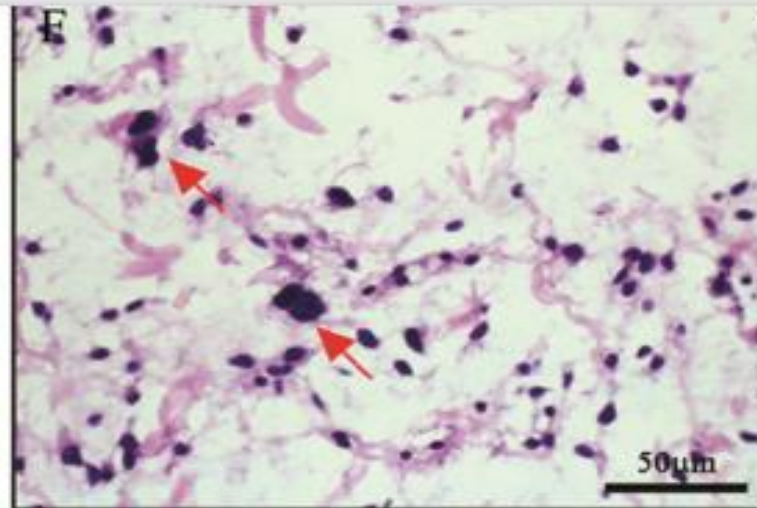
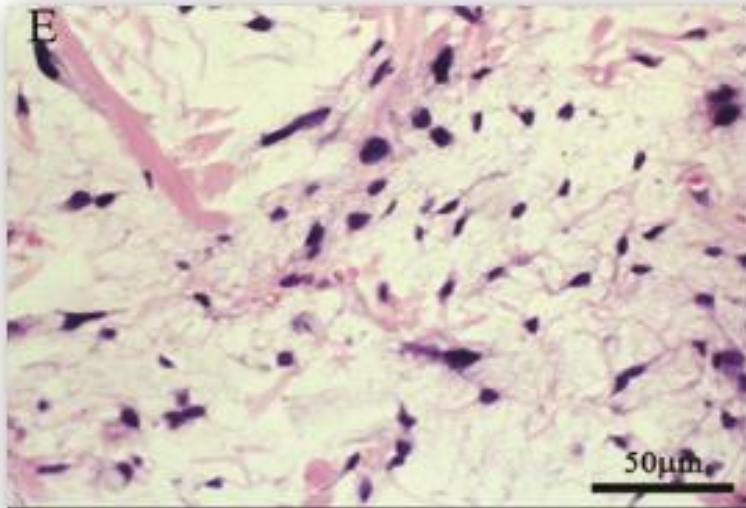
Pleomorphic lipoma lacking mature fat component in extensive myxoid stroma: a great diagnostic challenge

Xu-Yong Lin^{1,2}, Yan Wang^{1,2}, Yang Liu^{1,2}, Ying Sun³, Yuan Miao^{1,2}, Yong Zhang^{1,2}, Juan-Han Yu^{1,2} and En-Hua Wang^{1,2*}



A case of 'fat-free' pleomorphic lipoma occurring in the upper back and axilla simultaneously

Liang Wang^{1,2}, Yang Liu^{1,2}, Di Zhang^{1,2}, Yong Zhang^{1,2}, Na Tang^{1,2} and En-Hua Wang^{1,2*}



Case	Sex	Age (yrs)	Site	Referring Diagnosis
1	M	NA	Posterior auricular	NA
2	M	56	Left scapula	NA
3	M	38	Right shoulder	Myxoid malignant fibrous histiocytoma
4	M	67	Left neck	Giant cell fibroblastoma
5	M	76	Left cheek	NA
6	M	NA	NA	Pleomorphic soft tissue tumor
7	F	48	Nose	Granulomatous rosacea

1	33	M	Scalp	2.4	Benign myxoid tumor
2	78	M	Back	2.5	Myxoid neurofibroma
3	33	F	Foot	1.1	NA
4	48	M	Thigh	4.0	Angiomyxoma
5	70	M	Neck	NA	NA
6	54	M	Neck	2.2	Atypical lipoma
7	50	M	Shoulder	2.0	Spindle cell lipoma vs. low-grade sarcoma
8	51	M	Neck	1.3	Benign myxoid tumor
9	47	F	Neck	1.7	Solitary fibrous tumor
10	58	M	Back	2.0	Spindle cell lipoma

13	74	M	Shoulder	2.8	Benign nerve sheath tumor
14	59	M	Back	2.7	Benign mesenchymal tumor
15	59	M	Neck	2.5	Angiomyxoma
16	76	M	Neck	1.0	Benign nerve sheath tumor

Myxofibrosarcoma vs. angiomyxoma

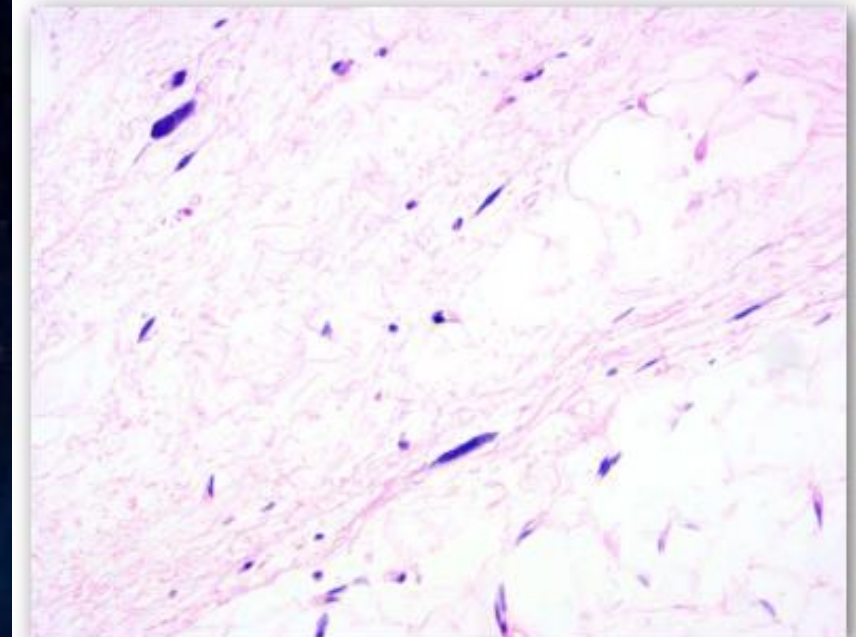
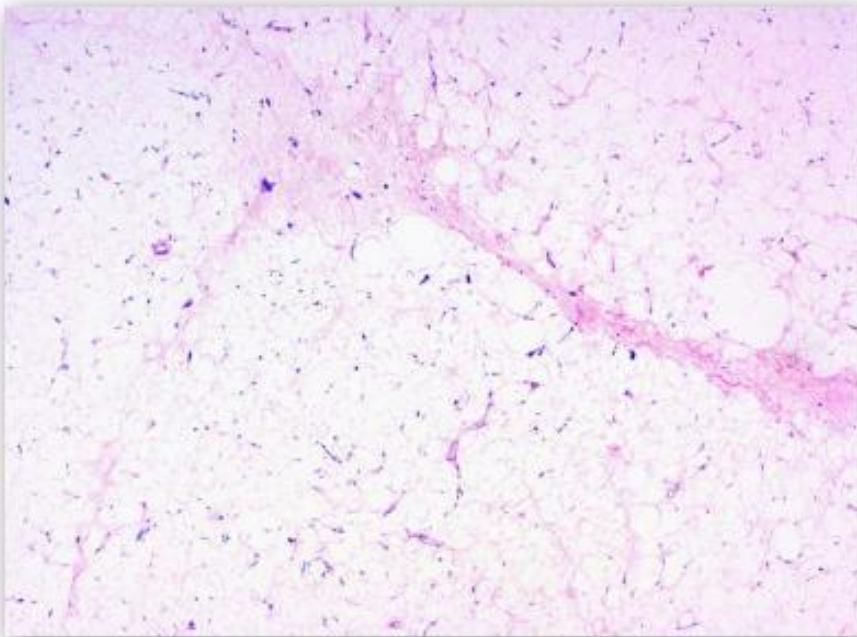
- Low-grade sarcoma
- Low-grade fibromyxoid sarcoma
- Benign mesenchymal tumor
- Spindle cell lipoma vs. solitary fibrous tumor
- Neurofibroma
- Reactive process

DIFERENCIÁLNA DG.

- **ALT/WDLP, MYXOID LIPOSARCOMA**
- **MYXOFIBROSARCOMA**
- **GIANT-CELL FIBROBLASTOMA**
- **GIANT-CELL ANGIOFIBROMA**
- **FAT-FORMING SFT**
- **LGFMS**
- **OTHER BENIGN T.**

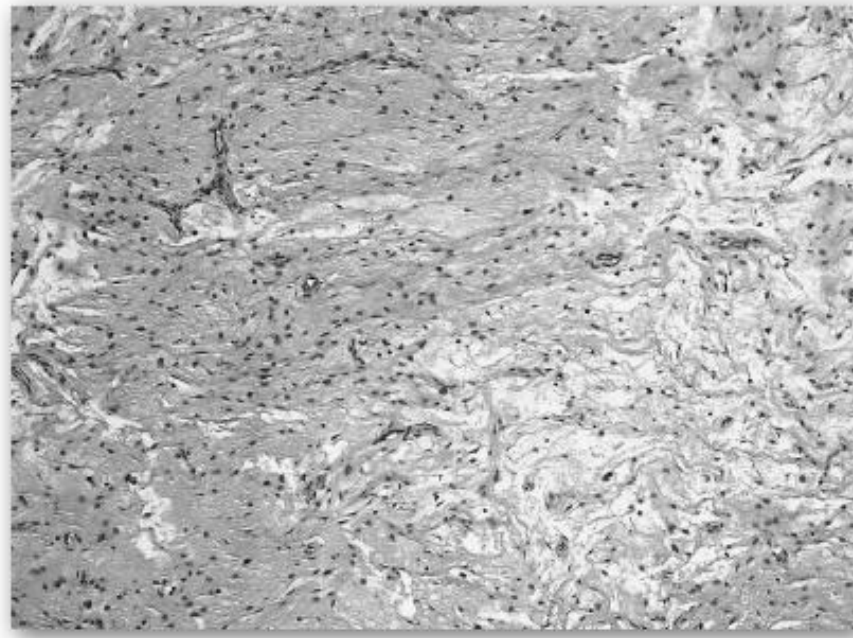
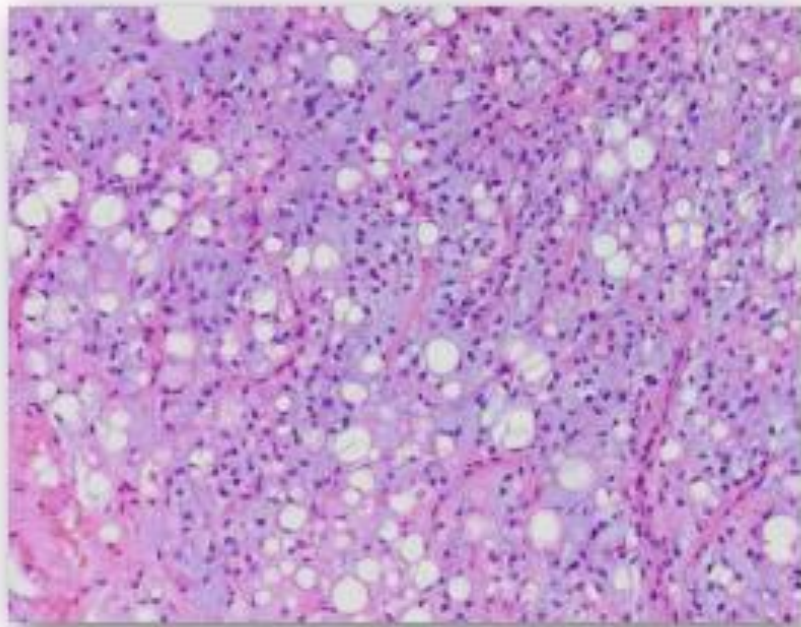
DIFERENCIÁLNA DG.

– ALT/WDLP, MYXOID LIPOSARCOMA



DIFERENCIÁLNA DG.

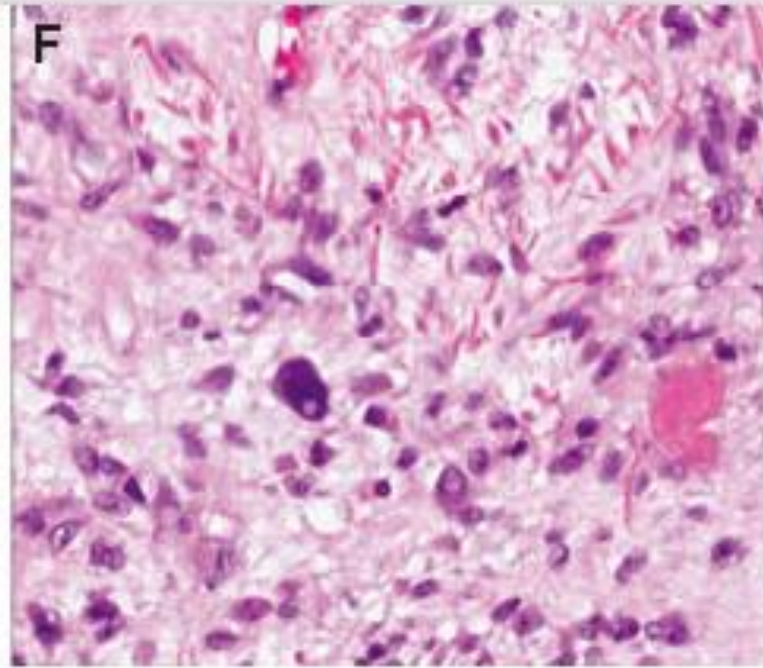
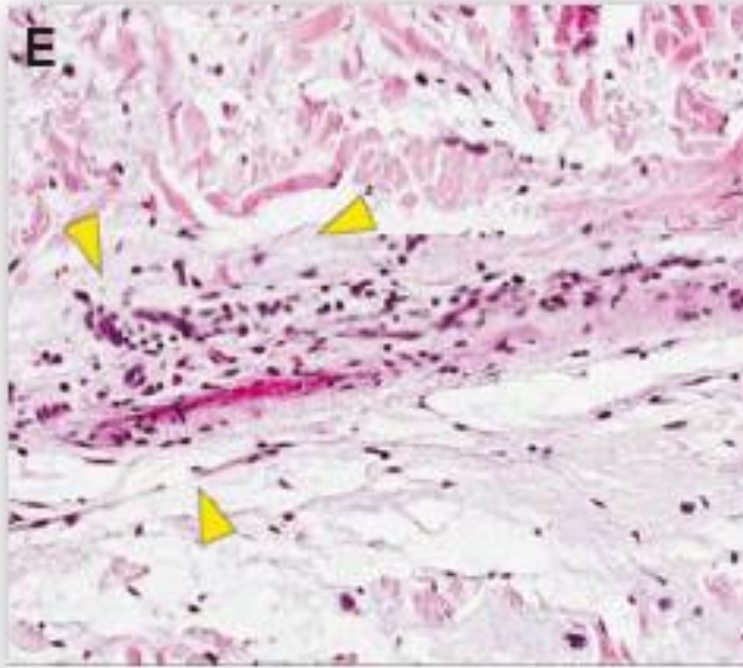
– ALT/WDLP, MYXOID LIPOSARCOMA



DIFERENCIÁLNA DG.

CD34-positive superficial myxofibrosarcoma: a potential diagnostic pitfall[§]

Steven C. Smith^{1,†}, Ann A. Poznanski^{1,†,§}, Douglas R. Fullen^{1,2}, Linglei Ma³, Jonathan B. McHugh¹, David R. Lucas¹ and Rajiv M. Patel^{1,2}



DIFERENCIÁLNA DG.

- **ALT/WDLP, MYXOID LIPOSARCOMA**
- **MYXOFIBROSARCOMA**
- **GIANT-CELL FIBROBLASTOMA**
- **GIANT-CELL ANGIOFIBROMA**
- **FAT-FORMING SFT**
- **LGFMS**
- **OTHER BENIGN T.**



